The Journal of

Laryngology & Otology

FOUNDED IN 1887 BY MORELL MACKENZIE & NORRIS WOLFENDEN

Editors:
John B Booth (1987–1992)
Neil Weir (1993–)
Guy Kenyon (1998–), Co-editor

Assistant Editors: Neil Weir (1989–1992), Patrick Beasley (–1993), Carol Wengraf, Richard Ramsden, Iolo Griffiths (–1993), Peter Rhŷs-Evans (–1996), David Proops (1993–), Valerie Lund (1993–), Henry Grant (1993–1998), Andrew Jones (1994–), Guy Kenyon (1994–1997), Michael Rothera (1995–1999), Martin Bailey (1996–), Liam Flood (1996–), Patrick Bradley (1996–), Nick Jones (1996–), Iain Swan (1997–), John Rubin (1998–)

Assistant Editors USA: Steven Zeitels (1998–), Saumil Merchant (1998–)

Advisers in Pathology: Imrich Friedmann, Brian Manners (1993–1997), Christopher Milroy (1993–), Kenneth McClelland (1993–1994), Lesley Smallman (1993–), Ketan Shah (1999–), Adrian Warfield (1999–)

Adviser in Audiology: Linda Luxon

Advisers in Radiology: Glyn Lloyd, Peter Phelps

Advisers in Statistics: Steven Evans (–1991), Anthony Hughes (1992–1999), Peter Kelly (1992–1999), Gillian Raab (1992), Janine Gray (1997–)

Book Review and Abstracts Editor: John Booth (1993–1994)

Production Editors: Jenny Mugridge (1993), Gillian Goldfarb (1994–), Inga McKenzie (1994–1995), Jennifer Almond (1996–)

Indexer: June Morrison

INDEX

VOLUMES 104–113

Published for the Proprietors JLO (1984) Ltd by
Headley Brothers Ltd
Ashford, Kent TN24 8HH

1999

The Journal of

Laryngology & Otology

FOUNDED IN 1887 BY MORELL MACKENZIE & NORRIS WOLFENDEN

Editors:
John B Booth (1987–1992)
Neil Weir (1993–)
Guy Kenyon (1998–), Co-editor

Assistant Editors: Neil Weir (1989–1992), Patrick Beasley (–1993), Carol Wengraf, Richard Ramsden, Iolo Griffiths (–1993), Peter Rhŷs-Evans (–1996), David Proops (1993–), Valerie Lund (1993–), Henry Grant (1993–1998), Andrew Jones (1994–), Guy Kenyon (1994–1997), Michael Rothera (1995–1999), Martin Bailey (1996–), Liam Flood (1996–), Patrick Bradley (1996–), Nick Jones (1996–), Iain Swan (1997–), John Rubin (1998–)

Assistant Editors USA: Steven Zeitels (1998–), Saumil Merchant (1998–)

Advisers in Pathology: Imrich Friedmann, Brian Manners (1993–1997), Christopher Milroy (1993–), Kenneth McClelland (1993–1994), Lesley Smallman (1993–), Ketan Shah (1999–), Adrian Warfield (1999–)

Adviser in Audiology: Linda Luxon

Advisers in Radiology: Glyn Lloyd, Peter Phelps

Advisers in Statistics: Steven Evans (–1991), Anthony Hughes (1992–1999), Peter Kelly (1992–1999), Gillian Raab (1992), Janine Gray (1997–)

Book Review and Abstracts Editor: John Booth (1993–1994)

Production Editors: Jenny Mugridge (1993), Gillian Goldfarb (1994–), Inga McKenzie (1994–1995), Jennifer Almond (1996–)

Indexer: June Morrison

INDEX

VOLUMES 104–113

Published for the Proprietors JLO (1984) Ltd by
Headley Brothers Ltd
Ashford, Kent TN24 8HH

1999

AUTHORS INDEX

Vol. 104 1990	Vol. 105 1991	Vol. 106 1992	Vol. 107 1993	Vol. 108 1994
Vol. 109 1995	Vol. 110 1996	Vol. 111 1997	Vol. 112 1998	Vol. 113 1999

Aanesen JP *see* Haye R *et al.*
Aasen S *see* Boysen M *et al.*
Abadir WF, Nakhla V, Chong P, Removal of superglue from the external ear using acetone: case report and literature review. *Clin. Rec.* **109**: 1219
Abbondanzo SL *see* Aguilera NSI *et al.*
Abboud B, Tabchy B, Jambart S, Abou Hamad W, Farah P, Benign disease of the thyroid gland and vocal fold paralysis. *Clin. Rec.* **113**: 473
Abd-Al-Hady MR, Shehata O, Saleh A, Sallam FS, Audiology findings following head trauma. *Orig. Art.* **104**: 927
Abdel-Aziz MF, Gad El Hak NA, Carding PN, Thyroplasty for functional rehabilitation of the incompetent larynx. *Orig. Art.* **112**: 1172
Abdel-Fatah H *see* Elwany and Abdel-Fatah
Abdel-Moneim MH *see* Elwany and Abdel-Moneim
Abdelnour A *see* Atiyeh BS *et al.*
Abdul-Baqi KJ, Chloral hydrate and middle ear pressure. *Orig. Art.* **105**: 421
Abdullah JM *see* Sharma HS *et al.*
Abdullah V, Pringle MB, Shah NS, Use of the trimmed Shah permavent tube in the management of glue ear. *Orig. Art.* **108**: 303
Abdullah V, Williamson P, Gallimore A, Shah NS, Middle ear lipoma. *Clin. Rec.* **107**: 1151
Abdullah V, *see also* McFerran DJ *et al.*; Morgan DW *et al.*
Abdulwahab AA *see* Saleh EM *et al.*
Abele R *see* Quinodoz D *et al.*
Abhyankar US *see* Bhargava KB *et al.*
Abiko Y *see* Ikeda M *et al.*
Abou El-Hamd KA, Nasolabial cyst: a report of eight cases and a review of the literature. *Clin. Rec.* **113**: 747
Abou Hamad W *see* Abboud B *et al.*
Abou-Elhmd KA, Hawthorne MR, Flood LM, Cochlear implantation in a case of Wegener's granulomatosis. *Clin. Rec.* **110**: 958
Abou-Seif SG, Baky FA, El-Ebrashy F, Gaafar HA, Scleroma of the upper respiratory passages: a CT study. *Orig. Art.* **105**: 198
Abraham EK *see* Cherian T *et al.*
Abramovich S *see* Balraj A *et al.*; Jayaraj SM *et al.*; Patel SK *et al.*; Thomas DM *et al.*; Vijaya-Sekaran S *et al.*
Abrol R *see* Gupta AK *et al.*
Abu Chra KA *see* Al Muhana A *et al.*
Abu Nasser I *see* Gordts F *et al.*
Abu Shara KA, Al-Muhana AA, Al-Shennawy M, Hamartomatous tonsillar polyp. *Path. Focus* **105**: 1089
Abu Shara KA, Ghareeb MA, Zaher S, Mobacher A, Khalifa MCh, Saleh SZ, Radiotherapeutic effect on oropharyngeal flora in patients with head and neck cancer. *Orig. Art.* **107**: 222
Abuzeid M, Gangopadhyay K, Rayappa CS, Antonios JI, Intraoral sebaceous carcinoma. *Path. Focus* **110**: 500
Abuzeid MO *see* Gangopadhyay K *et al.*
Acar A, Dursun G, Aydin Ö, Akbas Y, J incision in neck dissections. *Orig. Art.* **112**: 55
Acharya M *see* Udwadia RA *et al.*
Achiron R *see* Golan-Porat N *et al.*
Actis R *see* Rossi G *et al.*
Adali MK *see* Uzun C *et al.*
Adam EC, Schumacher DU, Schumacher U, Cilia from a cystic fibrosis patient react to the ciliotoxic *Pseudomonas aeruginosa* II lectin in a similar manner to normal control cilia - a case report. *Clin. Rec.* **111**: 760
Adam EJ *see* Rowe-Jones JM *et al.*
Adamopoulos G, Yotakis I, Apostolopoulos K, Manolopoulos L, Kandiloros D, Ferekidis E, Supraglottic laryngectomy: series report and analysis of results. *Orig. Art.* **111**: 730
Adamopoulos G, *see also* Ferekidis E *et al.*; Manolis E *et al.*; Manolopoulos L *et al.*; Vlahos L *et al.*
Adamopoulos GK *see* Kandiloros DC *et al.*; Yiotakis J *et al.*
Adams DA, Gormley PK, Kerr AG, Smyth GDL, Osterberg P, Sloan J, Otological manifestations of a new familial polyostotic bone disorder. *Orig. Art.* **105**: 80
Adams DA, *see also* Chan YM *et al.*
Adams G *see* Lund VJ *et al.*
Adams WM, Jones RL, Chavda SV, Pahor AL, CT assessment of jugular foramen dominance and its association with hand preference. *Rad. Focus* **111**: 290
Adcock S *see* Dawes PJD *et al.*
Adeley J *see* Drysdale AJ *et al.*
Adiego MI, Millán J, Royo J, Domínguez L, Castellote MA, Alfonso JI, Vallés H, Unusual association of secondary tonsillar and cerebral tuberculosis. *Clin. Rec.* **108**: 348
Adlam DM *see* von Blumenthal H *et al.*
Adler D *see* Siodlak MA *et al.*
Adlington P, Anscombe AJ, Phillips JJ, Influence of the mode of preparation on the long-term efficacy of homologous costal cartilage implants. *Orig. Art.* **106**: 511
Adour KK *see* Wayman DM *et al.*
Adunski A *see* Talmi YP *et al.*
Agarwal P, Bais, AS, A clinical and videostroboscopic evaluation of laryngeal tuberculosis. *Orig. Art.* **112**: 45
Aggerholm K, Illum P, Surgical treatment of Zenker's diverticulum. *Orig. Art.* **104**: 312
Agius AM, Wake M, Pahor AL, Smallman LA, Surface morphology of middle ear epithelium in chronic ear disease. *Orig. Art.* **108**: 1024
Agrawal R, Flood LM, Bradey N, Iatrogenic pulsatile tinnitus. *Clin. Rec.* **107**: 445
Agrawal R, Hampal S, Flood LM, The open access ENT casualty service. *Orig. Art.* **106**: 719
Aguilera NSI, Wenig BM, Abbondanzo SL, The blastic variant of mantle cell lymphoma arising in Waldeyer's tonsillar ring. *Path. Focus* **112**: 991
Ah-See K *see* Molony NC *et al.*
Ah-See KW, Kelly G, Todd JG, MacKenzie K, A prospective evaluation of the feasibility of day-case microlaryngeal surgery. *Orig. Art.* **112**: 351
Ah-See KW, Kerr J, Sim DW, Prophylaxis for venous thromboembolism in head and neck surgery: the practice of otolaryngologists. *Orig. Art.* **111**: 845
Ah-See KW, McLaren K, Maran AGD, Wegener's granulomatosis presenting as major salivary gland enlargement. *Clin. Rec.* **110**: 691
Ah-See KW, Molony NC, A qualitative assessment of randomized controlled trials in otolaryngology. *Orig. Art.* **112**: 460
Ah-See KW, Molony NC, Maran AGD, Trends in randomized controlled trials in ENT: a 30 year review. *Rev. Art.* **111**: 611
Ahluwalia H, Gupta SC, Gupta SC, Spindle cell carcinoma of the nasal septum. *Path. Focus* **110**: 284
Ahluwalia H, *see also* Gupta and Ahluwalia; Singh and Ahluwalia
Ahluwalia KB, Bahadur S, Rhinosporidiosis associated with squamous cell carcinoma in the tongue. *Clin. Rec.* **104**: 648
Ahluwalia KB, Culture of the organism that causes rhinosporidiosis. *Orig. Art.* **113**: 523
Ahmad BM *see* Nwaorgu OGB *et al.*
Ahmad H *see* Atiyeh BS *et al.*
Ahmad I, Ray J, Cullen RJ, Shortridge RTJ, Bilateral and multicystic major salivary gland disease: a rare presentation of primary Sjögren's syndrome. *Clin. Rec.* **112**: 1196
Ahmed A *see* Prichard AJN *et al.*
Ahmed IM *see* Cherian T *et al.*
Ahmed K, Jones AS, Shah K, Smethurst A, The role of ultrasound in the management of peritonsillar abscess. *Rad. Focus* **108**: 610
Ahmed K, McCormick MS, Bay leaf: an unusual oesophageal foreign body. *Clin. Rec.* **107**: 153
Ahmed M *see* Taibah K *et al.*
Ahmed N *see* Pamaraju N *et al.*; Sharma RK *et al.*
Ahmed S *see* Thomas R *et al.*

Ahmed SK, Lee WC, Irving RM, Walsh AR, Is Ollier's disease an understaging of Maffucci's syndrome? *Rad. Focus* **113**: 861
Ahmed YS, Hanson DR, Halaka AN, Hoarseness as the sole presenting symptom of foramen magnum meningioma. *Clin. Rec.* **104**: 715
Ahmmed AU, Camilleri AE, Small M, Cavernous sinus thrombosis following manipulation of fractured nasal bones. *Clin. Rec.* **110**: 69
Ahmmed AU, Mackenzie I, Das VK, Chatterjee S, Lye RH, Audio-vestibular manifestations of Chiari malformation and outcome of surgical decompression: a case report. *Clin. Rec.* **110**: 1060
Ahuja A, Leung SF, Ying M, Metreweli C, Echography of metastatic nodes treated by radiotherapy. *Orig. Art.* **113**: 993
Ahuja A, Ying M, King W, Metreweli C, A practical approach to ultrasound of cervical lymph nodes. *Orig. Art.* **111**: 245
Ahuja A, *see also* John DG *et al.*; Scott PMJ *et al.*
Aidonis A *see* Nikolaou A *et al.*
Aijaz F, Salam AU, Muzaffar S, Akbani Y, Hasan SH, Inflammatory pseudotumour of trachea — report of a case in an eight-year-old child. *Path. Focus* **108**: 613
Aijaz F, *see also* Iqbal K *et al.*
Aikawa T *see* Murakami M *et al.*
Aitasalo K *see* Joensuu H *et al.*
Ajal M, Roche J, Turner J, Fagan P, Unusual lesions of the internal auditory canal. *Clin. Rec.* **112**: 650
Ajal M, Turner J, Fagan P, Walker P, Actinomycosis otomastoiditis. *Clin. Rec.* **111**: 1069
Ajulo SO, 'Priapism'of the turbinates: a cause of nasal obstruction in sickle cell anaemia. *Clin. Rec.* **105**: 851
Ajulo SO, Harun S, Montgomery P, An unusual oronasal foreign body. *Clin. Rec.* **105**: 1118
Ajulo SO, Khambata AS, Pushpala SM, Unusual presentation of squamous cell carcinoma of the middle ear and mastoid. *Clin. Rec.* **105**: 38
Ajulo SO, Osiname AI, Myatt HM, Sensorineural hearing loss in sickle cell anaemia — a United Kingdom study. *Orig. Art.* **107**: 790
Ajulo SO, *see also* Owa AO *et al.*
Akagi H *see* Kariya S *et al.*
Akang EEU *see* Nwaorgu OGB *et al.*
Akbani Y *see* Aijaz F *et al.*
Akbas Y *see* Acar A *et al.*
Akbulut N *see* Osma Ü *et al.*
Akbulut S *see* Özyar E *et al.*
Akhtar MJ, Shinefield HR, *Staphylococcus aureus* peritonsillar abscess in an 11-week-old infant. *Clin. Rec.* **110**: 78
Akhtar S, Wood G, Rubin JS, O'Flynn PE, Ratcliffe P, Effect of caffeine on the vocal folds: a pilot study. *Orig. Art.* **113**: 341
Akhtar S *see also* Salib RJ *et al.*
Akin I, Torkut A, Ustünosoy E, Taskoparan G, Gúrzumar A, Results of reconstruction with free forearm flap following laryngopharyngo-oesophageal resection. *Orig. Art.* **111**: 48
Akiner MN, Saatci MR, Yilmaz O, Erekul S, Intraglandular toxoplasmosis lymphadenitis of the parotid gland. *Clin. Rec.* **105**: 860
Akkielah A, Kalan A, Kenyon GS, Diathermy tonsillectomy comparisons of morbidity following bipolar and monopolar microdissection needle excision. *Orig. Art.* **111**: 735
Akmal SN *see* Rajab E *et al.*
Akosa AB *see* Tay HL *et al.*
Aksoy Y *see* Sutay S *et al.*
Aktan B *see* Altas E *et al.*
Aktaş D *see* Dündar A *et al.*
Akyol Ö *see* Canbolat O *et al.*
Al Anazy F *see* Asiri S *et al.*
Al Anazy FH *see* Zakzouk SM *et al.*
Al Ghamdi S *see* Thomas R *et al.*
Al Muhaimeid H *see* Ali Bafaqeeh S *et al.*
Al Muhana A, Abu Chra KA, Dashti H, Behbehani A, Al-Naqueeb N, Thyroid lobectomy for removal of fish bone. *Clin. Rec.* **104**: 511
Al Saigh A-A *see* Sheikha A *et al.*
Al-Anazy FH, Zakzouk SM, Otolaryngological manifestation of Gorlin Goltz's syndrome. *Clin. Rec.* **111**: 286
Al-Arfaj AL *see* Dawlatly EE *et al.*
Al-Arifi A *see* Taibah K *et al.*
Al-Ayoubi A, Burns BV, Ray J, Shotton JC, Schofield JB, Actinomycosis of the posterior triangle: a case report and review of the literature. *Clin. Rec.* **111**: 1082
Al-Ayoubi A, Ray J, An unusual foreign body in the post-nasal space: a case report. *Rad. Focus* **111**: 775
Al-Ayoubi A, *see also* Ray J *et al.*
Al-Azizi MA *see* Dawlatly EE *et al.*
Al-Fallouji HK, Snow DG, Kuo MJ, Johnson PJE, Spontaneous retropharyngeal haematoma: two cases and a review of the literature. *Clin. Rec.* **107**: 649
Al-Habib HM *see* Yehia MM *et al.*
Al-Hady MR, Ghanaam B, Al-Hady MZ, Aneurysmal bone cyst of the maxillary sinus. *Clin. Rec.* **104**: 501
Al-Hady MZ *see* Al-Hady MR *et al.*
Al-Hilou R, Inhalation of foreign bodies in children. *Orig. Art.* **105**: 466
Al-Jassim AH, Swift AD, Persistent nasal crusting due to hypohidrotic ectodermal dysplasia. *Clin. Rec.* **110**: 379
Al-Jassim AHH *see* Lesser and Al-Jassim
Al-Khaboori MJJ *see* Nehru VI *et al.*
Al-Khabori M *see* Thomas MR *et al.*
Al-Khabori MJJ, Simple method of insertion of Xomed one piece septal button. *Short Comm.* **106**: 358
Al-Khabori MJJ, Natarajan B, Thomas M, Irvine B, Naso-labial flap in the reconstruction of the floor of the mouth defects. *Orig. Art.* **107**: 320
Al-Khalifa A *see* Sharma RK *et al.*
Al-Khalifa S *see* Janahi WM *et al.*; Sharma RK *et al.*
Al-Khayat M, Kenyon GS, Midline sublingual dermoid cyst. *Clin. Rec.* **104**: 578
Al-Khayat M, Kenyon GS, Fawcett HV, Powell-Tuck J: Nutritional support in patients with low volume chylous fistula following radical neck dissection. *Orig. Art.* **105**: 1052
Al-Muhaimeid H *see* El-Sayed and Al-Muhaimeid
Al-Muhana AA *see* Abu Shara KA *et al.*
Al-Naggar AK *see* Carrillo R *et al.*
Al-Naqueeb N *see* Al Muhanna A *et al.*
Al-Saati A, Mitchell DB, Toynton S, Fitzgerald O'Connor AF, Post laryngectomy diverticulum — a case report. *Clin. Rec.* **107**: 46
Al-Saati A, Morrison GAJ, Clary RA, Bailey CM, Surgical decannulation of children with tracheostomy. *Orig. Art.* **107**: 217
Al-Sader MH, Tait R, Leader M, Chondroblastoma — an unusual site in a young patient. *Path. Focus* **110**: 696
Al-Sader MH, *see also* Donnelly MJ *et al.*
Al-Samarrae SM, Treatment of 'vasomotor rhinitis' by the local application of silver nitrate. *Orig. Art.* **105**: 285
Al-Serhani A *see* El-Sayed and Al-Serhani
Al-Shahi R, O'Connell M, Huchzermeyer P, Moore-Gillon V, Combined forceps and catheter extraction of an oesophageal foreign body. *Clin. Rec.* **111**: 583
Al-Shennawy M *see* Abu Shara KA *et al.*
Al-Shihabi BM, Carcinoma of temporal bone presenting as malignant otitis externa. *Clin. Rec.* **106**: 908
Al-Sinawi A, Johns AN, Parapharyngeal solitary fibrous tumour: an incidental finding at ENT examination. *Clin. Rec.* **108**: 344
Al-Wadei A *see* Kameswaran M *et al.*
Alapatt JJ *see* Nayar RC *et al.*
Albarino AR *see* Colmenero C *et al.*
Albers FWJ, Ingels KJAO, Otoneurological manifestations in Chiari-I malformation. *Clin. Rec.* **107**: 441
Albert DM *see* Fisher EW *et al.*; Hollis LJ *et al.*; Irving RM *et al.*; Laing MR *et al.*; Papsin BC *et al.*; Worley GA *et al.*
Albery EH *see* Robson AK *et al.*
Alcantud V *see* Dueñas L *et al.*
Alcock GJ, Fowler JF, Haybittle JL, Hopewell JW, Rezvani M, Wiernik G, Salvage surgery following irradiation with different fractionation regimes in the treatment of carcinoma of the laryngopharynx: experience gained from a British Institute of Radiology study. *Orig. Art.* **106**: 147
Alderson D *see* Pothula and Alderson
Alderson DJ, Lannigan FJ, Lingual thyroid presenting after previous thyroglossal cyst excision. *Clin. Rec.* **108**: 341
Alderson DJ, O'Sullivan DG, Oro-nasal transfer of nasogastric tube following endoscopic placement. *Short Comm.* **112**: 644
Alderson DJ, *see also* Jepson RH *et al.*; Lacy PD *et al.*; Lancaster JL *et al.*

Aldren C *see* El Naggar M *et al.*; Morgan DW *et al.*; Watson MG *et al.*
Aldren CJ *see* Hoare TJ *et al.*
Aldren CP, Soames JV, Birchal JP, Bony remodelling in an osteoma of the paranasal sinuses. *Clin. Rec.* **107**: 633
Aldren CP, *see also* Morgan and Aldren
Alexis R *see* Singh B *et al.*
Alfaro-Monge JM, Fernandez-Espinosa J, Soda-Merhy A, Scleroma of the lower respiratory tract: case report and review of literature. *Clin. Rec.* **108**: 161
Alfonso JI *see* Adiego MI *et al.*
Alguacil-Garcia A *see* Safneck JR *et al.*
Alho O-P, Kristo A, Luotonen J, Autio-Harmainen H, Intraductal papilloma as a cause of a parotid duct cyst: a case report. *Clin. Rec.* **110**: 277
Ali Bafaqeeh S, Zakzouk SM, Al Muhaimeid H, Essa A, Relevant demographic factors and hearing impairment in Saudi children: epidemiological study. *Orig. Art.* **108**: 294
Ali MH *see* Reddy KTV *et al.*
Ali O, Snow DG, Severe congenital laryngeal hypoplasia in a 45-year-old man. *Clin. Rec.* **113**: 1026
Ali Raza S, Denholm SW, Wong JCH, An audit of the management of acute otitis externa in an ENT casualty clinic. *Aud. Art.* **109**: 130
Ali Raza S, *see also* Farrugia EJ *et al.*
Ali Tekalan Ş *see* Ünlü Y *et al.*
Alkan M *see* Leibermann A *et al.*
Allal AS *see* Quinodoz D *et al.*
Allam H *see* Shabana YK *et al.*
Allan W *see* Hill J *et al.*
Allen JP *see* Shotton JC *et al.*
Allias-Montmayeur F, Durroux R, Dodart L, Combelles R, Tumours and pseudotumorous lesions of the temporomandibular joint: a diagnostic challenge. *Path. Focus* **111**: 776
Allison RS *see* Siodlak MA *et al.*
Allphin AL *see* Strauss M *et al.*
Allsager CM, Banerjee AR, Bolia A, Moir A, Oesophageal strictures in children: balloon or bougie dilatation? *Clin. Rec.* **110**: 683
Almaç A, Ündar L, Göze F, Small lymphocytic lymphoma presenting with simultaneous involvement of parotid and submandibular glands bilaterally, maxillary sinus, hard palate and optic nerve. *Clin. Rec.* **105**: 584
Almadori G, Paludetti G, Cerullo M, Ottaviani F, D'Alatri L, Marijuana smoking as a possible cause of tongue carcinoma in young patients. *Clin. Rec.* **104**: 896
Almadori G, Trivelli M, Scarano E, Cadoni G, Misleading clinical features in Wegener's granulomatosis. A case report. *Clin. Rec.* **111**: 746
Almadori G, *see also* Galli J *et al.*
Almeyda J *see* Hern JD *et al.*
Almeyda JS *see* Ghufoor K *et al.*; Hollis LJ *et al.*; Jayaraj SM *et al.*
Alsanjari N *see* **Andaz C** *et al.*
Alsanjari NA *see* Harmse JL *et al.*
Alshaikhly A, Hamid AM, Azadeh B, Glomus tympanicum chemodectoma — unusual radiological findings. *Rad. Focus* **108**: 607
Alshaikhly A, *see also* Hamid and Alshaikhly
Altas E, Karaşen RM, Yilmaz AB, Aktan B, Kocer I, Erman Z, A case of large dentigerous cyst containing a canine tooth in the maxillary antrum leading to epiphora. *Clin. Rec.* **111**: 641
Altas K *see* Tuzuner N *et al.*
Altavilla E *see* Gulisano M *et al.*
Altés J *see* Cánovas DL *et al.*
Altman KW, Mirza N, Philippe L, Metastatic follicular thyroid carcinoma to the paranasal sinuses: a case report and review. *Clin. Rec.* **111**: 647
Alum K *see* Matin MA *et al.*
Alun-Jones T *see* Leighton SEJ *et al.*; Russell JD *et al.*; Wormald and Alun-Jones
Alusi GH, Grant WE, Lee CA, Pasi KJ, Stearns MP, Bleeding after tonsillectomy in severe von Willebrand's disease. *Clin. Rec.* **109**: 437
Alusi GH, Grant WE, Quiney RE, Oculopharyngeal myopathy with sensorineural hearing loss. *Clin. Rec.* **110**: 567
Alvarado CS *see* Wendall Todd N *et al.*
Alvarez F *see* Dueñas L *et al.*
Alvarez J *see* Bernáldez R *et al.*
Alvarez JC *see* Rodrigo JP *et al.*
Alvarez-Gago T *see* Benito I *et al.*
Alvi A, Stegnjajic A, Electrodissection tracheotomy. *Short Comm.* **110**: 765
Alvi A, Theodoropoulos PA, Self-inflicted traumatic macroglossia. *Clin. Rec.* **111**: 75
Amadasun JEO, Bacteriology of inadequately treated active chronic otitis media in the paediatric age group. *Orig. Art.* **105**: 341
Amar MS, Wishahi HF, Zakhary MM, Clinical and biochemical studies of bone destruction in cholesteatoma. *Orig. Art.* **110**: 534
Ambrose R *see* Porter MJ *et al.*
Amerasinghe C *see* Mears and Amerasinghe
Ameye F, Mattelin W, Ingels K, Bradwell R, Bilateral pneumothorax after emergency tracheotomy: two case reports and a review of the literature. *Clin. Rec.* **108**: 69
Anandi V *see* Kurien M *et al.*
Anantha N *see* Shenoy AM *et al.*
Andaz C, Alsanjari N, Garth RJN, Dearnaley DP, Metastatic seminoma of the sphenoid sinus. *Clin. Rec.* **105**: 1075
Andaz C, Whittet HB, Ludman H, An unusual cause of benign paroxysmal positional vertigo. *Clin. Rec.* **107**: 1153
Anderhuber W *see* Habermann W *et al.*; Walch C *et al.*
Andersen NH *see* Sørensen JA *et al.*
Anderson G *see* Fisher EW *et al.*
Anderson SD *see* Halford and Anderson
Andre P *see* Moulin G *et al.*
Andreassen UK, Baer S, Nielsen TG, Dahm SL, Arndal H, Acute epiglottis — 25 years experience with nasotracheal intubation, current management policy and future trends. *Orig. Art.* **106**: 1072
Andreassen UK, *see also* Nielsen TR *et al.*
Andretta M *see* Ferlito A *et al.*
Andrew AC *see* Dekker and Andrew
Angel DG *see* O'Connor Reina C *et al.*
Angeli G *see* Pisani P *et al.*
Angeli SS *see* Athanassopoulou AC *et al.*
Annis JAD *see* Singh V *et al.*
Anscombe AJ *see* Adlington P *et al.*
Ansell J *see* Drysdale AJ *et al.*
Anslow P *see* Whittet HW *et al.*
Anstey ST, Marais J, Wallace W, An unusual case of laryngeal pseudotumour. *Clin. Rec.* **109**: 142
Antinori A *see* Del Forno A *et al.*
Antonelli P *see* Tesei F *et al.*
Antonios DA *see* Harries PG *et al.*
Antonios JI *see* Abuzeid M *et al.*; Rayappa CS *et al.*
Antoun NM *see* Lau DPC *et al.*
Anwar R, Ruddy J, Ghosh S, Lavery KM, Wilson F, Chondrosarcoma of the maxilla. *Clin. Rec.* **106**: 53
Anzai T *see* Murakami M *et al.*
Aoji K *see* Kariya S *et al.*
Apaja-Sarkkinen M *see* Tikkakoski T *et al.*
Aplin DY, Psychological assessment of multi-channel cochlea implant patients. *Orig. Art.* **107**: 298
Aplin DY, *see also* Mawman DJ *et al.*
Apostolopoulos K *see* Adamopoulos G *et al.*
Appleton D *see* Watson MG *et al.*
Appleton RE *see* Hughes AP *et al.*
Aqel NM *see* Dhingra JK *et al.*
Aragon G *see* Regueiro CA *et al.*
Arapantoni-Dadioti P *see* Panayiotides JG *et al.*
Arasaratnam RBS *see* Srinivasan V *et al.*
Archer DJ *see* Hadfield PJ *et al.*; Uttley and Archer
Argov S *see* Kraus M *et al.*
Arias A *see* Campos A *et al.*
Aristegui M *see* Naguib MB *et al.*
Aristimuño D *see* Gòmez Estanocona N *et al.*
Armengot M *see* Basterra J *et al.*; Marco-Algarra J *et al.*
Armour A, Williamson JMS, Ectopic cervical hamartomatous thymoma showing extensive myoid differentiation. *Path. Focus* **107**: 155
Arnal Monreal F *see* López Amado M *et al.*
Arndal H *see* Andreassen UK *et al.*; Tos M *et al.*
Arni T *see* Indudharan R *et al.*
Arrue P *see* Percodani J *et al.*
Arslanoğlu S *see* Öncel S *et al.*

Arteaga J *see* Dueñas L *et al.*
Arthurs GJ *see* Coakley *et al.*
Artzt M *see* Keilmann A *et al.*
Arullendran P, Jani P, Baglin T, Moffat DA, Internal jugular vein thrombosis in association with the factor V Leiden mutation. *Clin. Rec.* **112**: 383
Asahi K *see* Ueda H *et al.*
Asai Y *see* Hoshino T *et al.*
Asakura K *see* Ohguro S *et al.*
Asare-Owusu L, Shotton JC, Schofield JB, Adjuvant radiotherapy for primary mucosal malignant melanoma of the larynx. *Clin. Rec.* **113**: 932
Asawa S *see* Sakaguchi M *et al.*
Ascott F *see* Hartley and Ascott
Asher I *see* Giles and Asher
Ashman RB, Papadimitriou JM Fulurija A, Acute labyrinthitis associated with systemic *Candida albicans* infection in ageing mice. *Orig. Art.* **110**: 13
Ashraf Ali M *see* Gangopadhyay K *et al.*
Ashraf J *see* Iqbal K *et al.*
Ashraful Haq J *see* Indudharan and Ashraful Haq
Ashton-Key M *see* Vinayak BC *et al.*
Asiri S, Hasham A, Al Anazy F, Zakzouk S, Banjar A, Tympanosclerosis: review of the literature and incidence among patients with middle-ear infection. *Orig. Art.* **113**: 1076
Aslan A, Falcioni M, Ruso A, de Donato G, Balyan FR, Taibah A, Sanna M, Anatomical considerations of a high jugular bulb in lateral skull base surgery. *Orig. Art.* **111**: 333
Aslan T *see* Erkan M *et al.*
Astley S *see* Nunez DA *et al.*
Atabey N *see* Güneri EA *et al.*
Atahan IL *see* Özyar E *et al.*
Athanasou NA *see* Commins DJ *et al.*; Koay CB *et al.*
Athanassopoulou AC, Vlahos LL, Gouliamos AD, Kailidou ED, Papailiou JG, Angeli SS, MRI features in a malignant glomus jugulare tumour. *Rad. Focus* **107**: 1067
Athow AC, Kirham N, Malignant parotid salivary gland peripheral nerve sheath tumour in a twelve-year-old girl. *Clin. Rec.* **106**: 748
Atiyeh BS, Abdelnour A, Haddad FF, Ahmad H, Lingual thyroid: tongue-splitting incision for transoral excision. *Orig. Art.* **109**: 520
Atkan B *see* Karasen RM *et al.*
Atlas MD, Coakley D, Diffuse neurofibroma obstructing the external auditory meatus, *Clin. Rec.* **111**: 145
Atlas MD, *see also* Fenton JE *et al.*
Ator GA *see* Edmonds L *et al.*
Atula T, Grénman R, Laippala P, Klemi P-J, Fine-needle aspiration cytology of submandibular gland lesions. *Orig. Art.* **109**: 853
Atula T, Klemi P-J, Donath K, Happonen R-P, Joensuu H, Grenman R, Basal cell adenocarcinoma of the parotid gland: a case report and review of the literature. *Path. Focus* **107**: 862
Auslander L *see* Ostfeld EJ *et al.*
Aust R *see* Nieminen P *et al.*
Autio-Harmainen H *see* Alho O-P *et al.*
Avraham S *see* Berger G *et al.*
Axon PR, Hartley C, Rothera MP, Endoscopic balloon dilatation of subglottic stenosis. *Clin. Rec.* **109**: 876
Axon PR, Mawman DJ, Upile T, Ramsden RT, Cochlear implantation in the presence of chronic suppurative otitis media. *Orig. Art.* **111**: 228
Axon PR, *see also* Hartley and Axon; Temple RH *et al.*; Yates PD *et al.*
Ayache D, Sleiman J, Plouin-Gaudon I, Klap P, Elbaz P, Obliterative otosclerosis. *Orig. Art.* **113**: 512
Aydin Ö, Ustündağ E, İseri M, Özkarakas H, Oğuz AO, Laryngeal amyloidosis with laryngocele. *Clin. Rec.* **113**: 361
Aydin Ö, *see also* Acar A *et al.*
Ayhan A *see* Ünal ÖF *et al.*
Ayshford C *see* Hogg RP *et al.*
Ayshford CA, Walsh RM, Watkinson JC, Dysphagia secondary to invasive candidiasis of a jejunal free flap. *Clin. Rec.* **112**: 1090
Ayshford CA, Walsh RM, Proops DW, Corrosion of a silver Negus tracheostomy tube. *Clin. Rec.* **113**: 68
Ayshford CA, Walsh RM, Watkinson JC, Reconstructive techniques currently used following resection of hypopharyngeal carcinoma. *Orig. Art.* **113**: 145
Azadeh B, Baghoumian N, El-Bakri OT, Rhinosporidiosis: immunohistochemical and electron microscopic studies. *Orig. Art.* **108**: 1048
Azadeh B *see also* Alshaikhly A *et al.*
Aziz NS *see* Gendeh BS *et al.*
Azman N *see* Elango S *et al.*
El Azzouni MZ *see* Bhargava D *et al.*

Baba H *see* Yasumoto K *et al.*
Baba S *see* Ito and Baba
Baba Y *see* Nishimura G *et al.*
Babighian G, Use of a glass ionomer cement in otological surgery. A preliminary report. *Orig. Art.* **106**: 954
Babu Manohar M, Saleem M, McArthur P, Tulbah A, Laryngeal inflammation mimicking laryngeal carcinoma. *Clin. Rec.* **111**: 568
Babu Manohar M, Sharp JF, Johnson AP, Vertebro-carotid anastomosis as a cause of uncontrollable epistaxis. *Clin. Rec.* **108**: 247
Bachaud JM, David JM, Shubinski RE, Perineau D, Boussin G, Serrano E, De Forni M, Pessey JJ, Daly-Schveitzer NJ, Predictive factors of a complete response to and adverse effects of a CDDP-5FU combination as primary therapy for head and neck squamous carcinomas. *Orig. Art.* **107**: 924
Backhouse SS, Shone GR, Douglas-Jones AG, Angiolymphoid hyperplasia with eosinophilia of the parapharyngeal space. *Path. Focus* **112**: 802
Badia L, Lund VJ, Vile bodies: an endoscopic approach to nasal myiasis. *Clin. Rec.* **108**: 1083
Badia L, Parikh A, Brookes GB, Management of middle ear myoclonus. *Orig. Art.* **108**: 380
Badia L, Parikh A, Brookes GB, Pyocele of the middle turbinate. *Clin. Rec.* **108**: 783
Badia L, Weir JN Robinson AC, Heterotopic pleomorphic adenoma of the external nose. *Clin. Rec.* **110**: 376
Baer S, Hehar S, Maw AR, Tympanic membrane ossification. *Clin. Rec.* **107**: 550
Baer S, Watkinson A, Oesophageal intramural pseudodiverticulosis. *Rad. Focus* **104**: 911
Baer S, *see also* Andreassen UK *et al.*; Jonathan and Baer
Baer ST *see* Blanshard JD *et al.*
Baert AL *see* Hermans R *et al.*
Baessa, E *see* Taibah K *et al.*
Bagan JV *see* Basterra J *et al.*
Bagatin M *see* Handžić-Čuk J *et al.*
Bagger-Sjöbäck D *see* Yamashita H *et al.*
Baghoumian N *see* Azadeh B *et al.*
Baglin T *see* Arullendran P *et al.*
Baguley D *see* Moffatt DA *et al.*
Baguley DM, Beynon GJ, Grey PL, Hardy DG, Moffat DA, Audio-vestibular findings in meningioma of the cerebello-pontine angle: a retrospective review. *Orig. Art.* **111**: 1022
Baguley DM, Beynon GJ, Thornton F, A consideration of the effect of ear canal resonance and hearing loss upon white noise generators for tinnitus retraining therapy. *Orig. Art.* **111**: 810
Baguley DM, Moffat DA, Hardy DG: What is the effect of translabyrinthine acoustic schwannoma removal upon tinnitus?. *Orig. Art.* **106**: 329
Baguley DM, *see also* Farrell ML *et al.*; Gray RF *et al.*; Jayaram M *et al.*; Moffat DA *et al.*
Bahadur S, Mandibular involvement in oral cancer. *Orig. Art.* **104**: 968
Bahadur S, Kumar S, Tandon DA, Rath GK, De S, Combined therapy in advanced head and neck cancers. *Orig. Art.* **106**: 412
Bahadur S, *see also* Ahluwalia and Bahadur; Kacker A *et al.*; Kakani RS *et al.*; Singh AM *et al.*; Tandon DA *et al.*; Thakar A *et al.*
Baier G *see* Geyer G *et al.*
Bailey CM, Froehlich P, Hoeve HLJ, Management of subglottic haemangioma **112**: 765
Bailey CM *see* Al-Saati A *et al.*; Balakrishman A *et al.*; Balakrishnan and Bailey; Ford GR *et al.*; Hollis LJ *et al.*; Huchzermeyer P *et al.*; Irving RM *et al.*; Jani P *et al.*; Laing MR *et al.*; Mansell NJ *et al.*; Papsin BC *et al.*; Richards A *et al.*; Thirlwall AS *et al.*; Tostevin PMJ *et al.*; Wyatt ME *et al.*
Bailey M *see* Ejnell H *et al.*
Bain J *see* Williamson IG *et al.*

Baird AR, Hilmi O, White PS, Robertson AJ, Epithelial atypia and squamous metaplasia in nasal polyps. *Orig. Art.* **112**: 755
Baird AR, *see also* Ram B *et al.*
Bais AS, Uppal K, Logani KB, Narayan S, Acute leukaemic cell infiltration of the nose. *Clin. Rec.* **106**: 261
Bais AS, *see also* Agarwal and Bais; Bajaj Y *et al.*; Mathur NN *et al.*; Mukherjee B *et al.*
Bajaj Y, Bais AS, Mukherjee B, Tympanoplasty in children — a prospective study. *Orig. Art.* **112**: 1147
Bajaj Y, *see also* Mukherjee B *et al.*
Bak-Pedersen K *see* Egelund and Bak-Pedersen
Baker SR *see* Wolansky LJ *et al.*
Baker-Schreyer A *see* Hörmann K *et al.*
Bakey FA *see* Shafshak TS *et al.*
Bakka A *see* Boysen M *et al.*
Baky FA *see* Abou-Seif SG *et al.*
Bal IS *see* Bjerregaard B *et al.*
Balakrishnan A, Ford GR, Bailey CM, Plunging ranula following bilateral submandibular duct transposition. *Clin. Rec.* **105**: 667
Balakrishnan A, Bailey CM, Lymphangioma of the tongue. *Orig. Art.* **105**: 924
Balakrishnan A, *see also* Ford GR *et al.*; Low WK *et al.*
Balakrishnan R, Pujary K, Shah P, Hazarika P, Solitary adult myofibroma of the pinna. *Clin. Rec.* **113**: 155
Balakrishnan R, *see also* Hazarika P *et al.*; Nayak DR *et al.*
Balatsouras DG, Eliopoulos PN, Economou CN, Multiple glomus tumours. *Clin. Rec.* **106**: 538
Balatsouras DG, Kaberos AK, Eliopoulos PN, Kandiloros D, Economou CN, Cervicofacial actinomycosis presenting as acute upper respiratory tract obstruction. *Clin. Rec.* **108**: 801
Balcerzak W *see* Kręcicki T *et al.*
Baldan M *see* Ferlito A *et al.*
Baldwin D *see* Callanan V *et al.*; Gurr P *et al.*
Baldwin DL, King TT, Morrison AW, Hearing conservation in acoustic neuroma surgery via the posterior fossa. *Orig. Art.* **104**: 463
Baldwin DL, *see also* Callanan V *et al.*; Carney AS *et al.*; Williamson PA *et al.*
Baldwin M, Watkin P, The clinical application of oto-acoustic emissions in paediatric audiological assessment. *Orig. Art.* **106**: 301
Balkissoon A *see* Juman S *et al.*
Ball ABS, Meirion Thomas J, Management of parotid metastases from cutaneous melanoma of the head and neck. *Clin. Rec.* **104**: 350
Ball RY *see* Kedjanyi WK *et al.*
Ball SE *see* Connolly AAP *et al.*
Ballagh RH *see* Morris DP *et al.*
Ballance CA, A case of division of the auditory nerve for painful tinnitus. *Clin. Rec.* **105**: 1106
Balle V *see* Franzmann M-B *et al.*
Balle VH *see* Nielsen TR *et al.*
Balm AJM, Brown DH, de Vries WAEJ, Snow GB, Blindness: A potential complication of bilateral neck dissection. *Clin. Rec.* **104**: 154
Balm AJM, Hilgers FJM, Baris G, Keus RB, Pectoralis major muscle transposition: an adjunct to laryngeal preservation in severe chondroradionecrosis. *Clin. Rec.* **107**: 748
Balm AJM, *see also* Ceha HM *et al.*; Dijkstra MD *et al.*; Elias MM *et al.*; Kemper J *et al.*; Leemans CR *et al.*; Mak-Kregar S *et al.*; van der Laan BFAM *et al.*
Balraj A, Abramovich S, Shorvon P, Occult sphenoid sinusitis presenting clinically as parotid swelling: a case report. *Rad. Focus* **111**: 982
Balsitis M *see* Saunders MW *et al.*
Balyan FR *see* Aslan A *et al.*
Bamiou DE, Mahoney CO, Sirimanna T, Useful residual hearing despite radiological findings suggestive of anacusis. *Orig. Art.* **113**: 714
Bance M *see* de la Cruz and Bance; Maas S *et al.*; Ramsden R *et al.*
Bance ML *see* Bath AP *et al.*
Bandason C, Lee RJ, Fatal human cyclical neutropenia and unresolving tonsillitis and bilateral cervical abscesses. *Clin. Rec.* **105**: 487
Bandasson C *see* Murthy P *et al.*
Bandyopadhyay S, Prasad S, Singhania PK, Partial anodontia in a case of Waardenburg's syndrome. *Clin. Rec.* **113**: 672
Banerjee AMS, McLellan DR, Bingham BJG, Laryngeal involvement by cutaneous lymphoma. *Path. Focus* **113**: 948
Banerjee AR, Murty GE, Moir AA, Cervical necrotizing fasciitis: a distinct clinicopathological entity? *Clin. Rec.* **110**: 81
Banerjee AR, *see also* Allsager CM *et al.*
Banerjee PK *see* Iqbal SM *et al.*
Banerjee SS *see* Logue JP *et al.*; Slevin NJ *et al.*
Banfield GK, Brasher PF, Deans JAJ, Barker PG, Taylor WJ, Intrapetrous carotid artery aneurysm presenting as epistaxis and otalgia. *Clin. Rec.* **109**: 865
Banfield GK, Chowdhury CR, Brookstein R, Penetrating laryngeal injury: two case reports from Bosnia. *Clin. Rec.* **109**: 144
Bang G *see* el-Saggan A *et al.*
Banis C *see* Nikolaou A *et al.*
Banis CG *see* Panayiotides JG *et al.*
Banjar A *see* Asiri S *et al.*
Baños EC *see* Villarejo PL *et al.*
Bapuraj JR *see* Gupta AK *et al.*; Srinivasan S *et al.*
Bar-Lavie Y, Gatot A, Tovi F, Intraoperative herniation of a tracheostomy tube cuff. *Clin. Rec.* **109**: 159
Bar-Ziv J *see* Bodner L *et al.*
Baraka A *see* Ramadan HH *et al.*
Baraka ME, Medical education: an audit of an overseas postgraduate training programme in ENT. *Aud. Art.* **108**: 1072
Barbara M, Saliola S, Filipo R, False-positive MRI in a patient with otoneurological pathology. *Rad. Focus* **107**: 465
Barbara M, *see also* Filipo R *et al.*
Baredes S *see* Wolansky LJ *et al.*
Bar'el E *see* Gertner R *et al.*
Baris G *see* Balm AJM *et al.*; van der Laan BFAM *et al.*
Barker CS *see* Robson AK *et al.*
Barker PB *see* Lloyd and Barker
Barker PG *see* Banfield GK *et al.*
Barker S *see* Whittet HW *et al.*
Barker THW, Hosni AA, Idiopathic midline destructive disease: does it exist? *Path. Foc.* **112**: 307
Barki Y *see* Goldenberg D *et al.*; Leibermann A *et al.*; Levy I *et al.*
Barnes L *see* Fagan JJ *et al.*; Fujii H *et al.*
Barnes NM *see* Marriage and Barnes
Barnes PRJ, Lomas DA, Repeated insertion of foreign bodies into the tracheobronchial tree via tracheostomy. *Clin. Rec.* **107**: 359
Barnham M, Bradwell RA, Acute peritonsillar abscess caused by *Arcanobacterium haemolyticum*. *Clin. Rec.* **106**: 1000
Barona RL *see* O'Connor Reina C *et al.*
Barr GD, Barr J, Early marked arytenoid calcification in a case of suspected foreign body. *Clin. Rec.* **106**: 1089
Barr GD, More IAR, McCallum HM, Leiomyoma of the nasal septum. *Clin. Rec.* **104**: 891
Barr GS, Tewary AK, Alteration of airflow and mucociliary transport in normal subjects. *Orig. Art.* **107**: 603
Barr GS, *see also* Tewary AK *et al.*
Barr J *see* Barr and Barr
Barr-Hamilton RM, Matheson LM, Keay DG, Ototoxicity of cisplatinum and its relationship to eye colour. *Orig. Art.* **105**: 7
Barra S *see* Barzan L *et al.*
Barrett AW *see* Bryant C *et al.*
Barrett GS *see* Pringle MB *et al.*
Barrett-Lee P *see* Bottrill ID *et al.*
Barros E *see* Ruah CB *et al.*
Barrow M *see* Wilson PS *et al.*
Bartella L *see* Kothari P *et al.*
Bartley J, How long should ears be bandaged after otoplasty? *Orig. Art.* **112**: 531
Bartoli J-M *see* Moulin G *et al.*
Barton J *see* Heaton JM *et al.*
Barton RPE *see* Morgan NJ *et al.*; Prichard AJN *et al.*
Bartow S *see* Wong G *et al.*
Barzan L, Barra S, Franchin G, Talamini R, Zanelli G, Caruso G, Maione A, Pin M, Politi D, Gobitti C, Minatel E, Trovò GM, Comoretto R, Squamous cell carcinoma of the posterior pharyngeal wall: characteristics compared with the lateral wall. *Orig. Art.* **109**: 120
Barzan L, Franchin G, Frustaci S, De Paoli A, Comoretto R, Carcinoma of the nasal vestibule: Report of 12 cases. *Orig. Art.* **104**: 9
Barzan L, Tavio M, Tirelli U, Comoretto R, Head and neck manifestations during HIV infection. *Orig. Art.* **107**: 133

Barzan L, Veronesi A, Caruso G, Serraino D, Magri D, Zagonel V, Tirelli U, Comoretto R, Monfardini S, Head and neck cancer and ageing: a prospective study in 438 patients. *Orig. Art.* **104**: 634
Barzan L, *see also* Comoretto and Barzan
Başak S, Türkütanit S, Sarierler M, Metin KK, Effects of capsaicin pretreatment in experimentally-induced secretory otitis media. *Orig. Art.* **113**: 114
Baser B, Grewal DS, Hiranandani NL, Management of saddle nose deformity in atrophic rhinitis. *Orig. Art.* **104**: 404
Baser B, Shahani R, Khanna S, Grewal DS, Calvarial bone grafts for augmentation rhinoplasty. *Orig. Art.* **105**: 1018
Basiouny HE *see* Dawes and Basiouny
Bassiouni M *see* Rifai M *et al.*
Bassiouny M *see* Elwany and Bassiouny
Basterra J, Bagan JV, Zapater E, Armengot M, Pull-through oropharyngectomy in advanced stage malignant tumours. *Orig. Art.* **112**: 355
Batch A *see* Rogers *et al.*
Batch AJ *see* George MK *et al.*
Batch AJG *see* Weiner and Batch; Weiner GM *et al.*
Bateman AC *see* Norman L *et al.*
Bateman N, Jones NS, The use of nasal endoscopy to control profuse epistaxis from a fracture of the basisphenoid in a seven-year-old child. *Clin. Rec.* **113**: 561
Bateman ND, Johnson IJM, Gibbin KP, Susac's syndrome: a rare cause of fluctuating sensorineural hearing loss. *Clin. Rec.* **111**: 1072
Bates G *see* Koay B *et al.*
Bates GJ *see* Koay CB *et al.*
Bath AP, Bull PD, Management of upper airway obstruction, Pierre Robin sequence. *Orig. Art.* **111**: 1155
Bath AP, Murty GE, Bradley PJ, Branchial cyst — to endoscope or not? *Clin. Rec.* **106**: 1006
Bath AP, Murty GE, Gibbin KP, Munchausen syndrome by proxy: otolaryngologists beware! *Clin. Rec.* **107**: 151
Bath AP, O'Flynn P, Gibbin KP, Nasopharyngeal tuberculosis. *Clin. Rec.* **106**: 1079
Bath AP, Rowe JR, Innes AJ, Malignant otitis externa with optic neuritis. *Clin. Rec.* **112**: 274
Bath AP, Toynton SC, Innes AJ, Technique of tracheo-oesophageal puncture under local anaesthesia. *Short Comm.* **108**: 980
Bath AP, Walsh RM, Bance ML, Presumed reduction in vestibular function in unilateral Ménière's disease with aminoglycoside eardrops. *Clin. Rec.* **113**: 916
Bath AP, *see also* Kedjanyi WK *et al.*; Linton K *et al.*
Batman P *see* Martin-Hirsch DP *et al.*
Batmanghelichi O *see* Lupovitch A *et al.*
Batsakis JG *see* Carrillo R *et al.*; Cho KJ *et al.*; El-Naggar AK *et al.*; Kemp BL *et al.*
Bauer CA *see* Redleaf and Bauer
Bauer GP *see* Wiet RJ *et al.*
Bauman NM *see* Redleaf MI *et al.*
Baxter A *see* McQueen CT *et al.*; Natarajan and Baxter
Bazerbachi S *see* Wake M *et al.*
Beasley N *see* Sim RJ *et al.*
Beasley NJP, Jones NS, A modification to the brow incision for access to the anterior skull base and paranasal sinuses. *Short Comm.* **109**: 134
Beasley NJP, Jones NS, Downes RN, Enophthalmos secondary to maxillary sinus disease: single-stage operative management. *Clin. Rec.* **109**: 868
Beasley NJP, Jones NS, Ménière's disease: evolution of a definition. *Hist. Art.* **110**: 1107
Beasley NJP, Jones NS, Otoplasty: the problem of the deep conchal bowl. *Short Comm.* **110**: 864
Beasley NJP, *see also* Karkanevatos A *et al.*; Parton M *et al.*
Beasley P *see* Flynn MD *et al.*; Pringle MB *et al.*
Beaumont A *see* Callanan V *et al.*
Beck MH *see* Wilkinson and Beck
Becker M *see* Zbären P *et al.*
Beckinsale J *see* Callanan V *et al.*
Bedrin L *see* Talmi YP *et al.*
Beer K *see* Zbären P *et al.*
Begg J *see* Gray RF *et al.*
Begg JA *see* Ray J *et al.*
Bégin LR, Frenkiel S, Polypoid lipoma of the palatine tonsil. *Clin. Rec.* **107**: 556
Bégin LR, *see also* Yoskovitch A *et al.*
Behbehani A *see* Al Muhana A *et al.*
Behrendt N *see* Sorensen WT *et al.*
Beitler JJ *see* Rubin JS *et al.*
Beliaeff M *see* Richardson HC *et al.*
Bellman S *see* Vanniasegaram I *et al.*
Bellman SC *see* Papsin BC *et al.*; Tungland OP *et al.*
Belus J-F *see* Triglia J-M *et al.*
Bely N *see* Laccourreye O *et al.*
Ben David J *see* Fradis M *et al.*; Podoshin L *et al.*
Ben-Arieh Y *see* Danino J *et al.*; Hefer T *et al.*
Ben-David Y *see* Podoshin L *et al.*
Benbow EW *see* Martin-Hirsch DP *et al.*
Bende M, Mark J, Long-term effects of topical corticosteroids in the nose. *Orig. Art.* **106**: 810
Bende M, *see also* Paulsson B *et al.*
Bendet E *see* Kronenberg J *et al.*
Benghiat A *see* Soussi AC *et al.*
Bengtson H *see* Hultcrantz E *et al.*
Benharroch D *see* Kraus M *et al.*
Benicky M *see* Böör A *et al.*
Benitez A *see* Dueñas L *et al.*
Benito I, Alvarez-Gago T, Morais D, Tonsillar metastasis from adenocarcinoma of the stomach. *Path. Focus* **110**: 291
Benjamin E, Pickles J, Chlorine-induced anosmia. A case presentation. *Clin. Rec.* **111**: 1075
Benlyazid A, Lescanne E, Lefrancq T, Fetissoff F, Beutter, P, Solitary fibrous tumour of the larynx: report of a case. *Clin. Rec.* **112**: 286
Bennett J *see* Callanan V *et al.*
Bennett JDC, High tracheostomy and other errors - revisited. *Rev. Art.* **110**: 1003
Bennett JDC, Chowdhury CR, Primary amyloidosis of the larynx. *Clin. Rec.* **108**: 339
Bennett JDC, *see also* Chowdhury and Bennett; Milner and Bennett
Bennett M *see* Deans JAJ *et al.*; Morgan M *et al.*; Richardson H *et al.*
Bennett MH *see* Fairley JW *et al.*
Bennett MK *see* Murty GE *et al.*
Bensadon RL *see* Bento RF *et al.*
Bensing JM *see* van Veen ED *et al.*
Benson-Mitchell R, Buchanan G, Cervical lymphadenopathy secondary to atypical mycobacteria in children. *Orig. Art.* **110**: 48
Benson-Mitchell R, Gatland D, Kenyon G, Septoplasty as a day case procedure — a two centre study. *Orig. Art.* **110**: 129
Benson-Mitchell R, Kenyon GS, Gardiner Q, Day-stay myringoplasty. *Orig. Art.* **110**: 421
Benson-Mitchell R, Tolley N, Croft CB, Gallimore A, Aspergillosis of the larynx. *Clin. Rec.* **108**: 883
Benson-Mitchell R, Tolley N, Croft CB, Roberts D, Lipoma of the left tonsillar fossa. *Clin. Rec.* **108**: 507
Benson-Mitchell R, Tolley N, Croft CB, Roberts D, Wegener's granuloma–presenting as a unilateral parotid swelling. *Clin. Rec.* **108**: 431
Benson-Mitchell R, Warwick-Brown N, Chappell ME, Non-Hodgkin's lymphoma presenting as an isolated temporal soft tissue swelling. *Clin. Rec.* **110**: 161
Bent JP, Wood BP, Complications resulting from treatment of severe posterior epistaxis. *Clin. Rec.* **113**: 252
Bentacur TM *see* Luntz M *et al.*
Bento RF, Guatimosin MH, Bensadon RL, Sanchez TG, Voegels RL, Otological lesions in pachyonychia congenita syndrome. *Clin. Rec.* **110**: 1145
Berco E *see* Berger G *et al.*
Berenholz LP, Segal S, Kessler A, Goitre presenting as an oropharyngeal mass: an unusual finding in the elderly. *Clin. Rec.* **113**: 170
Berger G, Eustachian tube submucosal glands in normal and pathological temporal bones. *Orig. Art.* **107**: 1099
Berger G, Finkelstein Y, Avraham S, Himmelfarb M, Patterns of hearing loss in non-explosive blast injury of the ear. *Orig. Art.* **111**: 1137
Berger G, Finkelstein Y, Harell M, Non-explosive blast injury of the ear. *Orig. Art.* **108**: 395

Berger G, Ophir D, Berco E, Sadé J, Revision myringoplasty. *Orig. Art.* **111**: 517
Bergler W, Hönig M, Götte K, Petroiamu G, Hörmann K, Treatment of recurrent respiratory papillomatosis with argon plasma coagulation. *Clin. Rec.* **111**: 381
Bergler W, *see also* Keilmann A *et al.*
Berglund J *see* Theander C *et al.*
Bergmann I *see* Klima A *et al.*
Berkovits RNP, Bos CE, Wijburg FA, Holzki J, Caustic injury of the oesophagus. Sixteen years experience and introduction of a new model oesophageal stent. *Orig. Art.* **110**: 1041
Berliner KI *see* Frau GN *et al.*
Berlis A *see* Ross UH *et al.*
Bernáldez R, Nistal M, Kaiser C, Gavilán J, Malignant fibrous histiocytoma of the larynx. *Clin. Rec.* **105**: 130
Bernáldez R, Toledano A, Alvarez J, Gavilán J, Pulmonary carcinoma metastatic to the larynx. *Path. Focus* **108**: 898
Bernáldez R, *see also* De Diego JI *et al.*
Berry J *see* Owen G *et al.*
Bertino G *see* Ferlito A *et al.*
van Besouw JP *see* Hinton AE *et al.*
Betancor L *see* Campos A *et al.*
Beutter P *see* Benlyazid A *et al.*; Klossek J-M *et al.*; Klossek JM *et al.*
Beynon G, When is a decibel not a decibel? *Orig. Art.* **107**: 985
Beynon GJ *see* Baguley DM *et al.*
Bhagava K *see* Bhargava D *et al.*
Bhandarkar P, Green KMJ, de Carpentier JP, Multiple cutaneous metastases from laryngeal carcinoma. *Clin. Rec.* **111**: 654
Bhardwaj I *see* Gupta A *et al.*
Bhargava AK, Shenoy AM, Kumar RV, Rao Nanjundappa CR, Parotid tuberculosis simulating malignancy. *Path. Focus* **113**: 951
Bhargava AK, *see also* Shenoy AM *et al.*
Bhargava D, Bhusnurmath S, Daar AS, Chondroid syringoma of the nose: report of a case. *Clin. Rec.* **111**: 862
Bhargava D, Raman R, El Azzouni MZ, Bhagava K, Bhusnurmath B, Anisakiasis of the tonsils. *Clin. Rec.* **110**: 387
Bhargava D, Raman R, Khalfan Al Abri R, Bushnurmath B, Heterotopia of the tonsil. *Path. Focus* **110**: 611
Bhargava KB, Shirali GN, Abhyankar US, Gadre KC, Treatment of allergic and vasomotor rhinitis by the local application of different concentrations of silver nitrate. *Orig. Art.* **106**: 699
Bhargava KB, Uppal PK, Bhargava SK, Nanivadekar SA, Shirali GN, Burning sensation in the throat — should it be named caloripharyngeus? *Short Comm.* **108**: 235
Bhargava KB, *see also* Bhargava SK *et al.*; Hegde R *et al.*
Bhargava P *see* Grewal DS *et al.*
Bhargava S *see* Hegde R *et al.*
Bhargava SK, Bhat N, Bhargava KB, Broken tracheostomy introducer — an unusual tracheobronchial foreign body. *Clin. Rec.* **107**: 463
Bhargava SK, Gupta S, Huge retropharyngeal cold abscess in an adult with respiratory distress. *Rad. Focus* **104**: 157
Bhargava SK, *see also* Bhargava KB *et al.*
Bharucha H *see* McCluggage WG *et al.*
Bhat N *see* Bhargava SK *et al.*
Bhat NA, Oates J, An unusual foreign body of the larynx — a case report. *Clin. Rec.* **110**: 1164
Bhat NA, Stansbie JM, Tuberculous parotitis: a case report. *Clin. Rec.* **110**: 976
Bhatia N *see* Mishra SC *et al.*
Bhatia S, Karmarkar S, DeDonato G, Mutlu C, Taibah A, Russo A, Sanna M, Canal wall down mastoidectomy: causes of failure, pitfalls and their management. *Orig. Art.* **109**: 583
Bhatia S, Karmarkar S, Taibah A, Russo A, Sanna M, Vestibular schwannoma and the only hearing ear. *Clin. Rec.* **110**: 366
Bhatnagar RK, Critical evaluation of the Per–Lee tubes in children. *Orig. Art.* **104**: 112
Bhatoe HS, Deshpande GU, Cerebellopontine angle metastasis from clear cell renal carcinoma presenting as bleeding from the ear. *Clin. Rec.* **110**: 370
Bhatoe HS, Suryanarayana KV, Gill HS, Recurrent massive epistaxis due to traumatic intracavernous internal carotid artery aneurysm. *Clin. Rec.* **109**: 650
Bhattacharyya AK, Deshpande AR, Nayak SR, Kirtane MV, Ingle MV, Vora LM, Rhinocerebral mucormycosis: An unusual case presentation. *Clin. Rec.* **106**: 48
Bhattacharyya AK, Lund VJ, Unilateral choanal atresia in siblings — a rare occurrence. *Clin. Rec.* **110**: 665
Bhendwal S *see* Hosney A *et al.*
Bhide A, Computer simulation of human tympanic membrane. *Orig. Art.* **106**: 878
Bhusnurmath B *see* Bhargava D *et al.*
Bhusnurmath S *see* Bhargava D *et al.*
Bibas A *see* Skia B *et al.*; Xenellis J *et al.*
Bicciolo G *see* Ruscito P *et al.*
Bickerton RC *see* Raj P *et al.*; Tewary AK *et al.*
Bicknell P *see* Owen G *et al.*
Bicknell PG *see* Whinney DJ *et al.*
Biefel K *see* Graamans K *et al.*
Bieger AK *see* Bradwell RA *et al.*
Biermann G *see* Hörmann K *et al.*
Bilen Ç *see* Kñulahli I *et al.*
Bingham B *see* Khanobthamchai K *et al.*
Bingham BJG *see* Banerjee AMS *et al.*; Cree IA *et al.*; Heaton JM *et al.*; Padgham ND *et al.*; Prikas and Bingham
Binnington J *see* McCombe AW *et al.*
Binnington JD *see* Wake M *et al.*
Birch PJ *see* Than T *et al.*
Birch R *see* Connolly AAP *et al.*
Birchall JP *see* Aldren CP *et al.*; Deans JAJ *et al.*; Johnson IJM *et al.*; Watson MG *et al.*; Welch AR *et al.*
Birchall M *see* Lennox P *et al.*
Birchall MA, Dilkes MG, Bilateral parotid secondaries from primary bronchial carcinoid tumour.*Clin. Rec.* **105**: 489
Birchall MA, *see also* French PD *et al.*; Huchzermeyer P *et al.*
Biring GS *see* Sharp HR *et al.*
Birman CS, Gibson WPR, Hearing loss associated with large internal auditory meatus: a report of 5 paediatric cases. *Clin. Rec.* **113**: 1015
Birzgalis AR, Curley JWA, Camphor I, Pneumoparotitis, subcutaneous emphysema and pleomorphic adenoma. *Clin. Rec.* **107**: 349
Birzgalis AR, Farrington WT, O'Keeffe L, Shaw J, Localized tracheopathia osteoplastica of the subglottis. *Clin. Rec.* **107**: 352
Birzgalis AR, Ramsden RT, Curley JWA, Intralabyrinthine schwannoma. *Clin. Rec.* **105**: 659
Birzgalis AR, Ramsden RT, Farrington WT, Small M, Severe radionecrosis of the temporal bone. *Orig. Art.* **107**: 183
Birzgalis AR, Ramsden RT, Lye RH, Richardson PL, Haemangiopericytoma of the temporal bone. *Path. Focus* **104**: 998
Birzgalis AR, *see also* Hartley C *et al.*; O'Keeffe LJ *et al.*; Slevin NJ *et al.*; Woolford TJ *et al.*
Bisschop P *see* Saussez S *et al.*
Bizakis J *see* Velegrakis G *et al.*
Bjerkhoel A, Trobbe O, Frey's syndrome: treatment with botulinum toxin. *Orig. Art.* **111**: 839
Bjerre PK *see* Nyrop M *et al.*
Bjerregaard B, Okoth-Olende CA, Gatei D, Bal IS, Jensen H, Tumours of the nose and maxillary sinus. Ten year survey from Kenya. *Orig. Art.* **106**: 337
Black J *see* Irani BS *et al.*
Black JHA *see* Scally and Black
Black MJ *see* Yoskovitch A *et al.*
Blackshaw G, Thomson N, Pott's puffy tumour reviewed. *Clin. Rec.* **104**: 574
Blair RL, Irani BS, Low C, Aural papillomatosis: treatment with carbon dioxide laser. *Clin. Rec.* **112**: 565
Blair RL, McKerrow WS, The Scottish Otolaryngology Audit — laryngeal cancer audit. *Aud. Art* **108**: 332
Blair RL, McKerrow WS, Carter NW, Fenton A. Scottish tonsillectomy audit *Supplement* No. 20
Blair RL, *see also* Heaton JM *et al.*; Ram B *et al.*
Blair V *see* Evans DGR *et al.*
Blamires TL, Friedmann I, Moffat DA, Von Hippel-Lindau disease associated with an invasive choroid plexus tumour presenting as a middle ear mass. *Clin. Rec.* **106**: 429
Blandamura S *see* Megighian D *et al.*
Blaney SPA, Why paranasal sinuses? *Orig. Art.* **104**: 690
Blaney SPA, *see also* Sharp HR *et al.*
Blanshard J *see* Toma AG *et al.*
Blanshard JD, Macleod TI, Baer ST, Canter RJ, Granulomatous cutaneous T-cell lymphoma of the neck. *Path. Focus* **106**: 563
Blanshard JD, Robinson AK, Smith I, Maw AR, Long-term view of myringoplasty in children. *Orig. Art.* **104**: 758

Blanshard JD, *see also* Robson AK *et al.*
Blayney A *see* Curran AJ *et al.*
Blayney AW *see* Fenton JE *et al.*; Gaffney RJ *et al.*; Jawad and Blayney; *see* Donnelly MJ *et al.*
Bleach N *see* Scott PMJ *et al.*
Bleach NR *see* Cerovac SS *et al.*; Chalstrey SE *et al.*; Dhingra JK *et al.*; Lim JC *et al.*; McEwan JA *et al.*; Quinn SJ *et al.*; Russell JD *et al.*; Scott PMJ *et al.*
Blewitt R *see* Mayall F *et al.*
Blewitt RW *see* Osammor JY *et al.*
Blomgren K, Qvarnberg Y, Valtonen H, Spontaneous fracture of an ossified stylohyoid ligament. *Clin. Rec.* **113**: 854
von Blumenthal H, Fisher EW, Adlam DM, Moffat DA, Surgical emphysema: a novel complication of aural exostosis surgery. *Clin. Rec.* **108**: 490
von Blumenthal H, *see also* Moffat DA *et al.*
Blundell JW *see* Chatrath P *et al.*
Board T *see* Green KMJ *et al.*
Bobhate SK *see* Deshpande and Bobhate
Bodner EE, Browning GC, Chalmers FT, Chalmers TC, Can meta-analysis help uncertainty in surgery for otitis media in children. *Orig. Art.* : **105**: 812
Bodner L, Parotid sialolithiasis. *Clin. Rec.* **113**: 266
Bodner L, Tovi F, Bar-Ziv J, Teeth in the maxillary sinus - imaging and management. *Orig. Art.* **111**: 820
Bohlin L *see* Spandow O *et al.*
Boldy DAR *see* Manohar MB *et al.*
Bolia A *see* Allsager CM *et al.*
Bonachera C *see* Navarro Cunchillos M *et al.*
Bonafe A *see* Deguine L *et al.*
Bonding P *see* Nyrop and Bonding; Sørensen and Bonding
Bonnin P *see* Lallemant JG *et al.*
Böör A, Jurkovič I, Dudriková K, Kavečanský V, Friedmann I, Intestinal-type sinonasal adenocarcinoma: a sporadic case. *Path. Focus* **110**: 805
Böör A, Jurkovič I, Friedmann I, Benicky M, Dudriková K, Krajcár R, Actinomycosis of the middle ear. *Path. Focus* **112**: 800
Booth AP *see* Liddington MI *et al.*
Booth JB, Alfred Gardiner Brown (1838-1882): His contribution to the history of the development of the tuning fork. *Hist. Art.* **113**: 304
Booth JB, *see also* Chevretton EB *et al.*; Quinn SJ *et al.*
Bopuza M *see* Dueñas L *et al.*
Boreham AB *see* Fisher and Boreham
Borges A *see* Sanghvi V *et al.*
Borochovitz Z *see* Gaitini L *et al.*
Borum P *see* Rungby JA *et al.*; Walsted A *et al.*
Bos CE *see* Berkovits RNP *et al.*
Bottrill ID, Post-traumatic cholesteatoma. *Clin. Rec.* **105**: 367
Bottrill ID, Chawla OR, Ramsay AD, Salivary gland choristoma of the middle ear. *Clin. Rec.* **106**: 630
Bottrill ID, Wood S, Barrett-Lee P, Howard DJ, Mesenchymal chondrosarcoma of the maxilla. *Clin. Rec.* **108**: 785
Bottrill ID, *see also* Hartley BEJ *et al.*; Lau DPC *et al.*
Boucher BJ *see* Quinn SJ *et al.*
Bourhis J *see* Koka VN *et al.*
Bourikas Z *see* Nikolaou A *et al.*
Bourn D *see* Broomfield and Bourn; Hampson and Bourn
Bousquet J *see* Lallemant JG *et al.*
Boussin G *see* Bachaud JM *et al.*
Bowdler DA *see* Daoud A *et al.*; Hollis LJ *et al.*; McGlashan JA *et al.*; Sherman IW *et al.*; Walsh RM *et al.*
Bowen RM *see* Fagan JJ *et al.*
Bowie GL *see* Kinsella AR *et al.*
Bown SG *see* Grant WE *et al.*
Boyd P *see* Ramsden RT *et al.*; Saeed SR *et al.*
Boyle M *see* Hadley J *et al.*
Boysen M, Aasen S, Løtveit T, Bakka A, Two simultaneously occurring hypopharyngo-oesophageal diverticula. *Clin. Rec.* **107**: 49
Boysen M, *see also* Natvig K *et al.*
Bozzo C *see* Teatini GP *et al.*
Brackmann DE, Surgical treatment of vertigo. *Orig. Art.* **104**: 849
Brademann G, Werner JA, Jänig U, Mehdorn HM, Rudert H, Cemento-ossifying fibroma of the petromastoid region: case report and review of the literature. *Clin. Rec.* **111**: 152
Bradey N *see* Agrawal R *et al.*
Bradley J *see* Vanniasegaram I *et al.*
Bradley PJ, Arytenoid granuloma. *Edit. Rev.* **111**: 801
Bradley PJ, *see also* Bath AP *et al.*; Clark LJ *et al.*; Diver JP *et al.*; Mason J *et al.*; Reilly PG *et al.*; Shinkwin CA *et al.*; Thompson and Bradley; Walsh RM *et al.*
Bradwell R *see* Ameye F *et al.*
Bradwell RA, Bieger AK, Strachan DR, Homer JJ, Endoscopic laser myotomy in the treatment of pharyngeal diverticula. *Orig. Art.* **111**: 627
Bradwell RA, *see also* Barnham and Bradwell
Brahmadathan KN *see* Kurien M *et al.*
Brain C *see* Richards A *et al.*
Brain DJ *see* Kent SE *et al.*
Brake H *see* Fenton JE *et al.*
Brasher PF *see* Banfield GK *et al.*
Brasnu D *see* Crevier-Buchman L *et al.*; Laccoureye O *et al.*; Laccourreye O *et al.*
Brassier G *see* Godey B *et al.*
Braun F *see* Percodani J *et al.*
Breach NM *see* Commins DJ *et al.*; Hartley BEJ *et al.*
Breen D *see* Farrell RWR *et al.*; Roberts DN *et al.*
Bretlau P *see* Petersen BL *et al.*
Brettle RP *see* Laing RBS *et al.*
Brewer DB *see* Wendall Todd N *et al.*
Brewis C, McFerran DJ, "Farmer's ear": sudden sensorineural hearing loss due to *Chlamydia psittaci* infection. *Clin. Rec.* **111**: 855
Bricknell MCM *see* Chowdhury and Bricknell; Chowdhury CR *et al.*
Bridger M *see* Violaris and Bridger
Bridger MW *see* Eynon-Lewis and Bridger; Toma AG *et al.*
Bridger MWM *see* Saleh and Bridger
Bridges A *see* Little P *et al.*
Briggs RJS, Gallimore AP, Phelps PD, Haward DJ, Laryngeal imaging by computerized tomography and magnetic resonance following radiation therapy: a need for caution. *Rad. Focus* **107**: 565
Briggs RJS, *see also* Donnelly MJ *et al.*
Brightwell AP *see* Cox HJ *et al.*; Garth and Brightwell; Garth RJN *et al.*; Pringle MB *et al.*
Brimble E *see* Quiney RE *et al.*
Brink PRG *see* Ernest van Heurn and Brink
Bristow A *see* Mendel and Bristow
Bristow ASE *see* Evans KL *et al.*
Britton J *see* Coley SC *et al.*
Broc V *see* Dominici L *et al.*
Brock CA, An evaluation of mucus glycoproteins in the larynges of victims of sudden infant death syndrome. *Orig. Art.* **109**: 403
Brockbank M *see* Whittet HB *et al.*
Brockbank MJ *see* Harries PG *et al.*; Singh V *et al.*
Brockhurst PJ, Feltoe CK, Corrosion and fracture of a silver tracheostomy tube. *Clin. Rec.* **105**: 48
van den Broek P *see* Makhdoum MJA *et al.*
Brofeldt S *see* Stangerup S-E *et al.*
Brook I, Gober AE, Bacterial colonization of pacifiers of infants with acute otitis media. *Orig. Art.* **111**: 614
Brook L, Yocum P, Antimicrobial management of chronic sinusitis in children. *Orig. Art.* **109**: 1159
Brooker D *see* McCluggage WG *et al.*
Brooker DS, Cinnamond MJ, Young's procedure in the treatment of epistaxis. *Clin. Rec.* **105**: 847
Brooker DS, Smyth GDL, Management of posterior mesotympanic cholesteatoma. *Orig. Art.* **106**: 496
Brookes G *see* Graham J *et al.*
Brookes GB *see* Badia L *et al.*; Golding-Wood DG *et al.*; Harcourt JP *et al.*; Hellier and Brookes; Morgan and Brookes; Parikh and Brookes; Porter MJ *et al.*; Saeed and Brookes; Saeed SR *et al.*
Brookes JD *see* Ziyada WF *et al.*
Brooks JP, Morgan DW, Glaholm J, Twelve cases of glottic carcinoma *in situ* treated by radiotherapy: an observation on clinical course versus response. *Orig. Art.* **107**: 1014
Brooks JR *see* Ravi and Brooks
Brookstein R *see* Banfield GK *et al.*
Broomfield A, Bourn D, Basic techniques in molecular genetics. *Mol. Biol.* **112**: 230
Brosch S, Johannsen HS, Clinical course of acute laryngeal trauma and associated effects on phonation. *Clin. Rec.* **113**: 58

Brough M *see* Macnamara M *et al.*
Brough MD *see* East CA *et al.*
Brown CL *see* Harar RPS *et al.*; Nielsen TR *et al.*
Brown D *see* Timon CI *et al.*; Timon CVI *et al.*
Brown DH *see* Balm AJM *et al.*
Brown J *see* Hefer T *et al.*; Hefer T *et al.*9797
Brown MJ *see* Cherry and Brown
Brown MJKM *see* Hari CK *et al.*; Tomkinson A *et al.*
Brown P *see* Harkness P *et al.*
Brown PM, Fowler S, Ryan R, Rivron R, ENT day surgery in England and Wales: an audit by the Royal College of Surgeons (Eng.) Comparative Audit Service **112**: 161
Brown SG *see* Robinson PJ *et al.*
Browning GC *see* Bodner EE *et al.*
Browning GG, The British experience of an implantable, subcutaneous bone conduction hearing aid (Xomed Audiant). *Clin. Rec.* **104**: 534
Browning GG, *see also* Dempster JH *et al.*; Giles M *et al.*; McClymont and Browning; MacKenzie and Browning; Nunez and Browning; Swan and Browning
Bruins WR, Cawood RH, Blast injuries of the ear as a result of the Peterborough- lorry explosion. *Orig. Art.* **105**: 890
Brunner HG *see* Ensink RJH *et al.*
de Bruyn R *see* Tostevin PMJ *et al.*
Bryan RL *see* Manohar MB *et al.*
Bryant C, Manisali M, Barrett AW, Adenomatoid hyperplasia of palatal minor salivary glands. *Clin. Rec.* **110**: 167
Bryceson ADM *see* Grant A *et al.*
Bu-Saba N *see* Ramadan HH *et al.*
Buades J *see* Cánovas DL *et al.*
Buchanan DS, Fagan PA, Turner J, Cavernous haemangioma of the temporal bone. *Clin. Rec.* **106**: 1086
Buchanan G *see* Benson-Mitchell and Buchanan
Buchwald C, Nissen F, Thomsen J, Parapharyngeal abscess and torticollis. *Rad. Focus* **104**: 829
Buchwald C, Tos M, Thomsen J, Møller H, Parving A, Observer variations in the evaluation of facial nerve function after acoustic neuroma surgery. *Orig. Art.* **107**: 1119
Buchwald C, *see also* Franzmann M-B *et al.*; Petersen BL *et al.*
Buckland JR, Manjaly G, Violaris N, Howlett DC, Ultrasound-guided cutting needle biopsy of the parotid gland. *Orig. Art.* **113**: 988
Buckley JG, Hickey SA, Fitzgerald O'Connor AF, Does post-operative nasal packing cause nocturnal oxygen desaturation? *Short Comm.* **105**: 109
Buckley JG, Hickey SA, Fletcher CDM, Mid-line presentation of cervical lymphomata. *Path. Focus* **104**: 737
Buckley JG, Mitchell DB, Hickey SA, Fitzgerald O'Connor AF, Submucous resection of the nasal septum as an outpatient procedure. *Orig. Art.* **105**: 544
Buckley JG, *see also* England RJA *et al.*; Hickey SA *et al.*
Buffa R *see* Capaccio P *et al.*; Pignataro L *et al.*
Bull PD *see* Bath AP and Bull PD
Bull TR *see* Hoare TJ *et al.*; Journeaux SF *et al.*; Owa AO *et al.*; Premachandra DJ *et al.*
Bullock J *see* Colver GB *et al.*
Bulman C *see* Mayall F *et al.*
Bulman CH, A ten-year audit of the management of cancers of the larynx and pharynx **112**: 948
Bulman CH, *see also* Osammor JY *et al.*
Burden P *see* Koay CB *et al.*
Burgel R *see* Grant DG *et al.*
Burian P *see* Paulsson B *et al.*
Burns BV, Shotton JC, Vocal fold palsy following vinca alkaloid treatment. *Clin. Rec.* **112**: 485
Burns BV, *see also* Al-Ayoubi A *et al.*
Burrows EH *see* O'Reilly and Burrows
Burstin PP, Marshall CL, Infectious mononucleosis and bilateral peritonsillar abscesses resulting in airway obstruction. *Clin. Rec.* **112**: 1186
Burtin B *see* Haye R *et al.*
Burton M *see* Ingrams D *et al.*
Burton MJ, Leighton SEJ, Lund WS, Long-term results of submandibular duct transposition for drooling. *Orig. Art.* **105**: 101
Burton MJ, Lund WS, Pharyngeal pouch carcinoma: two unusual cases. *Clin. Rec.* **104**: 821
Bushnurmath B *see* Bhargava D *et al.*
Bussoli TJ, Steel KP, The molecular genetics of inherited deafness: current and future applications. *Mol. Biol.* **112**: 523
Butcher C *see* Osinubi OA *et al.*
Butler JD *see* Mason JDT *et al.*
Butler P *see* O'Reilly BJ *et al.*
Buyse GG, Caekebeke J, Demaerel P, Plets C, Primary brainstem tethering: a rare cause of geniculate neuralgia. *Rad. Focus* **113**: 945
Byers RM *see* El-Naggar AK *et al.*
Byl FM *see* Wayman DM *et al.*
Byrne PJ *see* Lacy PD *et al.*

Cable HR *see* Salam and Cable; Tewary AK *et al.*
Cabrera M *see* Myatt and Cabrera
Cabrera Pozuelo, E *see* Del Valle Zapico A *et al.*
Cadoni G, Marinelli L, De Santis A, Romito A, Manna R, Ottaviani F, Sudden hearing loss in a patient hepatitis C virus (HCV) positive on therapy with alpha-interferon: a possible autoimmune-microvascular pathogenesis. *Clin. Rec.* **112**: 962
Cadoni G, *see also* Almadori G *et al.*
Caekebeke J *see* Buyse GG *et al.*
Cafarelli Dees, D *see* Munro and Cafarelli Dees
Çagil N *see* Külahli I *et al.*
Cai Z, Yu G, Ma D, Tan J, Yang Z, Xhang X, Experimental studies on traumatic facial nerve injury. *Orig. Art.* **112**: 243
Cain AJ, Michie BA, Davis BC, Ram B, Focal myositis of the sternocleidomastoid muscle. *Path. Focus* **112**: 687
Cairns A *see* O'Keeffe LJ *et al.*
Çakmak A *see* Kurtulmaz SY *et al.*
Calabrese V *see* Fabretti F *et al.*
Calder C *see* O'Conell JE *et al.*
Caldicott LD *see* Hussain SSM *et al.*
Caliceti UG *see* Casolino D *et al.*
Callanan V, Capper R, Gurr P, Baldwin DL, Day-case adenoidectomy, parental opinions and concerns. *Orig. Art.* **108**: 470
Callanan V, Curran AJ, Smyth DA, Gormley PK, The influence of bismuth subgallate and adrenaline paste upon operating time and operative blood loss in tonsillectomy. *Orig. Art.* **109**: 206
Callanan V, Fitzgerald O'Connor AF, King TT, Air travel-induced meningitis following vestibular schwannoma (acoustic neuroma) surgery. *Clin. Rec.* **110**: 258
Callanan V, Gillmore K, Field S, Beaumont A, The use of magnetic resonance imaging to assess tracheal stenosis following percutaneous dilatational tracheostomy. *Orig. Art.* **111**: 953
Callanan V, Gurr P, Baldwin D, White-Thompson M, Beckinsale J, Bennett J, Provox valve use for post-laryngectomy voice rehabilitation. *Orig. Art.* **109**: 1068
Callanan V, *see also* Gurr P *et al.*
Callanan VP, Curran AJ, Gormley PK, Xenograft versus autograft in tympanoplasty. *Orig. Art.* **107**: 892
Callanan VP, *see also* Wareing MJ *et al.*
Calvert RJ, Quinn CM, Squamous cell carcinoma of the maxillary antrium metastatic to the heart and skin. *Path. Focus* **108**: 896
Camacho FJ *see* Tavin ME *et al.*
Cameron CHS *see* McCluggage WG *et al.*
Camilleri AE, Chronic sinusitis and the yellow nail syndrome. *Clin. Rec.* **104**: 811
Camilleri AE, Craniofacial fibrous dysplasia. *Clin. Rec.* **105**: 662
Camilleri AE, Information leaflets in the rhinitis clinic? *Orig. Art.* **105**: 282
Camilleri AE, Management of acquired tracheo-oesophageal fistula following intubation. *Clin. Rec.* **104**: 267
Camilleri AE, Davies FW, Aberrant central venous catheter complicating radical neck dissection. *Clin. Rec.* **105**: 491
Camilleri AE, MacKenzie K, The acceptability of secondary tracheo-oesophageal fistula creation in long-standing laryngectomees. *Orig. Art.* **106**: 231
Camilleri AE, Remamurthy L, Jones PH, Sleep nasendoscopy: what benefit to the management of snorers? *Orig. Art.* **109**: 1163
Camilleri AE, Toner JG, Howarth KL, Hampton S, Ramsden RT, Cochlear implantation following temporal bone fracture. *Clin. Rec.* **113**: 454
Camilleri AE, *see also* Ahmmed AU *et al.*; Houghton DJ *et al.*; O'Keeffe LJ *et al.*; Wheatley AH *et al.*
Campbell JB *see* Johnson IJM *et al.*; Lee WC *et al.*; Nigam A *et al.*; Snow DG *et al.*
Camphor I *see* Birzgalis AR *et al.*

Campos A, Arias A, Betancor L, Rodriguez C, Hernández AM, López Aguado D, Sierra A, Study of common aerobic flora of human cerumen. *Orig. Art.* **112**: 613
Canalis RF *see* Wackym PA *et al.*
Canals E *see* Guedea F *et al.*
Canbolat O, Akyol Ö, Kavutcu M, Ümit Isik A, Durak L, Serum adenosine deaminase and total superoxide dismutase activities before and after surgical removal of cancerous laryngeal tissue. *Orig. Art.* **108**: 849
Candiani F *see* Ferlito A *et al.*
Cannoni M *see* Dessi P *et al.*; Moulin G *et al.*; Triglias JM *et al.*
Cano SD *see* Rodriguez JLV *et al.*
Cánovas DL, Carbonell J, Torres J, Altés J, Buades J, Laryngeal leishmaniasis as initial opportunistic disease in HIV infection. *Clin. Rec.* **108**: 1089
Canöz K *see* Güney E *et al.*
Cansiz H *see* Sekercioğlu N *et al.*
Canter RJ *see* Blanshard JD *et al.*
Cantrell PJ *see* Tomkinson A *et al.*
Cao M-Y, Tomasi J-P, Gersdorff M, Deggouj N, The localization and specificity of guinea pig inner ear antigenic epitopes. *Orig. Art.* **109**: 19
Capaccio P, Pruneri G, Carboni N, Pagliari AV, Buffa R, Neri A, Ottaviani A, Pignataro L, Cyclin D1 protein expression is related to clinical progression in laryngeal squamous cell carcinomas. *Orig. Art.* **111**: 622
Capaccio P, *see also* Pignataro L *et al.*
Capelli A *see* Maurizi M *et al.*
Capildeo R *see* Osei-Lah V *et al.*
Cappello I *see* Pirodda A *et al.*
Capper R, Stewart TJ, Magennis JP, An unusual presentation of oat cell carcinoma. *Clin. Rec.* **107**: 559
Capper R, *see also* Callanan V *et al.*
Capucho C *see* Escada P *et al.*
Carbone A *see* Ferlito A *et al.*; Maurizi M *et al.*
Carbonell J *see* Cánovas DL *et al.*
Carboni N *see* Capaccio P *et al.*; Pignataro L *et al.*
Carding P *see* Loughran S *et al.*
Carding PN *see* Abdel-Aziz MF *et al.*
Carles D *see* Carrat X *et al.*
Carlin WV *see* Kumar BN *et al.*
Carney AS, Nandapalan V, JLO Travelling Fellowship 1998 Reports: **113**: 590
Carney AS, Patel N, Baldwin DL, Coakham HB, Sandeman DR, Intra-operative image guidance in otolaryngology - the use of the ISG viewing wand. *Orig. Art.* **110**: 322
Carney AS, Sharp JF, Cozens NJA, Atypically located submandibular gland diagnosed by Doppler ultrasound. *Clin. Rec.* **110**: 1171
Carney AS, *see also* Jones NS *et al.*
Carniege L *see* Dueñas L *et al.*
Carnot F *see* Laccoureye O *et al.*; Laccourreye O *et al.*
de Carpentier JP, Flanagan P, Hargreaves SP, Timms MS, An unusual cause of facial pain. *Clin. Rec.* **110**: 796
de Carpentier JP, Flanagan PM, Singh IP, Timms MS, Nassar WV, Nasopharyngeal *Corynebacterium ulcerans*: a different diphtheria. *Clin. Rec.* **106**: 824
de Carpentier JP, Hargreaves S, Zarod AP, A puzzling paediatric parotid haematoma. *Clin. Rec.* **110**: 590
de Carpentier JP, Ramamurthy L, Denning DW, Taylor PH, An algorithmic approach to aspergillus sinusitis. *Orig. Art.* **108**: 314
de Carpentier JP, Ryder WDJ, Saeed SR, Woolford TJ, Survival times of Provox valves. *Orig. Art.* **110**: 37
de Carpentier JP, *see also* Bhandarkar P *et al.*; Green and de Carpentier; Green KMJ *et al.*; Pahade A *et al.*; Yates PD *et al.*
Carrat X, Francois J-M, Devars F, Carles D, Traissac L, Horizontal glottectomy: functional and oncological results. *Orig. Art.* **111**: 833
Carrie S, Fenton PA, Necrobacillosis — an unusual case of pharyngotonsillitis. *Clin. Rec.* **108**: 1097
Carrie S, Hughes KB, Watson MG, Negative ANCA in Wegener's granulomatosis. *Clin. Rec.* **108**: 420
Carrillo R, Batsakis JG, Weber R, Luna MA, El-Naggar AK, Salivary neoplasms of the palate: A flow cytometric and clinicopathological analysis. *Path. Focus* **107**: 858
Carrillo R, El-Nagger AK, Luna MA, Rodriguez-Peralto JL, Batsakis JG, Nucleolar Organizer Regions (NORS) and myoepitheliomas: a comparison with DNA content and clinical course. *Orig. Art.* **106**: 616
Carrillo R, Rodriguez-Peralto JL, Batsakis JG, Al-Naggar AK, Primary haemangiopericytomas of the parotid gland. *Path. Focus* **106**: 659
Carruth JAS *see* Colquhoun-Flannery and Carruth; Colquhoun-Flannery W *et al.*; Harries PG *et al.*
Carruth JS *see* Harries PG *et al.*
Cartaya B *see* Dueñas L *et al.*
Carter J *see* Kothari P *et al.*
Carter K *see* Devaiah AK *et al.*
Carter N, Milroy CM, Thyroid carcinoma causing fatal laryngeal occlusion. *Clin. Rec.* **110**: 1176
Carter NW *see* Blair RL *et al.*
Caruso G *see* Barzan L *et al.*
Caslin AW *see* Jones AS *et al.*; Roland NJ *et al.*
Casolino D, Caliceti UG, Sorrenti G, Carcinoid tumours of the larynx: Report of two cases. *Clin. Rec.* **104**: 264
Cass AD *see* Donnelly MJ *et al.*
Cassidy M, Connolly CE, Clear cell carcinoma arising in a pleomorphic adenoma of the submandibular gland. *Path. Focus* **108**: 529
Cassidy M, Maher M, Keogh P, Leader M, Pseudosarcoma of the larynx: the value of ploidy analysis. *Path. Focus* **108**: 525
Cassinello E *see* Navarro Cunchillos M *et al.*
Castelli ML, Husband A, Superficial siderosis of the central nervous system: an underestimated cause of hearing loss. *Clin. Rec.* **111**: 60
Castellote MA *see* Adiego MI *et al.*
Castillo M *see* Wong G *et al.*
Castro F *see* Dessi P *et al.*
Catalfumo FJ, Golz A, Westerman ST, Gilbert LM, Joachims HZ, Goldenberg D, The epiglottis and obstructive sleep apnoea syndrome. *Orig. Art.* **112**: 940
van Cauwenberge P *see* Xu Z-M *et al.*
Cave APD *see* Thomas MR *et al.*
Cavicchi O, Farneti G, Occhiuzzi L, Sorrenti G, Laryngeal metastasis from colonic adenocarcinoma. *Clin. Rec.* **104**: 730
Cavicchi O, *see also* Tesei F *et al.*
Cawood RH *see* Bruins and Cawood
Ceha HM, Balm AJM, de Jong D, van't Veer JL, Multiple malignancies in a patient with bilateral retinoblastoma. *Clin. Rec.* **112**: 189
Celasun B *see* Günhan O *et al.*
Cemiloğlu R *see* Ünlü Y *et al.*
Cerovac SS, Vowles RH, Bleach NR, Sudden parotid swelling due to spontaneous haemorrhage. *Clin. Rec.* **112**: 497
Cerullo M *see* Almadori G *et al.*
Ceryan K *see* Güneri A *et al.*; Sutay S *et al.*
Çevikbas U *see* Süoglu Y *et al.*
Chabardes E *see* Laccoureye O *et al.*; Laccourreye O *et al.*
Chagnaud C *see* Moulin G *et al.*
Chakrabarti MK *see* Stoney and Chakrabarti
Chakravarti P *see* Sengupta A *et al.*
Chalmers FT *see* Bodner EE *et al.*
Chalmers TC *see* Bodner EE *et al.*
Chalstrey S *see* Laskiewicz B *et al.*
Chalstrey SE, Bleach NR, Cheung D, van Hasselt CA, A pneumatic artificial larynx popularized in Hong Kong. *Orig. Art.* **108**: 852
Chalstrey SE, Williams HOL, Reilly G, Necrobacillosis — an unusual cause of cervical abscess. *Clin. Rec.* **106**: 374
Chan C *see* Sethi DS *et al.*
Chan ESY *see* Pak MW *et al.*
Chan H *see* Mesko TW *et al.*
Chan HY *see* Morrissey MSC *et al.*
Chan JFC *see* Tsang WYW *et al.*
Chan JKC *see* Lee KC *et al.*; Tsang YW *et al.*; Wan SK *et al.*
Chan KKK *see* Rajenderkumar D *et al.*
Chan KL *see* Pak MW *et al.*
Chan O *see* Kothari P *et al.*
Chan ST *see* Yen PT *et al.*
Chan YM, Adams DA, Kerr AG, Syphilitic labyrinthitis — an update. *Orig. Art.* **109**: 719
Chandra Jha B, Nagarkar NM, Kochhar S, Mohan H, Dass A, Parathyroid cyst: a rare cause of an anterior neck mass. *Clin. Rec.* **113**: 73
Chandrasekaran S *see* Elango S *et al.*

Chang S-Y *see* Lu S-L *et al.*; Wang C-P *et al.*
Chantrain G *see* Delbrouck C *et al.*
Chapman J *see* Dilkes MG *et al.*
Chappell ME *see* Benson-Mitchell R *et al.*
Charabi S, Mantoni M, Tos M, Thomsen J, Cystic vestibular schwannomas: neuroimaging and growth rate. *Orig. Art.* **108**: 375
Charig MJ *see* Pringle and Charig
Charlton A *see* Herdman RCD *et al.*
Charlton G *see* Swift and Charlton
Charters P *see* Nandapalan V *et al.*
Chatrath P, Pfleiderer AG, Blundell JW, A rare case of intramuscular haemangioma in a six-year-old boy — a diagnostic dilemma. *Clin. Rec.* **112**: 1181
Chatterjee D, Ghosh TB, Ghosh BB, Size variation of mastoid air cell system in Indian people at different age groups: a radiographic planimetric study. *Orig. Art.* **104**: 603
Chatterjee S *see* Ahmmed AU *et al.*
Chaudhary N, Jain A, Gudwani S, Kapoor R, Motwani G, Intramuscular haemangioma of head and neck region. *Clin. Rec.* **112**: 1199
Chaudhuri D *see* Dubey SP *et al.*; Sengupta A *et al.*
Chauhan SR *see* Paul and Chauhan
Chaurasia MK *see* Subburaman and Chaurasia
Chavda SV, Pahor, AL, A century of ENT radiology. *Hist. Art.* **110**: 5
Chavda SV, *see also* Adams WM *et al.*; Jones RL *et al.*; Kuo MJ *et al.*; Patel K *et al.*; Umaria N *et al.*
Chawla OP *see* Bottrill ID *et al.*
Chee LWJ *see* Sethi DS *et al.*
Chee SK *see* Ga Sze H *et al.*
Cheesman A *see* Lloyd G *et al.*; Vowles R *et al.*
Cheesman AD *see* Colquhoun-Flannery W *et al.*; Fisher EW *et al.*; Hellier WPL *et al.*; Morgan DW *et al.*; Myatt HM *et al.*; Owa AO *et al.*; Russell JD *et al.*; Scott PMJ *et al.*; Spraggs PDR *et al.*; Toma AG *et al.*
Chen KTK, Weinberg RA, Simpson PR, Tschang T-P, Osteoblastoma of the nasal cavity. *Clin. Rec.* **107**: 737
Chen M-G *see* Wang D-H *et al.*
Chen W *see* Guo Y *et al.*
Cheng L *see* Hwang C-F *et al.*
Cherian T, Sebastian P, Abraham EK, Ahmed IM, Jayakumar KL, Sivaramakrishnan P, Unusual multiple metastases from malignant pleomorphic adenoma of the parotid gland. *Clin. Rec.* **106**: 652
Cherian TA, Rupa V, Raman R, External laryngeal trauma: analysis of thirty cases. *Orig. Art.* **107**: 920
Cherry JR, Brown MJ, Relief of severe hyperacusis and diplacusis in a deafened ear by cochlear labyrinthectomy. *Clin. Rec.* **110**: 57
Cheshire I *see* Proops and Cheshire
Chetan S, Nasal muco-ciliary clearance in snuff users. *Orig. Art.* **107**: 24
Cheung D *see* Chalstrey SE *et al.*
Cheung HS *see* Porter MJ *et al.*
Chevretton EB, McRae RDR, Booth JB, Mastoidectomy packs: Xeroform or BIPP? *Orig. Art.* **105**: 916
Chevretton EB, Morrison GAJ, The hayfork: an aid to safer tonsillectomy. *Short Comm.* **105**: 33
Chevretton EB, *see also* Davis JP *et al.*; Dilkes MG *et al.*; Morrison GAJ *et al.*; O'Reilly BJ *et al.*
Chew KK, Sethi DS, Stanley RE, Sng I, Synovial cell sarcoma of the hypopharynx. *Path. Focus* **106**: 285
Chi Fai Tong M, Kong Sang Woo J, Lun Sham C, van Hasselt CA, Ingested foreign bodies: a contemporary management approach. *Orig. Art.* **109**: 965
Chiang PK *see* Wolansky LJ *et al.*
Chitre VV, Prinsley PR, Hashmi SMH, Pneumopericardium: an unusual manifestation of blunt tracheal trauma. *Clin. Rec.* **111**: 387
Chiu PM *see* Nicholls JM *et al.*
Cho J-H, Lee D-H, Lee N-S, Won Y-S, Yoon H-R, Suh B-D, Size assessment of adenoid and nasopharyngeal airway by acoustic rhinometry in children. *Orig. Art.* **113**: 899
Cho KJ, El-Naggar AK, Mahanupab P, Luna MA, Batsakis JG, Carcinoma ex-pleomorphic adenoma of the nasal cavity: a report of two cases. *Path. Focus* **109**: 677
Choh K *see* Tsunoda K *et al.*
Chon K-M *see* Roh H-J *et al.*
Chong P *see* Abadir WF *et al.*
Chong PY *see* Leong HK *et al.*
Chong V *see* Sethi DS *et al.*
Chong VFH, Trigeminal neuralgia in nasopharyngeal carcinoma. *Rad. Focus* **110**: 394
Chong VFH, Fan YF, Jugular foramen involvement in nasopharyngeal carcinoma. *Rad. Focus* **110**: 987
Chong VFH, Mukherji SK, Goh CHK, The suprahyoid neck: normal and pathological anatomy. *Rev. Art.* **113**: 501
Chong VFH *see also* Hong Y *et al.*
Chong WH *see* Derias NW *et al.*
Chong YW *see* Lee KC *et al.*
Chou J-C *see* Lin C-H *et al.*
Chow LT, Chow W, Shum BS, Fatal massive upper respiratory tract haemorrhage: an unusual complication of localized amyloidosis of the larynx. *Clin. Rec.* **107**: 51
Chow LTC, Chow WH, Co-existing pleomorphic and tubular basal cell adenomas of the parotid gland. *Path. Focus* **111**: 182
Chow LTC, Kumta SM, King WWK, Extra-articular pigmented villonodular synovitis of the temporomandibular joint. *Clin. Rec.* **112**: 182
Chow LTC, *see also* Tsang WYW *et al.*
Chow SK *see* Tong and Chow
Chow W *see* Chow LT *et al.*
Chow WH *see* Chow and Chow
Chowdhury CR, Bennett JDC, Dysphagia caused by a foreign body in the thyroid. *Clin. Rec.* **107**: 1057
Chowdhury CR, Bricknell MCM, The management of quinsy — A prospective study. *Orig. Art.* **106**: 986
Chowdhury CR, Bricknell MCM, MacIver D, Oesophageal foreign body: an unusal cause of respiratory symptoms in a three week old baby. *Clin. Rec.* **106**: 556
Chowdhury CR, *see also* Banfield GK *et al.*; Bennett and Chowdhury
Choy ATK, Gluckman PGC, Tony MCF, van Hasselt CA, Flexible nasopharyngoscopy for fish bone removal from the pharynx. *Orig. Art.* **106**: 709
Choy ATK, John DG, van Hasselt CA, Posterior epistaxis and the undeflatable Foley's urinary catheter balloon. *Clin. Rec.* **107**: 142
Choy ATK, Su AP, Bipolar diathermy or ligation for haemostasis in tonsillectomy? A prospective study on post-operative pain. *Orig. Art.* **106**: 21
Choy ATK, *see also* Tang NLS *et al.*
Choy DTK *see* Lau SK *et al.*
Christensen J *see* Nyrop M *et al.*
Christensen NR, Jacobsen SD, Parotidectomy: preserving the posterior branch of the great auricular nerve. *Orig. Art.* **111**: 556
Christmas H *see* Heaton JM *et al.*
Christmas HE, Mills RP, Davies R, Diabetes insipidus and hypercalcaemia secondary to nasopharyngeal carcinoma. *Clin. Rec.* **104**: 43
Christmas HE, *see also* Vaughan-Jones RH *et al.*
Christodoulou C *see* Murthy P *et al.*
Chrobok, V *see* Núñez-Fernández D *et al.*
Chu TWF *see* Gluckman PGC *et al.*
Chua D *see* Nicholls JM *et al.*
Chuah CH *see* Siar CH *et al.*
Chughtai A *see* Muzaffer M *et al.*
Chukuezi AB, Nasal septal haematoma in Nigeria. *Orig. Art.* **106**: 396
Chung GH *see* Hong KH *et al.*
Chung SK, Dhong HJ, Na DG, Mucus circulation between accessory ostium and natural ostium of maxillary sinus. *Rad. Focus* **113**: 865
Çiftçioğlu A *see* Sutbeyaz Y *et al.*
Çiftçioğlu MA *see* Selimoğlu E *et al.*
Cinamon U, Kronenberg J, Hildesheimer M, Taitelbaum R, Cochlear implantation in patients suffering from Cogan's syndrome. *Orig. Art.* **111**: 928
Cinnamond MJ *see* Brooker and Cinnamond; Cullen and Cinnamond; Hampton and Cinnamond
Clancy MJ, Bronchoscopic removal of an inhaled, sharp, foreign body: an unusual complication. *Clin. Rec.* **113**: 849
Clark AH *see* Lancaster JL *et al.*
Clark D *see* Irani BS *et al.*

Clark LJ, Narula AA, Morgan DAL, Bradley PJ, Squamous carcinoma of the temporal bone: a revised staging. *Orig. Art.* **105**: 346
Clark SEM *see* Rockall TA *et al.*
Clarke G *see* Richardson HC *et al.*
Clarke GP *see* Hawthorne MR *et al.*
Clarke PM *see* Draper MR *et al.*; Fisher EW *et al.*; Hickey and Clarke
Clarke R *see* Roland NJ *et al.*; Viani L *et al.*
Clarke RW, Oliver St. John Gogarty. *Hist. Art.* **111**: 15
Clarke RW, Jones AS, The distribution of nasal airflow sensitivity in normal subjects. *Orig. Art.* **108**: 1045
Clarke RW, Jones AS, Richardson H, Peak nasal inspiratory flow: the plateau effect. *Orig. Art.* **109**: 399
Clarke RW, *see also* Jackson SR *et al.*; Panarese A *et al.*
Clarke SEM *see* Watkinson JC *et al.*
Clary RA *see* Al-Saati A *et al.*
Claveguera T *see* Gonzalez-Compta X *et al.*
Clayton MI *see* Hari CK *et al.*
Le Cleche G *see* Godey B *et al.*
Clegg RJ *see* Parker AJ *et al.*
Clegg RT *see* Jepson RH *et al.*; Parker AJ *et al.*; SR *et al.*
Clemens A *see* Vanden Abeele D *et al.*
Clement F *see* Nielsen TR *et al.*
Clement PAR *see* Gordts F *et al.*
Clerk LJ, Wakeel R, Omerod A, Relapsing polychondritis — two cases with tracheal stenosis and inner ear involvement. *Clin. Rec.* **106**: 841
Clifford AR, Fagan PA, Doust BD, Isolated congenital round window absence. *Clin. Rec.* **104**: 980
Clifford KMA *see* Dingle AF *et al.*
Clifton A *see* Coley SC *et al.*
Clifton AG *see* Phelps and Clifton
Coady AT *see* Hadley J *et al.*
Coakham HB *see* Carney AS *et al.*
Coakley D *see* Atlas and Coakley
Coakley DJ, Turner J, Fagan PA, Osteoma of the internal auditory canal: case report. *Clin. Rec.* **110**: 158
Coakley FV *see* Marshall JN *et al.*
Coakley JF, Arthurs GJ, Wilsher TK, The need for and development of a single use disposable nasal spray. *Orig. Art.* **107**: 20
Coales UF, Tandon P, Hinton AE, Limitations of imaging for foreign bodies in parapharyngeal abscess and the importance of surgical exploration. *Rad. Focus* **113**: 683
Coatesworth AP, Martin-Hirsch DP, MacDonald A, Post-irradiation liposarcoma of the temporal bone. *Clin. Rec.* **110**: 779
Cocks HC, Kumar BN, Das Gupta AR, Simms MH, Free jejunal patch flaps in oral and oro-pharyngeal reconstruction. *Clin. Rec.* **113**: 680
Coddington R *see* Fenton CJV *et al.*; Garth RJN *et al.*
Codling BW *see* Wake M *et al.*
van der Coer JMG, Marres HAM, Wielinga EMJ, Wong-Alcala LSM, Rhinosporidiosis in Europe. *Clin. Rec.* **106**: 440
Cogan E *see* Saussez S *et al.*
Cohen D *see* Ruah CB *et al.*
Cohen O, Herskovitz P, Shindell B, Leiba S, Hadar H, Pitfalls in the follow-up of cervical and mediastinal goitres: role of CT imaging. *Clin. Rec.* **106**: 65
Cohen-Kerem R, Uri N, Rennert H, Peled N, Greenberg E, Efrat M, Acute mastoiditis in children: is surgical treatment necessary? *Orig. Art.* **113**: 1081
Cokkeser Y *see* Naguib MB *et al.*
Cola C *see* Gherardi G *et al.*
Cole J *see* Pahor and Cole
Cole P *see* Tvinnereim M *et al.*
Coleman DV *see* Sarker SK *et al.*
Coleman N *see* Lale AM *et al.*
Coles RRA, Lutman ME, Robinson DW, The limited accuracy of bone-conduction audiometry: its significance in medicolegal assessments. *Orig. Art.* **105**: 518
Coley SC, Clifton A, Britton J, Giant aneurysm of the petrous internal carotid artery: diagnosis and treatment. *Rad. Focus* **112**: 196
Coley SC, *see also* Hern JD *et al.*
Cölhan I *see* Süoglu Y *et al.*
Colin JF *see* Courteney-Harris RG *et al.*
Collins CD *see* Slevin NJ *et al.*
Collins G *see* Gaitini L *et al.*
Collins M, Hawthorne M, El-Hmd K, Cochlear implantation in a district general hospital: problems and complications in the first five years. *Orig. Art.* **111**: 325
Collins M, Ryan R, Single grade specialist training in otolaryngology — a survey of attitudes among present and recent trainees. *Rev. Art.* **108**: 291
Collins MM, Wight RG, Posterior tracheal wall diverticula - an unexpected finding. *Clin. Rec.* **111**: 663
Collins MM, *see also* Scott RF *et al.*
Colloby P *see* Prichard AJN *et al.*
Colmenero B *see* Colmenero C *et al.*
Colmenero C, Esteban R, Albarino AR, Colmenero B, Sleep apnoea syndrome associated with maxillofacial abnormalities. *Orig. Art.* **105**: 94
Colquhoun I *see* Cumberworth VL *et al.*; Hill J *et al.*; Rowe-Jones J *et al.*
Colquhoun IR *see* Watson MG *et al.*
Colquhoun-Flannery W, Carruth JAS, Diet-modified sex hormone metabolism: is this the way forward in recurrent respiratory papillomatosis and squamous carcinoma prophylaxis? *Clin. Rec.* **109**: 873
Colquhoun-Flannery W, Carruth JAS, Cheesman AD, Laryngeal papillomatosis with subsequent development of papillomata in the paranasal sinuses — is it seeding by intubation? *Clin. Rec.* **109**: 238
Colreavy MP *see* Lacy PD *et al.*
Colver GB, Davis S, Bullock J, Infra-red coagulation for bleeding mucosal telangiectasia. *Short Comm.* **106**: 992
Comas C *see* Dueñas L *et al.*
Combelles R *see* Allias-Montmayeur F *et al.*
Comin CE, Dini M, Russo GL, Oncocytoma of the nasal cavity: report of a case and review of the literature. *Path. Focus* **111**: 671
Commins D *see* Koay CB *et al.*
Commins DJ, O'Malley S, Athanasou NA, Jalloh S, Giant cell tumour of the hyoid — first reported case. *Clin. Rec.* **113**: 566
Commins DJ, Roberts D, Fisher C, Breach NM, Seeding of parotid pleomorphic adenoma. *Clin. Rec.* **109**: 671
Commins DJ, Tolley NS, Milford CA, Fibrous dysplasia and ossifying fibroma of the paranasal sinuses. *Clin. Rec.* **112**: 964
Comoretto R, Barzan L, Benign parotid tumour enucleation — A reliable operation in selected cases. *Orig. Art.* **104**: 706
Comoretto R, *see also* Barzan L *et al.*; BarzanL *et al.*
Conboy PJ, Johnson IJM, Jaspan T, Jones NS, Idiopathic diffuse erosion of the skull base presenting as cerebrospinal fluid rhinorrhoea. *Rad. Focus* **112**: 679
Condom E *see* Gonzalez-Compta X *et al.*
Conlon B, Daly N, Temperely I, McShane D, ENT surgery in children with inherited bleeding disorders. *Orig. Art.* **110**: 947
Conlon BJ, Curran A, Timon CV, Pitfalls in the determination of intracranial spread of complicated suppurative sinusitis. *Clin. Rec.* **110**: 673
Conlon BJ, O'Dwyer T, The G syndrome/Opitz oculo-genital-laryngeal syndrome/Opitz BBB/G syndrome/Opitz–Frias syndrome. *Clin. Rec.* **109**: 244
Conlon BJ, O'Dwyer TP, Thoraco-cervical fibromatosis: treatment by surgical excision. *Clin. Rec.* **111**: 385
Connolly AAP, Davis JP, Stafford ND, Oropharyngeal trauma during routine ear, nose and throat procedures. *Clin. Rec.* **108**: 403
Connolly AAP, MacKenzie K, Paediatric neck masses - a diagnostic dilemma? *Orig. Art.* **111**: 541
Connolly AAP, Martin J, White P, Sedation with a target-controlled propofol infusion system during assessment of upper airway in snorers. *Short Comm.* **108**: 865
Connolly AAP, Rowe-Jones J, Leighton SEJ, Ball SE, Davies EG, Moore-Gillon V, Pseudomonal supraglottitis occuring in a patient with profound neutropenia secondary to virus-associated haemophagocytic syndrome. *Clin. Rec.* **106**: 739
Connolly AAP, Waldron J, Stafford N, Birch R, Chronic bone abscess as an unusual cause of dysphagia. *Clin. Rec.* **105**: 1084
Connolly AAP, *see also* White PS *et al.*
Connolly CE *see* Cassidy and Connolly
Conrad GJ, 'Collective stapedectomy' (An approach to the numbers problem). *Orig. Art.* **104**: 390
Considine N *see* Donnelly MJ *et al.*
Constantinidis J *see* Keerl R *et al.*

Contencin P *see* Gumpert L *et al.*
Cook HT *see* Toynton SC *et al.*
Cook JA, Irving RM, Role of tympanic neurectomy in otalgia. *Orig. Art.* **104**: 114
Cook JA, *see also* Murrant NJ *et al.*
Cook T *see* Thomas DM *et al.*
Cooke LD, Hadley DM, MRI of the paranasal sinuses: incidental abnormalities and their relationship to symptoms. *Orig. Art.* **105**: 278
Cooke LD, *see also* Espinoza FI *et al.*; Jones AS *et al.*
Cooke RA *see* Dubey SP *et al.*
Cooke TG *see* Jones AS *et al.*
Cooper DA *see* Harrison HC *et al.*
Cör A *see* Zidar N *et al.*
Corbett MJ *see* Roberts DN *et al.*
Cordoba M *see* Ophir D *et al.*
Corina L *see* Galli J *et al.*
Corney C *see* El-Silimy and Corney
Corry J *see* O'Hanlon DM *et al.*
Da Costa P *see* Santana-Hernandez DJ *et al.*
Costello S *see* Ruske DR *et al.*
Cotayo R *see* Dueñas L *et al.*
Cotlear D *see* Talmi YP *et al.*
Couldery AD, Tuberculosis of the upper respiratory tract misdiagnosed as Wegener's granulomatosis: an important distinction. *Clin. Rec.* **104**: 255
Coumbe A *see* Irving RM *et al.*
Counter RT *see* Murrison AW *et al.*
Coup A, Williamson JMS, Curley JWA, Septal, widely infiltrative and clinically occult adenoid cystic carcinoma of the parotid gland. *Clin. Rec.* **111**: 491
Court I *see* Gray RF *et al.*; Ray J *et al.*
Courteney-Harris R *see* Kesse WK *et al.*
Courteney-Harris RG, Ford GR, Ganiwalla TMJ, Mangat KS, Closure of tympanic membrane perforation after the removal of Goode-type tympanostomy tubes: the use of silastic sheeting. *Orig. Art.* **106**: 960
Courteney-Harris RG, Ford GR, Innes AJ, Colin JF, Pulsatile tinnitus: three cases of arteriovenous fistula treated by ligation of the occipital artery. *Clin. Rec.* **104**: 421
Courteney-Harris RG, Goddard MJ, Sinus histiocytosis with massive lymphadenopathy (Rosai-Dorfman Disease): a rare case of subglottic narrowing. *Clin. Rec.* **106**: 61
Courteney-Harris RG, Mills RP, Aniridia and deafness: an inherited disorder. *Clin. Rec.* **104**: 419
Courteney-Harris RG, *see also* Ford and Courteney-Harris; Kumar BN *et al.*; Mitchell TE *et al.*
Courtnay Bennett JD, Riddington-Young J, Draffin and his rods. *Hist. Art.* **106**: 1035
Cowan IA *see* White PS *et al.*
Cowan RA *see* Slevin NJ *et al.*
Cox GJ *see* Vinayak BC *et al.*
Cox HJ, Brightwell AP, Riordan T, Non-tuberculous mycobacterial infections presenting as salivary gland masses in children: investigation and conservative management. *Orig. Art.* **109**: 525
Cox HJ, Ford GR, Hearing loss associated with weapons noise exposure; when to investigate an asymmetrical loss. *Orig. Art.*. **109**: 291
Cox HJ, *see also* Pearson CR *et al.*
Cox PM *see* Robinson AC *et al.*
Cozens NJA *see* Carney AS *et al.*
Crankson S *see* Senthikumaran G *et al.*
Craven C *see* Tomkinson A *et al.*
Creagh TM *see* Ingrams DR *et al.*
Cree IA, Bingham BJG, Ramesar KCRB, Granular cell tumour of the larynx. *Rad. Focus* **104**: 159
Cremers CWRJ *see* Ensink RJH *et al.*; Marres HAM *et al.*; Mylanus and Cremers; van Leeuwen JPPM *et al.*
Crevier-Buchman L, Laccourreye O, Weinstein G, Garcia D, Jouffre V, Brasnu D, Evolution of speech and voice following supracricoid partial laryngectomy. *Orig. Art.* **109**: 410
Crevier-Buchman L, *see also* Laccourreye O *et al.*
Cristofari P *see* Magliulo G *et al.*
Crockard HA *see* Hellier WPL *et al.*
Crocker J *see* Kuo MJ *et al.*; Trendell-Smith NJ *et al.*
Crocker K, Watson MG, Non-Hodgkin's lymphoma involving the tonsil. *Orig. Art.* **105**: 445
Croft CB, Golding-Wood DG, Uses and complications of uvulopalatopharyngoplasty. *Orig. Art.* **104**: 871
Croft CB, *see also* Benson-Mitchell R *et al.*; Habashi and Croft; Ingrams DR *et al.*; McBrien F *et al.*; McFerran DJ *et al.*; Vowles RH *et al.*
Croitoru M *see* Gaitini L *et al.*
Crooks L *see* Wong G *et al.*
Cross P, A travelling tonsillectomy kit. *Edit.* **107**: 1086
Cross S *see* Fairley JW *et al.*
Crowther J *see* White PS *et al.*
Crowther JA *see* Thompson and Crowther; Watson C *et al.*
de la Cruz M, Bance M, Bilateral sudden sensorineural hearing loss following non-otologic surgery. *Clin. Rec.* **112**: 769
Cuddihy P *see* Osborne JE *et al.*
Cuddihy PJ, Maheshwar A, Griffith H, Symptomatic heterotopic gastric mucosa in the upper oesophagus. *Clin. Rec.* **112**: 979
Cuddihy PJ, Srinivasan V, An unusual presentation of a nasal septal abscess. *Clin. Rec.* **112**: 776
Cuddihy PJ, *see also* Quine SM *et al.*
Cui P-C, Ohsaki K, Li K, Tenshin S, Kawata T, Subcutaneous tissue reaction to synthetic auditory ossicle (Apaceram) in rats. *Orig. Art.* **109**: 14
Ćuk V *see* Handžić-Ćuk J *et al.*
Cullan J *see* McCluggage WG *et al.*
Cullen JR, Ovarian carcinoma metastatic to the larynx. *Clin. Rec.* **104**: 48
Cullen JR, Cinnamond MJ, Hearing loss in diabetics. *Orig. Art.* **107**: 179
Cullen JR, Primrose WJ, Vaughan CW, Osteomyelitis as a complication of a tracheo-oesophageal puncture. *Clin. Rec.* **107**: 242
Cullen RJ *see* Ahmad I *et al.*; Jay S *et al.*
Cullington HE, Cochlear implantation of a deaf blind patient with mitochondrial cytopathy. *Clin. Rec.* **113**: 353
Cumberworth VL, Djazaeri B, Mackay IS, Endoscopic fenestration of choanal atresia. *Orig. Art.* **109**: 31
Cumberworth VL, Friedmann I, Glover GW, Late metastasis of breast carcinoma to the external auditory canal. *Path. Focus* **108**: 808
Cumberworth VL, Ohri A, Morrissey G, Stirling R, Late sinonasal metastasis from follicular thyroid carcinoma. *Path. Focus* **108**: 1010
Cumberworth VL, Robinson AC, *Mycobacterium avium — intracellulare* cervical lymphadenitis in siblings: a case report and review. *Clin. Rec.* **109**: 70
Cumberworth VL, Russell J, Colquhoun I, Mackay IS, Pneumatization of the uncinate process. *Rad. Focus* **107**: 361
Cumberworth VL, *see also* Curtin JJ *et al.*; Moffat DA *et al.*; Thomas KM *et al.*
Cüreoğlu S *see* Külahli I *et al.*; Osma Ü *et al.*
Curley JWA, Ramsden RT, Howell A,, Healy K, Lye RH, Oestrogen and progesterone receptors in acoustic neuroma. *Orig. Art.* **104**: 865
Curley JWA, *see also* Birzgalis AR *et al.*; Coup A *et al.*; Green KMJ *et al.*; Pace-Balzan A *et al.*
Curran A *see* Conlon BJ *et al.*
Curran AJ, Malik N, McShane D, Timon CVI, Surgical management of lymphangiomas in adults. *Clin. Rec.* **110**: 586
Curran AJ, O'Dwyer TP, Blayney A, Emergency tracheostomy in a patient with Melnick–Needles Syndrome and sleep apnoea. *Clin. Rec.* **107**: 647
Curran AJ, *see also* Callanan V *et al.*; Callanan VP *et al.*
Curry AR *see* Lim and Curry; Tewary and Curry
Curtin JJ, Ridley NTF, Cumberworth VL, Glover GW, Pneumoparotitis. *Rad. Focus* **106**: 178
Czigner J, Fekete-Szabó G, Neurofibroma of the supraglottic larynx in childhood. *Clin. Rec.* **108**: 156
Czigner J, *see also* Szilvassy J *et al.*

Da Costa P *see* Santana-Hernandez DJ *et al.*
Daar AS *see* Bhargava D *et al.*
Dabrowski MT, Keith AO, Three cases of mycobacterial cervical lymphadenitis. *Clin. Rec.* **108**: 514
Daelemans P *see* Van Vooren JP *et al.*
Daghistani KJ, Jamal TS, Zaher S, Nassif OI, Allergic aspergillus sinusitis with proptosis. *Orig. Art.* **106**: 799
Dahlström M *see* Spandow O *et al.*
Dahm SL *see* Andreassen UK *et al.*

D'Alatri L *see* Almadori G *et al.*
Dalby JE *see* Viani L *et al.*
Dallai S *see* Gulisano M *et al.*
Daly CA *see* Donnelly MJ *et al.*
Daly N *see* Conlon B *et al.*
Daly-Schveitzer NJ *see* Bachaud JM *et al.*
Damas F *see* Ducñas L *et al.*
Damkjaer Jensen K *see* Hald J *et al.*
Damm M *see* Jungehülsing M *et al.*
Dammeijer P *see* Viani L *et al.*
Dammeijer PF, McCombe AW, Meningitis from canine *Pasteurella multocida* following mastoidectomy. *Clin. Rec.* **105**: 571
Danić D, Miličić D, Prgomet D, Leović D, Acute laryngeal trauma: a comparison between peacetime and wartime injuries. *Orig. Art.* **110**: 435
Danić D, Miličić D, Prgomet D, Leović D, Prognostic factors in carcinoma of the larynx: relevance of DNA ploidy, S-fractions and localization of the tumour. *Orig. Art.* **113**: 538
Danielidis V *see* Kastanioudakis I *et al.*
Daniilidis I *see* Nikolaou AC *et al.*
Daniilidis J, Nikolaou A, Fountzilas G, Sombolos K, Vertical partial laryngectomy: our results after treating cases of T_2 and T_3 laryngeal carcinomas. *Orig. Art.* **106**: 349
Daniilidis J, Nikolaou A, Symeonidis V, Our experience in the surgical treatment of T_1 carcinoma of the vocal cord. *Orig. Art.* **104**: 222
Daniilidis J, *see also* Nikolaou A *et al.*
Danino J, Joachims HZ, Ben-Arieh Y, Hefer T, Weyl-Ben-Arush M, T-cell lymphoma of the ear presenting as mastoiditis. *Clin. Rec.* **111**: 852
Danino J, *see also* Goldenberg D *et al.*; Nir D *et al.*
Daoud A, Lannigan FJ, McGlashan JA, Keen CE, Bowdler DA, Verrucous carcinoma of the maxillary antrum. *Path. Focus* **105**: 696
Darby Y *see* Golding-Wood *et al.*
Darby YC *see* Scadding GK *et al.*
Dardick I *see* Klumpp TR *et al.*; Timon CI *et al.*
Darwish A *see* Janahi WM *et al.*; Pamaraju N *et al.*
Das A *see* Srinivasan S *et al.*
Das Gupta A *see* Dhaliwal J *et al.*
Das Gupta AR *see* Cocks HC *et al.*; Hogg RP *et al.*; Lee SJ *et al.*; Liddington MI *et al.*; Nigam A *et al.*; Nigam and Das-Gupta
Das VK *see* Ahmmed AU *et al.*
Dashti H *see* Al Muhana A *et al.*
Dass A *see* Chandra Jha B *et al.*; Goyal A *et al.*
Datoo M *see* Murthy P *et al.*
Daud AS, Pahor AL, Tympanic neurectomy in the management of parotid sialectasis. *Orig. Art.* **109**: 1155
Daum REO, O'Reilly BJ, The laryngeal mask airway in ENT surgery. *Orig. Art.* **106**: 28
Dauod A *see* McGlashan JA *et al.*
Davenport P *see* Ramamurthy L *et al.*
David JM *see* Bachaud JM *et al.*
David TM *see* Job A *et al.*
David VC *see* Shenoy and David
David YB, Fradis M, Goldstein Y, Podoshin L, Bilateral perilymph fistula in an adult. *Clin. Rec.* **105**: 304
David YB, *see also* Podoshin L *et al.*
Davidson NMcD *see* Louis N *et al.*
Davidsson Å, Hellquist HB, Villman K, Westman G, Malignant melanoma of the ear. *Orig. Art.* **107**: 798
Davies AN, A comparison of artificial saliva and pilocarpine in radiation induced xerostomia. *Orig. Art.* **108**: 663
Davies D *see* Stafford N *et al.*
Davies EG *see* Connolly AAP *et al.*
Davies FW *see* Camilleri and Davies
Davies R, Prasher D, O'Sullivan A, An unusual case of deafness with speech impairment: lesson in diagnosis and management. *Clin. Rec.* **109**: 1085
Davies R, *see also* Christmas HE *et al.*
Davies W *see* Stoney PJ *et al.*
Davilis D *see* Kandiloros DC *et al.*
Davis A *see* Jones *et al.*; McCombe AW *et al.*; Wharton and Davis
Davis BC *see* Cain AJ *et al.*
Davis JP, Respiratory obstruction associated with the use of the Brighton epistaxis balloon. *Clin. Rec.* **107**: 140
Davis JP, Hyde JAJ, Management of acute dilatation of the oesophagus presenting as stridor. *Clin. Rec.* **106**: 744
Davis JP, Maclennan KA, Schofield JB, Watkinson JC, Gluckman P, Synchronous primary mucosal melanoma and mucoepidermoid carcinoma of the maxillary antrum. *Clin. Rec.* **105**: 370
Davis JP, Maisey MN, Chevretton EB, Positron emission tomography: a useful imaging technique for otolaryngology, head and neck surgery? **112**: 125
Davis JP, Prinsley PR, Robinson PJ, Cervical lymphadenopathy due to mycobacterial infection: a diagnostic protocol. *Orig. Art.* **107**: 614
Davis JP, Toma AG, Robinson PJ, Friedmann I, Ossified thyroglossal cyst — is it of embryological significance? *Clin. Rec.* **108**: 168
Davis JP *see also* Connolly AAP *et al.*; Robinson PJ *et al.*
Davis S *see* Colver GB *et al.*
Dawes PJD, Early complications of surgery for chronic otitis media. *Orig. Art.* **113**: 803
Dawes PJD, Basiouny HE, Outcome of using magnetic resonance imaging as an initial screen to exclude vestibular schwannoma in patients presenting with unilateral tinnitus. *Orig. Art.* **113**: 818
Dawes PJD, O'Keefe L, Adcock S, Informed consent: the assessment of two structured interview approaches compared to the current approach. *Orig. Art.* **106**: 420
Dawes PJD, O'Keefe L, Adcock S, Informed consent: using a structured interview changes patient's attitudes towards informed consent. *Orig. Art.* **107**: 775
Dawes PJD, *see also* Than T *et al.*; Watson MG *et al.*
Dawkins RS *see* Ganesan S *et al.*
Dawlatly EE, Radical mastoid cavity reconstruction — the pedicled musculo-fascial flap. *Orig. Art.* **106**: 124
Dawlatly EE, Radiological diagnosis of rhinoscleroma — the 'Palatal Sign'. *Rad. Focus* **105**: 968
Dawlatly EE, Al-Arfaj AL, Al-Azizi MA, Paediatric foreign bodies: the lessons of failure and near misses. *Orig. Art.* **105**: 755
Dawson AA *see* Neilly IJ *et al.*
Daya H, Fawcett WJ, Weir N, Vocal fold palsy after use of the laryngeal mask airway. *Clin. Rec.* **110**: 383
Daya H, Gallimore A, Recurrent laryngeal papillomatosis: a case of florid papillomatosis following a remission of 30 years. *Clin. Rec.* **107**: 636
Daya S, To SS, A "silent" intracranial complication of frontal sinusitis. *Clin. Rec.* **104**: 645
Dazert S *see* Geyer G *et al.*
de Bruyn R *see* Tostevin PMJ *et al.*
de Carpentier JP, Flanagan P, Hargreaves SP, Timms MS, An unusual cause of facial pain. *Clin. Rec.* **110**: 796
de Carpentier JP, Flanagan PM, Singh IP, Timms MS, Nassar WV, Nasopharyngeal *Corynebacterium ulcerans*: a different diphtheria. *Clin. Rec.* **106**: 824
de Carpentier JP, Hargreaves S, Zarod AP, A puzzling paediatric parotid haematoma. *Clin. Rec.* **110**: 590
de Carpentier JP, Ramamurthy L, Denning DW, Taylor PH, An algorithmic approach to aspergillus sinusitis. *Orig. Art.* **108**: 314
de Carpentier JP, Ryder WDJ, Saeed SR, Woolford TJ, Survival times of Provox valves. *Orig. Art.* **110**: 37
de Carpentier JP, *see also* Bhandarkar P *et al.*; Green and de Carpentier; Green KMJ *et al.*; Pahade A *et al.*; Yates PD *et al.*
De Diego JI, Bernaldez R, Prim MP, Hardisson D, Polymorphous low-grade adenocarcinoma of the tongue. *Path. Focus* **110**: 700
de Donato G *see* Aslan A *et al.*; Chashaba A *et al.*
De Forni M *see* Bachaud JM *et al.*
de Grip A, Schofield JB, Shotton JC, An unusual cutaneous presentation of Hodgkin's disease. *Clin. Rec.* **113**: 765
de Jong D *see* Ceha HM *et al.*
De la C Mera A, Lopez MJS, Royo EM, Requena L, Premalignant changes in nasal and sinus polyps: a retrospective 10 year study (1979-1988). *Orig. Art.* **104**: 210
de la Cruz M, Bance M, Bilateral sudden sensorineural hearing loss following non-otologic surgery. *Clin. Rec.* **112**: 769
de la Fuente L *see* Marco-Algarra J *et al.*
de la Torre A *see* Regueiro CA *et al.*
de Mora Mieszkowski J *see* Szilvassy J *et al.*
De Paoli A *see* Barzan L *et al.*
De Potter C *see* Ingels K *et al.*
De PR, Mikhail T, A combined approach excision of branchial fistula. *Clin. Rec.* **109**: 999

De S, Pfleiderer AG, An extreme and unusual variant of Ramsay Hunt syndrome. *Clin. Rec.* **113**: 670
De S, *see also* Bahadur S *et al.*
De Santis A *see* Cadoni G *et al.*
De Schepper A *see* de Varebeke SJ *et al.*
de Souza C, Karnad D, de Souza R, Raje A, Mansukhani K, Tilve GH, The stapedial reflex in cephalic tetanus. *Orig. Art.* **108**: 736
de Souza C, Paparella MM, Schachern P, Yoon TH, Pathology of labyrinthine ossification. *Orig. Art.* **105**: 621
de Souza CE, Karnad DR, Tilve GH, Clinical and bacteriological profile of the ear in otogenic tetanus: a case control study. *Orig. Art.* **106**: 1051
de Souza R *see* de Souza C *et al.*
de Varebeke SJ, De Schepper A, Hauben E, Declau F, Marck EV, Van de Heyning PH, Subcutaneous diffuse neurofibroma of the neck: a case report. *Clin. Rec.* **110**: 182
De Vel E *see* Xu Z-M *et al.*
de Villiers JC *see* Wormald PJ *et al.*
de Vries WAEJ *see* Balm AJM *et al.*
Deadman MJ *see* Stevenson DS *et al.*
Deans JAJ, Acute isolated sphenoid sinusitis: a disease with complications. *Clin. Rec.* **105**: 1072
Deans JAJ, Birchall JP, Mendelow AD, Acoustic neuroma and the contralateral ear: recovery of auditory brainstem response abnormalities after surgery. *Clin. Rec.* **104**: 565
Deans JAJ, Hill J, Bennett M, Histological changes in free jejunal grafts used in pharyngeal reconstruction. *Orig. Art.* **105**: 556
Deans JAJ, Hill J, Welch AR, Soames JV, Late development of a squamous carcinoma in a reconstructed pharynx. *Clin. Rec.* **104**: 827
Deans JAJ, *see also* Banfield GK *et al.*; Srinivasan V *et al.*; Watson MG *et al.*
Dearnaley DP *see* **Andaz C** *et al.*
Debelle G *see* Magnay AR *et al.*
Debruyne F, Delaere F, Wouters J, Uwents P, Acoustic analysis of tracheo-oesophageal versus oesophageal speech. *Orig. Art.* **108**: 325
Debruyne F, Ostyn F, Delaere P, Distribution of the solitary adenoma over the parathyroid glands. *Orig. Art.* **111**: 459
Debry C, Renou G, Fingerhut A, Drainage after thyroid surgery: a prospective randomized study. *Orig. Art.* **113**: 49
Declau F *see* de Varebeke SJ *et al.*
DeDonato G *see* Bhatia S *et al.*
Deegan PC, McGlone B, McNicholas WT, Treatment of Robin sequence with nasal CPAP. *Clin. Rec.* **109**: 328
Deger K *see* Temple RH *et al.*
Deggouj N *see* Cao M-Y *et al.*
Deguchi K, Furuta S, Imakiire T, Ohyama M, Case of ageusia from a variety of causes. *Clin. Rec.* **110**: 598
Deguine L, Maillard A, Bonafe A, El Adouli H, Tremoulet M, Fraysse B, Pre-operative and per-operative factors conditioning long-term facial nerve function in vestibular schwannoma surgery through translabyrinthine approach. *Orig. Art.* **112**: 441
Dejima K *see* Hisa Y *et al.*
DeJode ML *see* Dilkes MG *et al.*
Deka RC *see* Tandon DA *et al.*
Dekker PJ, Alternative method of application of topical preparations in otitis externa. *Short Comm.* **105**: 842
Dekker PJ, Andrew AC, Laryngeal chondrosarcoma — an unusual presentation. *Clin. Rec.* **106**: 450
Del Borgo C *see* Del Forno A *et al.*
Del Forno A, Del Borgo C, Turriziani A, Ottaviani F, Antinori A, Fantoni M, Non-Hodgkin's lymphoma of the maxillary sinus in a patient with acquired immunodeficiency syndrome. *Onc. Focus* **112**: 982
Del Valle Zapico A, Rubio Suárez A, Mellado Encinas P, Morales Angula C, Cabrera Pozuelo E, Mucormycosis of the sphenoid sinus in an otherwise healthy patient. *Clin. Rec.* **110**: 471
Delaere P *see* Debruyne F *et al.*; Hermans R *et al.*
Delap T *see* Vijaya-Sekaran S *et al.*
Delap TG, Grant WE, Dick R, Quiney RE, Retropharyngeal abscess - an unusual complication of anorexia. *Clin. Rec.* **110**: 483
Delbrouck C, Chantrain G, Kampouridis S, Petein M, Laryngeal aspergillosis in an AIDS patient. *Clin. Rec.* **112**: 488
Delforge ML *see* Van Vooren JP *et al.*
Delgado H *see* Megighian D *et al.*
Delgado-Rodriguez M *see* Esteban F *et al.*
Deligne P *see* Dominici L *et al.*
Van Dellen J *see* Singh B *et al.*
Demaerel P *see* Buyse GG *et al.*
Demajumdar R, Rajesh PB, "Have we got the full picture?" *Clin. Rec.* **112**: 788
Demirdoven K *see* Guneri A *et al.*
Demirkesen C *see* Tuzuner N *et al.*
Dempster JH, Browning GG, Gatehouse SG, A randomized study of the surgical management of children with persistent otitis media with effusion associated with a hearing impairment. *Orig. Art.* **107**: 284
Denholm S *see* Nilssen ELK *et al.*
Denholm SW, Fielder CP, Submental abscess: an unusual delayed complication of primary Blom–Singer valve insertion *Clin. Rec.* **108**: 1093
Denholm SW, Maynard CA, Watson HG, Warfarin and epistaxis — a case controlled study. *Orig. Art.* **107**: 195
Denholm SW, *see also* Ali Raza S *et al.*; MacDougall and Denholm
Deniz I *see* Guneri A *et al.*
Denning DW *see* de Carpentier JP *et al.*; Swift and Denning
Deo R *see* Koka VN *et al.*
Dereköy S *see* Dündar A *et al.*
Derias NW, Chong WH, Fitzgerald O'Connor AF, Fine needle aspiration cytology of a head and neck swelling in a child: a non-invasive approach to diagnosis. *Path. Focus* **106**: 755
Deshpande A, Bobhate SK, Squamous cell carcinoma in thyroglossal duct cyst. *Clin. Rec.* **109**: 1001
Deshpande AH, Recurrent Bell's palsy in pregnancy. *Clin. Rec.* **104**: 713
Deshpande AR *see* Bhattacharyya AK *et al.*
Deshpande GU *see* Bhatoe and Deshpande
Desousa S *see* Shehab Z *et al.*
Dessi P, Castro F, Triglia JM, Zanaret M, Cannoni M, Major complications of sinus surgery: a review of 1192 procedures. *Orig. Art.* **108**: 212
Dessi P, Moulin G, Triglia JM, Zanaret M, Cannoni M, Difference in the height of the right and left ethmoidal roofs: a possible risk factor for ethmoidal surgery. Prospective study of 150 CT-scans. *Rad. Focus* **108**: 261
Dessi P, *see also* Moulin G *et al.*
Devaiah AK, Hoffman HT, Robinson RA, Carter K, Oral botryomycosis: a case report. *Clin. Rec.* **111**: 77
Devaney KO *see* Ferlito A *et al.*
Devaney SL *see* Ferlito A *et al.*
Devars F *see* Carrat X *et al.*
Devriese PP, Treatment of sequelae after facial paralysis: a global approach. **112**: 429
Dhaliwal J, Rowlands DC, Niedobitek G, Williams A, Das Gupta A, Jones EL, Nasal T-cell lymphoma associated with Epstein–Barr virus infection. *Path. Focus* **107**: 468
Dharan M *see* Rakover Y *et al.*
Dharap AS *see* Sharma HS *et al.*
Dhillon MK *see* Gendah BS *et al.*
Dhillon RS *see* Murthy P *et al.*; Scott PMJ *et al.*
Dhingra J *see* McEwan JA *et al.*
Dhingra JK, Aqel NM, McEwen J, Bleach NR, Multiple oncocytic cysts of the larynx. *Path. Focus* **109**: 1226
Dhong HJ *see* Chung SK *et al.*
Di Girolamo S, Fetoni AR, Di Nardo W, Paludetti G, An unusual complication of cochlear implant: benign paroxysmal positional vertigo. *Clin. Rec.* **113**: 922
Di Loreto C *see* Mannara GM *et al.*
Di Nardo W *see* Di Girolamo S *et al.*
Dicenta-Sousa M *see* Gonzalez-Compta X *et al.*
Dick R *see* Delap TG *et al.*
Dickenson AJ *see* El-Naggar M *et al.*
De Diego JI, Bernaldez R, Prim MP, Hardisson D, Polymorphous low-grade adenocarcinoma of the tongue. *Path. Focus* **110**: 700
Diendoh JV *see* Enion DS *et al.*
Dijkstra MD, Balm AJM, Gregor RT, Hilgers FJM, Loftus BM, Soft tissue sarcomas of the head and neck associated with surgical trauma. *Orig. Art.* **109**: 126
Dikkers FG, Sulter AM, Suspension microlaryngoscopic surgery and indirect microlaryngostroboscopic surgery for benign lesions of the vocal folds. *Orig. Art.* **108**: 1064
Dilkes M, JLO Travelling Fellowship 1994 Report. *Path. Focus* **109**: 1128

Dilkes M, *see also* Hadley J *et al.*; McRae D *et al.*
Dilkes MG, Chapman J, Stafford ND, Per-oral excision of a branchial cyst. *Clin. Rec.* **104**: 143
Dilkes MG, DeJode ML, Gardiner O, Kenyon GS, McKelvie P, Treatment of head and neck cancer with photodynamic therapy: results after one year. *Orig. Art.* **109**: 1072
Dilkes MG, Gautama P, Knowles CH, Chevretton EB, Primary tracheal tuberculosis in an otherwise healthy 65-year-old caucasian woman. *Clin. Rec.* **107**: 1052
Dilkes MG, McGilligan JA, Chapman J, A rare presentation of tuberculosis of the cervical spine. *Clin. Rec.* **105**: 786
Dilkes MG, Morrison GAJ, Orr WP, Rare presentation of a parapharyngeal schwannoma. *Clin. Rec.* **105**: 384
Dilkes MG, *see also* Birchall and Dilkes; Morrison and Dilkes
Dillon MJ *see* Richards A *et al.*
Dingle A *see* Wilson PS *et al.*
Dingle AF, Fistula between the external auditory canal and the temporomandibular joint: a rare complication of otitis externa. *Clin. Rec.* **106**: 994
Dingle AF, Clifford KMA, Flood LM, Retropharyngeal haematoma: a diagnosis for concern? *Clin. Rec.* **107**: 356
Dingle AF, Douglas-Jones AG, Airway obstruction with stridor due to nasal secretions. *Clin. Rec.* **109**: 331
Dingle AF, Flood LM, Implementation of audit in an ENT unit. *Rev. Art.* **105**: 611
Dingle AF, Flood LM, Kumar BU, Hampal S, The mini-grommet and tympanosclerosis: results at two years. *Orig. Art.* **107**: 108
Dingle AF, Flood LM, Udhi Kumar B, Tympanosclerosis and mini grommets: the relevance of grommet design. *Orig. Art.* **109**: 922
Dingsør G *see* Møller and Dingsør
Dini FM *see* Sennaroğlu L *et al.*
Dini M *see* Comin CE *et al.*
Dinnen JS *see* Singh KB *et al.*
Diver JP, Murty GE, Bradley PJ, Cervical cord compression complicating tracheo-oesophageal puncture. *Clin. Rec.* **105**: 1082
Dixon MG, Treacher Collins syndrome: from linkage to prenatal testing. *Mol. Biol.* **112**: 705
Djazaeri B *see* Cumberworth VL *et al.*
Djukić V *see* Petrović Z *et al.*
Dodart L *see* Allias-Montmayeur F *et al.*
Dodds A, Ramsden R, Kingston H, Feingold syndrome — a cause of profound deafness. *Clin. Rec.* **113**: 919
Doğanay M *see* Öncel S *et al.*
Doğusoy G *see* Tuzuner N *et al.*
Doig A *see* Vaughan-Jones RH *et al.*
Dokianakis G *see* Lefantzis D *et al.*
Dokup MK *see* Vele DD *et al.*
Domenge C *see* Salvan D *et al.*
Domínguez L *see* Adiego MI *et al.*
Dominici L, Gondret R, Broc V, Dubois S, Viallard M, Deligne P, Antimicrobial prophylaxis for major head and neck cancer surgery with piperacillin and ornidazole. *Orig. Art.* **106**: 409
Donald PJ, Gadre AK, Neuralgia-like symptoms in a patient with an airgun pellet in the ethmoid sinus: a case report. *Clin. Rec.* **109**: 646
Donaldson I, Snow DG, A five year follow up of incus transposition in relation to the first stage tympanoplasty technique. *Orig. Art.* **106**: 607
Donaldson I, *see also* Drake-Lee A *et al.*; Lall GS *et al.*
Donath K *see* Atula T *et al.*
de Donato G *see* Aslan A *et al.*
Donnadieu S *see* Laccoureye O *et al.*
Donnelly F *see* Haye R *et al.*
Donnelly M *see* Russell JD *et al.*
Donnelly MJ, Al-Sader MH, Blayney AW, Benign nasal schwannoma. *Path. Focus* **106**: 1011
Donnelly MJ, Cass AD, Ryan L, False positive MRI in the diagnosis of small intracanalicular vestibular schwannornas. *Clin. Rec.* **108**: 986
Donnelly MJ, Considine N, McShane DP, Upper airway invasion by well-differentiated thyroid carcinoma. *Clin. Rec.* **107**: 752
Donnelly MJ, Daly CA, Briggs RJS, MR imaging features in an intracochlear acoustic schwannoma. *Rad. Focus* **108**: 1111
Donnelly MJ, Quraishi MS, McShane DP, Indications for paediatric tonsillectomy: GP versus Consultant perspective. *Orig. Art.* **108**: 131
Donnelly MJ, Timon CI, Mooney E, A unique congenital glossocervical fistula. *Clin. Rec.* **108**: 519
Donnelly MJ, *see also* Lacy PD *et al.*
Donnelly MP *see* Lacy PD *et al.*
Dort JC, Wolfensberger M, Felix H, CO_2 laser repair of the facial nerve — an experimental study in the rat. *Orig. Art.* **108**: 466
Dort JC, *see also* Kerr and Dort; Lesser THJ *et al.*; Safneck JR *et al.*
Dossetor R *see* Harkness P *et al.*
Douboyas J *see* Tsakris A *et al.*
Douek EE *see* Rockall TA *et al.*
Doughty JC *see* Espinoza FI *et al.*
Douglas AR, Use of nebulised adrenaline to aid expulsion of intra-nasal foreign bodies in children. *Short Comm.* **110**: 559
Douglas-Jones AG, Rodd C, James EMV, Mills RGS, Prediagnostic malakoplakia presenting as a chronic inflammatory mass in the soft tissues of the neck. *Clin. Rec.* **106**: 173
Douglas-Jones AG, *see also* Backhouse SS *et al.*; Dingle and Douglas-Jones
Douglas-Jones T *see* Mills RG *et al.*; Williams and Douglas-Jones
Doust BD *see* Clifford AR *et al.*
Doweck I *see* Gordon CR *et al.*
Dowell M, Pahor AL, Nasal polypectomy: should antral washout be a routine? *Orig. Art.* **106**: 695
Downes RN *see* Beasley NJP *et al.*; Hehar SS *et al.*
Draf W *see* Keerl R *et al.*; Weber R *et al.*
Drago PC *see* Kuo MJ *et al.*
Drake-Lee A, Nasal polyps in identical twins. *Clin. Rec.* **106**: 1084
Drake-Lee A, Jones V, Lewin I, Nayyar S, Wells A, Stanworth D, Levels of substance P and IgE decapeptide in nasal polyp fluid and matching sera: a preliminary study. *Orig. Art.* **110**: 225
Drake-Lee A, Price J, Mast cell ultrastructure in the inferior turbinate and stroma of nasal polyps. *Orig. Art.* **111**: 340
Drake-Lee A, Price J, Varley R, Mast cell ultrastructure in the adenoids of children with and without secretory otitis media. *Orig. Art.* **108**: 1058
Drake-Lee A, Stevenson M, Donaldson I, Mass in the post nasal space and acquired immune deficiency syndrome. *Clin. Rec.* **110**: 787
Drake-Lee AB, Moriarty B, Smallman LA, Mast cell numbers in the mucosa of the inferior turbinate in patients with perennial allergic rhinitis: a light microscopic study. *Orig. Art.* **105**: 736
Drake-Lee AB, Price J, Ultrastructure of nasal mast cells in normal subjects and patients with perennial allergic rhinitis. *Orig. Art.* **105**: 1006
Drake-Lee AB, *see also* Raj P *et al.*; Slater A *et al.*; Snow DG *et al.*
Draper MR, Sandhu G, Frosh A, Clarke PM, Retropharyngeal haematoma causing acute airway obstruction — first presentation of metastatic carcinoma. *Clin. Rec.* **113**: 258
Dressler L *see* Wong G *et al.*
Drosos AA *see* Kastanioudakis I *et al.*
Drozdziewicz D *see* Stangerup S-E *et al.*
Drysdale AJ, Ansell J, Adeley J, Palato-pharyngo-laryngeal myoclonus: an unusual cause of dysphagia and dysarthria. *Clin. Rec.* **107**: 746
Drysdale AJ, Fawcett WJ, Holloway TE, Moore-Gillon B, Ventilatory monitoring during microlaryngeal surgery using jet insufflation anaesthesia. *Short Comm.* **106**: 42
Drysdale AJ, Moore-Gillon V, External nasal nerve division: a treatment for post-traumatic neuralgia. *Clin. Rec.* **106**: 915
Drysdale AJ, *see also* Lee and Drysdale
Dubey SP, Garep JP, Paediatric tracheostomy: an analysis of 40 cases. *Orig. Art.* **113**: 645
Dubey SP, Murthy DP, Cooke RA, Chaudhuri D, Primary osteogenic sarcoma of the tongue. *Path. Focus* **113**: 376
Dubey SP, *see also* Sengupta A *et al.*; Vele DD *et al.*
Dubois S *see* Dominici L *et al.*
Dubreuil L *see* Klossek JM *et al.*
Duby C *see* Haye R *et al.*
Dudríková K *see* Böör A *et al.*
Dueñas L, Alcantud V, Alvarez F, Arteaga J, Benitez A, Bopuza M, Carniege L, Cartaya B, Comas C, Cotayo R, Escobar H, Fernández H, Fernández M, Garcia M, Iznaga N, Márquez F la O J, Nordet D, Pérez J, Quintero J, Redonavich A, Robeleco M, Rodriquez H, Ruiz P, Seijas R, Villavicencio E, Viera D, Damas F, López-Saura P, Haglund S, Strander H, Use of interferon-alpha in laryngeal papillomatosis: 8 years of the Cuban programme. *Orig. Art.* **111**: 134

Dugar J *see* Hehar SS *et al.*
Duignan MC *see* Lee WC *et al.*
Dulguerov P *see* Quinodoz D *et al.*
Dündar A, Dereköy S, Önder T, Aktą D, Özünlü A, Undifferentiated carcinoma with lymphoid stroma of the parotid gland. *Path. Focus* **107**: 1177
Dündar A, *see also* Özünlü *et al.*
Dunkley P *see* Ram B *et al.*
Dunleavy J *see* Williamson IG *et al.*
Dunsmore IR *see* Heaton JM *et al.*
Dupont C *see* Gumpert L *et al.*
Duque CS *see* Ochoa LF *et al.*
Durak I *see* Canbolat O *et al.*
Dürrigl M-A, Fatović-Ferenčić S, Deafness as self-representation of a 16th century poet. *Hist. Art.* **113**: 795
Durroux R *see* Allias-Montmayeur F *et al.*
Dursun G *see* Acar A *et al.*
Dutt S *see* Raju KGS *et al.*
Dutt SN, East DM, Saleem Y, Jones EL, Spindle-cell variant of intralingual lipoma-report of a case with literature review. *Path. Focus* **113**: 587
Dutt SN, John H, Nayar RC, Nalinesha KM, Prasad D, Surgical management of a case of third branchial pouch fistula. *Clin. Rec.* **108**: 1095
Dutt SN, *see also* Hasan S *et al.*; Ogale SB *et al.*
Dutta TK *see* Murthy DP *et al.*
Dutton JEM, Ramsden RT, Lye RH, Morris K, Keith AO, Page R, Vafidis J, Acoustic neuroma (Schwannoma) surgery 1978-1990. *Orig. Art.* **105**: 165
Dutton JEM, *see also* Hinton AE *et al.*; Neary WJ *et al.*
Duvillard P *see* Klijanienko J *et al.*

East C, Grant H, Jones B, Tracheal reconstruction using a composite microvascular temporoparietal fascia flap and nasal septal graft. *Clin. Rec.* **106**: 741
East CA, Brough MD, Grant HR, Mastoid obliteration with the vascularised temporoparietal fascia flap. *Orig. Art.* **105**: 417
East DM *see* Dutt SN *et al.*
Ebrahim RA *see* Jamal A *et al.*
Eckel HE, Jungehülsing M, Lipoma of the hypopharynx: preoperative diagnosis and transoral resection. *Rad. Focus* **108**: 174
Economou CN *see* Balatsouras DG *et al.*
Economou EN *see* Balatsouras DG *et al.*
Edmonds JL, Woodroof JM, Ator GA, Middle ear lipoma, as a cause of mastoiditis. *Clin. Rec.* **111**: 1162
Edmonds SE *see* McFerran and Edmonds
Edo M *see* Higashi and Edo
Edwards JD *see* Mawman DJ *et al.*
van Eeden S, Lloyd RV, Tranter RM, Comparison of the endoscopic stapling technique with more established procedures for pharyngeal pouches: results and patient satisfaction survey. *Orig. Art.* **113**: 237
Efrat ME *see* Cohen-Kerem R *et al.*
Egelund E, Bak-Pedersen K, Suppurative labyrinthitis caused by anaerobic bacteria. *Clin. Rec.* **108**: 413
Egilmez R *see* Kunt T *et al.*
Egusa K *see* Lai M-T *et al.*
Eherer A *see* Habermann W *et al.*
Eisele D *see* Welsh J *et al.*
Eitan A *see* Hefer T *et al.*
Eizaguirre B *see* Elizalde JM *et al.*
Ejnell H, Järund M, Bailey M, Lindeman P, Airway obstruction in children due to plexiform neurofibroma of the larynx. *Clin. Rec.* **110**: 1065
El Adouli H *see* Deguine L *et al.*
El Azzouni MZ *see* Bhargava D *et al.*
El Chazly M, Rifai M, El Ezz AA, Arytenoidectomy and posterior cordectomy for bilateral abductor paralysis. *Orig. Art.* **105**: 454
El Ezz AA *see* El Chazley M *et al.*
El Jassar P, Moraitis D, Spencer M, Gissons G, A case of intractable epistaxis. *Rad. Focus* **111**: 1192
El-Alami M *see* Hollis LJ *et al.*
El-Bakri OT *see* Azadeh B *et al.*
El-Ebrashy F *see* Abou-Seif SG *et al.*
El-Fakharany AM *see* El-Hakim and El-Fakharany
El-Guindy A, A correlative manometric and endoscopic study of tubal function in dry central perforation of the tympanic membrane. *Orig. Art.* **105**: 716
El-Guindy A, Endoscopic management of posterior nasal obstruction. *Orig. Art.* **106**: 977
El-Guindy A, Endoscopic transcanal myringoplasty. *Orig. Art.* **106**: 493
El-Guindy A, El-Sherief S, Hagrass M, Gamea A, Endoscopic endonasal surgery of posterior choanal atresia. *Short Comm.* **106**: 528
El-Guindy A, Mansour MH, The role of transcanine surgery in antrochoanal polyps. *Orig. Art.* **108**: 1055
El-Guindy A, *see also* Gamea A *et al.*; Khalifa A *et al.*; Moustafa H *et al.*
El-Guindy AS *see* Hagrass MAE *et al.*
El-Hakim H, Nunez DA, Non-Hodgkin's lymphoma of the lacrimal sac and concomitant pansinusitis. *Clin. Rec.* **112**: 969
El-Hakim IE, El-Fakharany AM, The use of the pedicled buccal fat pad (BFP) and palatal rotating flaps in closure of oroantral communication and palatal defects. Orig. Art. **113**: 834
El-Hmd K *see* Collins M *et al.*
El-Husseiny W *see* Zeitoun H *et al.*
El-Jassar P *see* Sekhar P *et al.*
El-Kahky M *see* Salam MA *et al.*
El-Mehiry H *see* Salam MA *et al.*
El-Naggar AK, Batsakis JG, Luna MA, McLemore D, Byers RM, DNA flow cytometry of acinic cell carcinomas of major salivary glands. *Orig. Art.* **104**: 410
El-Naggar AK, Batsakis JG, Ordóñez NG, Luna MA, Goepfert H, Rhabdomyosarcoma of the adult head and neck: a clinicopathological and DNA ploidy study. *Orig. Art.* **107**: 716
El-Naggar AK, Batsakis JG, Vassilopoulou-Sellin R, Ordonez NG, Luna MA, Medullary (thyroid) carcinoma-like carcinoids of the larynx. *Clin. Rec.* **105**: 683
El-Naggar AK, *see also* Carrillo R *et al.*; Cho KJ *et al.*; Kemp BL *et al.*
El-Naggar M, Flood L, A leaking aortic aneurysm presenting as a recurrent neck swelling. *Clin. Rec.* **109**: 163
El-Naggar M, Hawthorne M, Delayed extrusion of a cochlear implant: a case report of an implant extruding 21 months after the original operation. *Clin. Rec.* **109**: 56
El-Naggar M, Hawthorne M, Pallister–Killian syndrome: an unusual presentation. *Clin. Rec.* **108**: 669
El-Naggar M, Kale S, Aldren C, Martin F, Effect of beconase nasal spray on olfactory function in post-nasal polypectomy patients: a prospective controlled trial. *Orig. Art.* **109**: 941
El-Naggar M, Rice B, Oswal V, Life-size photograph transparencies: a method for the photographic detection and documentation of recovery from facial paralysis. *Short Comm.* **109**: 748
El-Naggar M, Welsh A, Dickenson AJ, Flood LM, Gibb JG, Preadmission clinics in ENT: a national audit of UK practice opinion. *Audit Art.* **111**: 358
El-Naggar M, *see also* Hawthorne and El-Naggar; Kale U *et al.*
El-Nagger AK *see* Carrillo R *et al.*
El-Rahman AGA, Cochlear otosclerosis: statistical analysis of relationship of spiral ligament hyalinization to hearing loss. *Orig. Art.* **104**: 952
el-Saggan A, Bang G, Olofsson J, Melanotic neuroectodermal tumor of infancy arising in the maxilla. *Clin. Rec.* **112**: 61
El-Sawi M *see* Zeitoun H *et al.*
El-Sayed Y, Acquired medial canal fibrosis. *Orig. Art.* **112**: 145
El-Sayed Y, Fibromatosis of the head and neck. *Clin. Rec.* **106**: 459
El-Sayed Y, Teratoma of the head and neck. *Clin. Rec.* **106**: 836
El-Sayed Y, Al-Muhaimeid H, Acute visual loss in association with sinusitis. *Clin. Rec.* **107**: 840
El-Sayed Y, Al-Serhani A, Lobular capillary haemangioma (pyogenic granuloma) of the nose. *Orig. Art.* **111**: 941
El-Seifi A, Fouad B, The fibrous annulus in myringoplasty. *Orig. Art.* **106**: 116
El-Sharkawi S, Angiosarcoma of the head and neck. *Clin. Rec.* **111**: 175
El-Sherief S *see* El-Guindy A *et al.*; Moustafa H *et al.*
El-Sherief SG *see* Hagrass MAE *et al.*
El-Siliny O, Inferior turbinate resection: the need for a nasal pack. *Orig. Art.* **107**: 906
El-Siliny O, Corney C, The value of sonography in the management of cystic neck lesions. *Rad. Focus* **107**: 245
El-Siliny O, Harvey L, A clinico-pathological classification of laryngeal paraganglioma. *Clin. Rec.* **106**: 635

El-Simily O, Sharnuby M, Malignant external otitis: management policy. *Orig. Art.* **106**: 5
El-Sioufi I *see* Lallemant JG *et al.*
El-Tatawi FAY *see* Gamea and El-Tatawi; Hagrass MAE *et al.*
El-Zuebi F *see* Jawad and El-Zuebi
Elango S, Jayakumar CR, Nasopharyngeal carcinoma with secondaries at the porta hepatis presenting as obstructive jaundice. *Clin. Rec.* **104**: 41
Elango S, Kareem BA, Chandrasekaran S, Azman N, Nasopharyngeal carcinoma with spinal secondaries. *Clin. Rec.* **105**: 772
Elango S, Sivakumaran S, Parapharyngeal space melioidosis in a diabetic. *Clin. Rec.* **105**: 582
Elbaz P *see* Ayache D *et al.*
Elbrond O, Felding JU, Gustavsen KM, Acoustic rhinometry used as a method to monitor the effect of intramuscular injection of steroid in the treatment of nasal polyps. *Orig. Art.* **105**: 178
Elfenbein IB *see* Klumpp TR *et al.*
Elhan AH *see* Kurtulmaz SY *et al.*
Elias MM, Balm AJM, Peterse JL, Keus RB, Hilgers FJM, Malignant schwannoma of the parapharyngeal space in von Recklinghausen's disease — a case report and review of literature. *Clin. Rec.* **107**: 848
Elidan J *see* Nageris B *et al.*
Eliopoulos PN *see* Balatsouras DG *et al.*; Simaskos N *et al.*
Elizalde JM, Eizaguirre B, Florencio MR, Lopez JI, Frozen section diagnosis in a jugulo-tympanic paraganglioma. *Path. Focus* **107**: 755
Ell SR, *Candida* — the cancer of silastic. *Orig. Art.* **110**: 240
Ell SR, Parker AJ, Limb D, Clegg RT, Osteomyelitis of the cervical spine following laryngectomy. *Clin. Rec.* **106**: 1096
Ell SR, Stell PM, Blood transfusion and survival after laryngectomy for laryngeal carcinoma. *Orig. Art.* **105**: 293
Ell SR, *see also* Santana-Hernandez DJ *et al.*; Sekhar P *et al.*
Elliott C *see* Hill J *et al.*
Ellis GL *see* Williams SB *et al.*
Ellis H *see* Golledge and Ellis
Ellis PDM *see* Lale AM *et al.*
Elsaeid I *see* Elwany S *et al.*
Elston J *see* Koay B *et al.*
Elton PG *see* Ong CC *et al.*
Elwany S, Pathology of the eustachian tube in otitis media: an electron microscopic study. *Path. Focus* **107**: 651
Elwany S, Abdel-Fatah H, Endoscopic control of posterior epistaxis. *Orig. Art.* **110**: 432
Elwany S, Abdel-Moneim MH, Carbon dioxide laser turbinectomy. An electron microscopic study. *Orig. Art.* **111**: 931
Elwany S, Bassiouny M, Topical levocabastine for the treatment of perennial allergic rhinitis. *Orig. Art.* **111**: 935
Elwany S, Elsaeid I, Thabet H, Endoscopic anatomy of the sphenoid sinus. *Orig. Art.* **113**: 122
Elwany S, Harrison R, Inferior turbinectomy: Comparison of four techniques. *Orig. Art.* **104**: 206
Elwany S, Thabet H, Obstruction of the nasal valve. *Orig. Art.* **110**: 221
Emberton P *see* Morgan and Emberton; Morgan NJ *et al.*
Emgård P *see* Lagerholm S *et al.*
Emram B *see* Moulin G *et al.*
Endres D *see* Offiah and Endres
Engelberts I *see* Smeets and Engelberts
England J *see* Nandapalan V *et al.*; Wen QH *et al.*; Wilde AD *et al.*
England RJA, Strachan DR, Buckley JG, Temporalis fascia grafts shrink. *Orig. Art.* **111**: 707
Englender M, Nasal laser mucotomy (L-mucotomy) of the inferior turbinates. *Orig. Art.* **109**: 296
Englender M, Harrell M, Guttman R, Segal S, Typing of *Pseudomonas aeruginosa* ear infections related to outcome of treatment. *Orig. Art.* **104**: 678
Engzell UCG *see* Lau SK *et al.*
Enion DS, Jenkins A, Miles JB, Diendoh JV, Intracranial extension of a naso-ethmoid schwannoma. *Clin. Rec.* **105**: 578
Enjoli M *see* Sugimoto T *et al.*
Ensink RJH, Marres HAM, Brunner HG, Cremers CWRJ, Hearing loss in the Saethre–Chotzen syndrome. *Clin. Rec.* **110**: 952
Erdamar B *see* Süoglu Y *et al.*
Erdoğan N *see* Öncel *et al.*
Erekul S *see* Akiner MN *et al.*
Eren S *see* Murat Karaşen R *et al.*
Eréno C, Lopez JI, Sanchez JM, Atypical carcinoid of the larynx: presentation with scalp metastases. *Path. Focus* **111**: 89
Erfan F *see* Khalifa A *et al.*
Erkal HS *see* Kurtulmaz SY *et al.*
Erkan M, Tolu I, Aslan T, Guney E, Ultrasonography in laryngeal cancers. *Rad. Focus* **107**: 65
Erman Z *see* Altas E *et al.*
Ermete M *see* Öncel S *et al.*
Ernest van Heurn LW, Brink PRG, The history of percutaneous tracheotomy. *Hist. Art.* **110**: 723
Ersoy A *see* Güney E *et al.*
Erwin AC *see* McElveen Jr JT *et al.*; McElvenn JT Jr *et al.*
Eryilmaz K *see* Karaşen RM *et al.*
Escada P, Capucho C, Silva JM, Ruah CB, Vital JP, Penha RS, Cavernous haemangioma of the facial nerve. *Clin. Rec.* **111**: 858
Escobar H *see* Dueñas L *et al.*
Espinoza FI, MacGregor FB, Doughty JC, Cooke LD, Vocal fold paralysis following carotid endarterectomy. *Orig. Art.* **113**: 439
Esrefoğlu M *see* Selimoğlu E *et al.*
Essa A *see* Ali Bafaqeeh S *et al.*; Rajah and Essa
Essa AY *see* Shafshak TS *et al.*
Esteban F, Moreno JA, Delgado-Rodriguez M, Mochon A, Risk factors involved in stomal recurrence following laryngectomy. *Orig. Art.* **107**: 527
Esteban F, Ruiz-Avila I, Vilchez R, Gamero C, Gomez M, Mochon A, Ectopic pituitary adenoma in the sphenoid causing Nelson's syndrome. *Clin. Rec.* **111**: 565
Esteban F, *see also* Solanellas J *et al.*
Esteban R *see* Colmenero C *et al.*
Etkind P *see* Rubin JS *et al.*
Evans DG *see* Neary WJ *et al.*
Evans DGR, Blair V, Strachan T, Lye RH, Ramsden RT, Variation of expression of the gene for type 2 neurofibromatosis: absence of a gender effect on vestibular schwannomas, but confirmation of a preponderance of meningiomas in females. *Orig. Art.* **109**: 830
Evans DGR, Ramsden R, Huson SM, Harris R, Lye R, King TT, Type 2 neurofibromatosis: the need for supraregional care? *Orig. Art.* **107**: 401
Evans J *see* Phelps PD *et al.*
Evans JNG *see* Ford GR *et al.*; Hickey SA *et al.*; Morgan and Evans; Morrison GAJ *et al.*; Papsin and Evans; Tostevin PMJ *et al.*
Evans KL, Keene MH, Bristow ASE, High frequency jet ventilation — a review of its role in laryngology. *Orig. Art.* **108**: 23
Evans KL, Lowe DG, Keene MH, Vallecula angioleiomyoma: unusual cause of acute adult airway obstruction. *Clin. Rec.* **104**: 341
Evans PH, Tracheo-oesophageal puncture without tears: the forceps technique. *Orig. Art.* **105**: 748
Evans R *see* John DG *et al.*
Evans RA *see* Gray RF *et al.*
Eveson JW *see* McFall MR *et al.*; Robson AK *et al.*
Eynon-Lewis N *see* Toma AG *et al.*
El Ezz AA *see* El Chazley M *et al.*

Fabre JW *see* Milton CM *et al.*; Premachandra DJ *et al.*
Fabretti F, Calabrese V, Fornasari V, Poletti I, Subtotal parathyroidectomy for secondary hyperparathyroidism in chronic renal failure. *Orig. Art.* **105**: 562
Fagan JJ, Gallow I, A destructive false aneurysm of the maxillary sinus. *Rad. Focus* **106**: 1103
Fagan JJ, Learmonth GM, Garb M, Bowen RM, Nasopharyngeal lipoma - a rare clinico-pathological entity. *Clin. Rec.* **110**: 275
Fagan JJ, Myers EN, Barnes L, A parapharyngeal myxoid liposarcoma. *Path. Focus* **113**: 179
Fagan JJ, *see also* Hartley BEJ *et al.*
Fagan P *see* Ajal M *et al.*; Talbot A *et al.*
Fagan PA *see* Buchanan DS *et al.*; Clifford AR *et al.*; Coakley DJ *et al.*; Fenton and Fagan; Fenton JE *et al.*; Forrest AW *et al.*; Low WK *et al.*; Shirzai A *et al.*; Sillars and Fagan
Fairley JW, Patrick Watson-Williams and the concept of focal sepsis in the sinuses: An historical caveat for functional endoscopic sinus surgery. *Orig. Art.* **105**: 1
Fairley JW, Cross S, Shaw JD, Glover GW, Bennett MH, Kikuchi's necrotising lymphadenitis. *Path. Focus* **105**: 496

Fairley JW, Hughes M, Acute stridor due to bilateral vocal fold paralysis as a presenting sign of myasthenia gravis. *Clin. Rec.* **106**: 737
Fairley JW, Hunt BJ, Glover GW, Radley-Smith RC, Yacoub MH, Unusual lymphoproliferative oropharyngeal lesions in heart and heart-lung transplant recipients. *Clin. Rec.* **104**: 720
Falcioni M *see* Aslan A *et al.*
Fan YF *see* Chong and Fan; Low WK *et al.*
Fannin T *see* McCluggage WG *et al.*
Fantoni M *see* Del Forno A *et al.*
Farag I *see* Tierney PA *et al.*
Farah P *see* Abboud B *et al.*
Farber CM *see* Van Vooren JP *et al.*
Farneti G *see* Cavicchi O *et al.*; Tesei F *et al.*
Farrell ML, Gray RF, Cricoid release in a preterm neonate. *Clin. Rec.* **104**: 995
Farrell ML, Gray RF, Perforating injury of the neck and vertebral artery trauma. *Clin. Rec.* **106**: 925
Farrell ML, Harries ML, Baguley DM, Moffat DA, Bilateral acoustic schwannoma: post-operative hearing in the contralateral ear. *Clin. Rec.* **105**: 769
Farrell R *see* Motamed M *et al.*
Farrell RWR, McKenna DM, Breen D, Parker AJ, A difficult intubation – fatal respiratory arrest secondary to an oral epulis. *Clin. Rec.* **106**: 444
Farrell RWR, *see also* Owa AO *et al.*; Owa and Farrell
Farrington WT *see* Birzgalis AR *et al.*; Hartley C *et al.*; Lobo CJ *et al.*; Luff DA *et al.*; Martin-Hirsch DP *et al.*; Slevin NJ *et al.*; Woolford TJ *et al.*
Farrugia EJ, Ali Raza S, Penrose Stephen A, Juvenile xanthogranuloma of the temporal bone – a case report. *Clin. Rec.* **111**: 63
Farrugia EJ, Ali Raza S, Phillipps JJ, Tuberculous otitis media. *Clin. Rec.* **111**: 58
Fathi M *see* Gamea A *et al.*
Fatović-Ferenčić S *see* Dürrigl M-A and Fatović-Ferenčić
Favia A *see* Roberto M *et al.*
Fawcett HV *see* Al-Khayat M *et al.*
Fawcett WJ *see* Daya H *et al.*; Drysdale AJ *et al.*
Feakins R *see* Montgomery PQ *et al.*
Feat S *see* Godey B *et al.*
Featherstone T, Epidermoid tumour of the cerebellopontine angle: diagnosis by MRI. *Rad. Focus* **108**: 438
Federspil P *see* Pahl S *et al.*
Fee WE *see* Terris DJ *et al.*
Feghali JD, Kantrowitz AB, Transcranial translabyrinthine approach to vestibular schwannomas. *Orig. Art.* **107**: 111
Feibel M *see* Kaplan HY *et al.*
Feiglin H *see* Podoshin L *et al.*
Feinmesser M, Tell L, Levi H, Decline in the prevalence of childhood deafness in the Jewish population of Jerusalem: Ethnic and genetic aspects. *Orig. Art.* **104**: 675
Feinmesser M, *see also* Feinmesser R *et al.*
Feinmesser R, Feinmesser M, Freeman JL, Noyek AM, Livni N, Detection of occult nasopharyngeal primary tumours by means of *in situ* hybridization. *Orig. Art.* **106**: 345
Feinmesser R, Freeman JL, Noyek A, Flow cytometric analysis of DNA content in laryngeal cancer. *Orig. Art.* **104**: 485
Feinmesser R, *see also* Raveh E *et al.*; Shvero J *et al.*
Fekete-Szabó G *see* Czigner and Fekete-Szabó
Felder CP *see* John and Felder
Felding JU *see* Elbrønd O *et al.*
Felix H *see* Dort JC *et al.*
Fells P *see* Lund VJ *et al.*
Feltoe CK *see* Brockhurst and Feltoe
Feneley MR, Murthy P, Acute bilateral vestibulo-cochlear dysfunction following occipital fracture. *Clin. Rec.*: **108**: 54
Feng Gou X *see* Ming Li X *et al.*
Fenton A *see* Blair RL *et al.*
Fenton CJ *see* Garth RJN *et al.*
Fenton CJV, Coddington R, Ramsay AD, Garth RJN, Primary neuroblastoma of the facial nerve presenting as a recurrent facial paralysis. *Clin. Rec.* **110**: 151
Fenton J *see* Hone SW *et al.*; Smyth DA *et al.*
Fenton JE, Blayney AW, O'Dwyer TP, Bismuth subgallate — its role in tonsillectomy. *Orig. Art.* **109**: 203
Fenton JE, Brake H, Shirazi A, Mendelsohn MS, Atlas MD, Fagan PA, The management of dysphagia in jugular foramen surgery. *Orig. Art.* **110**: 144
Fenton JE, Fagan PA, Meatoplasty in Marfan syndrome. *Clin. Rec.* **110**: 456
Fenton JE, O'Sullivan TJ, The otological manifestations of Wegener's granulomatosis. *Clin. Rec.* **108**: 144
Fenton JE, Stack J, Kelly P, O'Dwyer TP, Lymphoma and Hashimoto's thyroiditis. *Rad. Focus* **109**: 781
Fenton JE, Timon CI, McShane DP, Recurrent laryngeal nerve palsy secondary to benign thyroid disease. *Clin. Rec.* **108**: 878
Fenton JE, Turner J, Shirazi A, Fagan PA, Post-stapedectomy reparative granuloma: a misnomer. *Path. Focus* **110**: 185
Fenton JE, *see also* Lacy PD *et al.*; Low WK *et al.*; Shirzai A *et al.*
Fenton PA *see* Carrie and Fenton
Fenwick JD *see* Sood S *et al.*
Ferekidis E, Tzounakos P, Kandiloros D, Kaberos A, Adamopoulos G, Modifications of the Caldwell-Luc procedure for the prevention of post-operative sensitivity disorders. *Orig. Art.* **110**: 228
Ferekidis E, *see also* Adamopoulos G *et al.*; Kandiloros DC *et al.*; Manolis E *et al.*
Ferekidis EA *see* Kandiloros DC *et al.*
Fergie N, Jones NS, Havlat MF, The nasal manifestations of sarcoidosis: a review and report of eight cases. *Orig. Art.* **113**: 893
Fergie N, Murray A, Kell RA, Peritonsillar haematoma. *Clin. Rec.* **111**: 266
Fergie N, *see also* Rapado F *et al.*
Ferlitio A, A review of the definition, terminology and pathology of aural cholesteatoma. *Rev. Art.* **107**: 483
Ferlito A, Andretta M, Baldan M, Candiani F, Non-occupational recurrent bilateral pneumoparotitis in an adolescent. *Rad. Focus* **106**: 558
Ferlito A, Bertino G, Rinaldo A, Mannarà GM, Devaney KO, A review of heterotopia and associated salivary gland neoplasms of the head and neck. *Rev. Art.* **113**: 299
Ferlito A, Rinaldo A, Level 1 dissection for laryngeal and hypopharyngeal cancer: is it indicated? *Rev. Art.* **112**: 438
Ferlito A, Rinaldo A, Selective lateral neck dissection for laryngeal cancer in the clinically negative neck: is it justified? *Rev. Art.* **112**: 921
Ferlito A, Rinaldo A, Selective lateral neck dissection for laryngeal cancer with limited metastatic disease: is it indicated? *Rev. Art.* **112**: 1031
Ferlito A, Rinaldo A, Devaney KO, Carbone A, Management of the clinically negative cervical lymph nodes in patients with non-conventional squamous carcinoma of the larynx. *Rev. Art.* **113**: 619
Ferlito A, Rinaldo A, Devaney KO, Devaney SL, Milroy CM, Impact of phenotype on treatment and pregnosis of laryngeal malignancies. *Rev. Art.* **112**: 710
Ferlito A, Rinaldo A, Mannarà GM, Is primary radiotherapy an appropriate option for the treatment of verrucous carcinoma of the head and neck? *Rev. Art.* **112**: 132
Ferlito A *see also* Mannara GM *et al.*
Ferluga D *see* Zidar N *et al.*
Fernandes CMC, Bilateral transnasal vidian neurectomy in the management of chronic rhinitis. *Orig. Art.* **108**: 569
Fernández H *see* Dueñas L *et al.*
Fernandez JA *see* Rodrigo JP *et al.*
Fernández M *see* Dueñas L *et al.*
Fernández MR *see* Rubio A *et al.*
Fernandez-Espinosa J *see* Alfaro-Monge JM *et al.*
Ferrario F, Roselli R, Macchi A, Occult thyroid carcinoma presenting as a parapharyngeal mass. *Clin. Rec.* **109**: 1204
Ferreiro J, Stylopoulos N, Oncocytic differentiation in salivary gland tumours. *Path. Focus* **109**: 569
Ferreiro JA, Kochar AS: Parotid acinic cell carcinoma with undifferentiated spindle transformation. *Path. Focus.* **108**: 902
Fetissoff F *see* Benlyazid A *et al.*
Fetoni AR *see* Di Girolamo S *et al.*
Feverman T *see* Wackym PA *et al.*
Feyerabend C *see* Whittet HB *et al.*
Field JK *see* Jones AS *et al.*; Kinsella AR *et al.*
Field S *see* Callanan V *et al.*
Fielder CP *see* Denholm and Fielder
Figols J *see* Rubio A *et al.*

Filipo R, Barbara M, Monini S, Mancini P, Clarion cochlear implants: surgical implications. *Orig. Art.* **113**: 321
Filipo R, *see also* Barbara M *et al.*
Finci R *see* Günhan O *et al.*
Findler G *see* Kronenberg J *et al.*
Fingerhut A *see* Debry C *et al.*
Finkelstein Y, Tairni UP, Raveh E, Orlin J, Rudnicki C, Fried M, Zahavi Y, Can obstructive sleep apnoea be a complication of uvulopalatopharyngoplasty? *Orig. Art.* **109**: 212
Finkelstein Y, *see also* Berger G *et al.*; Talmi YP *et al.*
Finlayson CJ *see* Wyatt ME *et al.*
Finn DG *see* Kieserman and Finn
Fish BM, An unusual case of presumed perilymph fistula. *Clin. Rec.* **111**: 1166
Fisher BEW, Toma A, Fisher PH, Cheesman AD, Rhinocerebral mucormycosis: Use of liposomal amphotericin. *Clin. Rec.* **105**: 575
Fisher C, Flood LM, Ramsay AD, The role of electron microsopy in the diagnosis of tumours of the head and neck. *Orig. Art.* **106**: 403
Fisher C, *see also* Commins DJ *et al.*; Greig AVH *et al.*; Hadfield PJ *et al.*; Hosni A *et al.*; Sarker SK *et al.*; See ACH *et al.*
Fisher EW, Boreham AB, Improving the reproducibility of acoustic rhinometry: a customized stand giving control of height and angle. *Short Comm.* **109**: 536
Fisher EW, Clarke PM, Cheesman AD, Prophylaxis of nasolacrimal duct obstruction after major sinus surgery using a silicone stent. *Short Comm.* **105**: 299
Fisher EW, Howard DJ, Percutaneous tracheostomy in a head and neck unit. *Orig. Art.* **106**: 625
Fisher EW, McManus TC, Surgery for external auditory canal exostoses and osteomata. *Orig. Art.* **108**: 106
Fisher EW, Palmer CR, Lund VJ, Monitoring fluctuations in nasal patency in children: acoustic rhinometry versus rhinohygrometry. *Orig. Art.* **109**: 503
Fisher EW, Richards A, Anderson G, Albert DM, Laryngeal candidiasis: a cause of airway obstruction in the immunocompromised child. *Clin. Rec.* **106**: 168
Fisher EW, *see also* Irving RM *et al.*; Toma AG *et al.*; Toma and Fisher; von Blumenthal H *et al.*; Wareing MJ *et al.*; Williams HOL *et al.*
Fisher PH *see* Fisher EW *et al.*
FitzGerald O'Connor A *see* Hickey and FitzGerald O'Connor
Fitzgerald O'Connor AF *see* Al-Saati A *et al.*; Buckley JG *et al.*; Callanan V *et al.*; Derias NW *et al.*; Hickey SA *et al.*
Flanagan P *see* de Carpentier JP *et al.*; Tomkinson A *et al.*
Flanagan PM, McIlwain JC, Tuberculosis of the larynx in a lepromatous patient. *Clin. Rec.* **107**: 845
Flanagan PM, Roland NJ, Jones AS, Cervical node metastases presenting with features of branchial cysts. *Orig. Art.* **108**: 1068
Flanagan PM, *see also* de Carpentier JP *et al.*
Flax-Goldenberg R *see* Goldenberg D *et al.*
Fleming J *see* Hardisty RE *et al.*
Fletcher CDM *see* Buckley JG *et al.*
Fliss DM *see* Goldenberg D *et al.*; Kraus M *et al.*; Noghreyan A *et al.*; Puterman M *et al.*; Tovi F *et al.*
Flood L *see* El-Naggar M and Flood; Morgan M *et al.*
Flood LM *see* Abou-Elhmd KA *et al.*; Agrawal R *et al.*; Dingle AF *et al.*; Dingle and Flood; El-Naggar M *et al.*; Fisher C *et al.*; Hampal S *et al.*; Kumar BU *et al.*; Nair SB *et al.*; Ravikumar A *et al.*; Robson NLK *et al.*
Florena AM *see* Franco V *et al.*
Florencio MR *see* Elizalde JM *et al.*
Floretti G *see* Poli P *et al.*
Flower N *see* Singh V *et al.*
Flynn JR *see* O'Hanlon DM *et al.*
Flynn MD, Beasley P, Tooke JE, Adrenal suppression with intranasal betamethasone drops. *Clin. Rec.* **106**: 827
Foda HMT, The one-stage rhinoplasty septal perforation repair. *Orig. Art.* **113**: 728
Foglia-Fernandez M *see* Gonzalez-Compta X *et al.*
Fong K-W *see* Leong J-L *et al.*
Fong KW *see* Low and Fong
Fooanant S *see* Kangsanarak J *et al.*
Ford GR, Balakrishnan A, Evans JNG, Bailey CM, Branchial cleft and pouch anomalies. *Orig. Art.* **106**: 137
Ford GR, Courteney-Harris RG, Another hazard of ear syringing. Malignant external otitis. *Clin. Rec.* **104**: 709
Ford GR, Horrocks CL, Hazards of microwave cooking: direct thermal damage to the pharynx and larynx. *Clin. Rec.* **108**: 509
Ford GR, Irving RM, Jones NS, Bailey CM, ENT manifestations of Fraser syndrome. *Orig. Art.* **106**: 1
Ford GR, *see also* Balakrishman A *et al.*; Courteney-Harris RG *et al.*; Cox and Ford; Hickey SA *et al.*; Irving RM *et al.*
Ford MJ *see* Jacob A *et al.*
Fornasari V *see* Fabretti F *et al.*
De Forni M *see* Bachaud JM *et al.*
Forrest AW, Turner JJ, Fagan PA, Aggressive papillary middle ear tumour. *Clin. Rec.* **105**: 950
Forster G *see* Jones AS *et al.*
Foster H *see* Mason J *et al.*
Fouad B *see* El-Seifi and Fouad
Fountzilas G *see* Daniilidis J *et al.*; Nikolaou A *et al.*; Nikolaou AC *et al.*
Fowler JF *see* Alcock GJ *et al.*
Fowler S *see* Brown PM *et al.*; Harkness P *et al.*
Fox GC *see* Gibbin KP *et al.*
Fradis M, Podoshin L, Ben David J, Post-laryngectomy pharyngocutaneous fistula — a still unresolved problem. *Orig. Art.* **109**: 221
Fradis M, *see also* David YB *et al.*; Gaitini L *et al.*; Gaitini LA *et al.*; Gertner R *et al.*; Podoshin L *et al.*
Frampton MC *see* Monem SA *et al.*
Franchi A, Frosini P, Santoro R, Pigmented villonodular synovitis of the temporomandibular joint: report of a case. *Clin. Rec.* **108**: 166
Franchin G *see* Barzan L *et al.*
Francis I *see* Tierney PA *et al.*
Francis TJR *see* Murrison AW *et al.*
Franco V, Florena AM, Lombardo F, Restivo S, Bilateral hairy polyp of the oropharynx. *Path. Focus* **110**: 288
Francois J-M *see* Carrat X *et al.*
Frankel R *see* Samet A *et al.*
Franzmann M-B, Buchwald C, Larsen P, Balle V, Tracheobronchial involvement of laryngeal papillomatosis at onset. *Clin. Rec.* **108**: 164
Fraser I *see* Rowley H *et al.*
Fraser ID *see* Midwinter KI *et al.*
Fraser JG *see* Robinson PJ *et al.*
Frattasio A *see* Mannara GM *et al.*
Frau GN, Luxford WM, Lo WWM, Berliner KI, Telischi FF, High-resolution computed tomography in evaluation of cochlear patency in implant candidates: a comparison with surgical findings. *Orig. Art.* **108**: 743
Fraysse B *see* Deguine L *et al.*
Freche C *see* Koka VN *et al.*
Freedman AR *see* Rowe-Jones JM *et al.*
Freeland AP *see* Koay CB *et al.*; Leighton SEJ *et al.*; Mckiernan DC *et al.*; Shinkin CA *et al.*
Freeman JL *see* Feinmesser R *et al.*
Freemont AJ *see* Herdman RCD *et al.*
Freer CEL *see* Gray RF *et al.*
French PD, Birchall MA, Harris JRW, Cytomegalovirus ulceration of the oropharynx. *Orig. Art.* **105**: 739
Frenguelli A *see* Ruscito P *et al.*
Frenkiel S *see* Bégin and Frenkiel
Freund B, Timon C: Cervical meningocoele presenting as a neck mass in a patient with neurofibromatosis 1. *Clin. Rec.* **106**: 463
Fried M *see* Finkelstein Y *et al.*
Friedman D *see* Little P *et al.*
Friedman J *see* Mesko TW *et al.*
Friedmann I, Frohlich A, Wright A, Epidemic typhus fever and hearing loss: a historical study. *Orig. Art.* **107**: 275
Friedmann I, *see also* Blamires TL *et al.*; Böör A *et al.*; Cumberworth VL *et al.*; Davis JP *et al.*
Friedmann I *see* Russell JD *et al.*
Friedrich G *see* Habermann W *et al.*; Koc C *et al.*
Froehlich P *see* Bailey CM *et al.*
Frohlich A *see* Friedmann I *et al.*
Frosh A, Prions and the ENT surgeon. *Rev. Art.* **113**: 1064
Frosh A *see also* Draper MR *et al.*
Frosh AC *see* Jayaraj SM *et al.*
Frosini P *see* Franchi A *et al.*
Frost RA *see* Singh V *et al.*
Frustaci S *see* Barzan L *et al.*
Fuchs C *see* Luntz M *et al.*; Sadé and Fuchs

de la Fuente L *see* Marco-Algarra J *et al.*
Fujii H, Barnes L, Johnson JT, Kapadia SB, Post radiation primary intranodal leiomyosarcoma. *Path. Focus* **109**: 80
Fujii M *see* Hirakawa K *et al.*
Fujikura T *see* Otsuka H *et al.*
Fujiura H *see* Harada H *et al.*
Fujiwara H *see* Watanabe K *et al.*
Fukaya T *see* Tsunoda and Fukaya
Fukuda H *see* Kawaida M *et al.*
Fukuda I *see* Minatogawa T *et al.*
Fukuda K *see* Itoh K *et al.*
Fulurija A *see* Ashman RB *et al.*
Funk GF *see* Graham SM *et al.*
Furukawa M *see* Ishimaru T *et al.*; Kimura Y *et al.*; Nagayama I *et al.*; Ngayama I *et al.*; Nishimura T *et al.*; Okabe Y *et al.*; Tanaka S *et al.*; Wen QH *et al.*; Yoshizaki T *et al.*
Furukawa S *see* Mochimatsu I *et al.*; Nishimura G *et al.*
Furuta S *see* Deguchi K *et al.*; Itoh K *et al.*
Fuse T, Yoshida S, Sakakibara A, Motoyama T, Angiomyoma of the retropharyngeal space. *Clin. Rec.* **112**: 290

Ga Sze H, John AB, Theobald D, Chee SK, Flexible endoscopic tracheo-oesophageal puncture under local anaesthetic. *Short Comm.* **109**: 1077
Gaafar HA *see* Abou-Seif SG *et al.*
Gad El Hak, NA *see* Abdel-Aziz MF *et al.*
Gadre AK, Gregory DeSautel M, Senders DW, Otolaryngological manifestations of factitious disorders — a case and literature review. *Clin. Rec.* **110**: 981
Gadre AK, *see also* Donald and Gadre
Gadre KC *see* Bhargava KB *et al.*
Gaffney RJ, Harrison M, Blayney AW, Nebulized racemic ephedrine in the treatment of acute exacerbations of laryngeal relapsing polychondritis. *Clin. Rec.* **106**: 63
Gaffney RJ, O'Dwyer TP, Maguire AJ, Bezold's abscess. *Clin. Rec.* **105**: 765
Gaffney RJ, Viani L, McShane DP, B-Mode ultrasound demonstration of non-luminal carotid artery invasion by tumour. *Clin. Rec.* **106**: 73
Gaffney RJ, Walsh MA, Cervicofacial actinomycosis: an unusual cause of submandibular swelling. *Clin. Rec.* **107**: 1169
Gaikwad N *see* Grewal DS *et al.*
Gaitini L, Fradis M, Vaida S, Collins G, Croitoru M, Somri M, Borochovitz Z, Golz A, Failure to control the airway in a patient with Hunter's syndrome. *Clin. Rec.* **112**: 380
Gaitini LA, Vaida SJ, Fradis M, Somri M, Yanovski B, Kalderon N, Replacing the combitube by an endotracheal tube using a fibreoptic bronchoscope during spontaneous ventilation. *Clin. Rec.* **112**: 786
Gal R *see* Talmi YP *et al.*
Gale N *see* Zidar N *et al.*
Galera-Ruiz H, Gomez-Angel D, Vazquez-Ramirez FJ, Sanguino-Fabre JC, Salazar-Fernandez CI, Gonzalez-Hachero J, Fine needle aspiration in the pre-operative diagnosis of melanotic neuroectodermal tumour of infancy. *Path. Focus* **113**: 581
Le Gall F *see* Godey B *et al.*
Galleti di San Cataldo F *see* Stephens D *et al.*
Galli J, Almadori G, Paludetti G, Rosignoli M, Corina L, Leraci A, Plexiform neurofibroma of the cervical portion of the vagus nerve. *Clin. Rec.* **106**: 643
Gallimore A *see* Abdullah V *et al.*; Benson-Mitchell R *et al.*; Daya and Gallimore
Gallimore AP *see* Briggs RJS *et al.*; Harcourt and Gallimore; McFerran DJ *et al.*; Owa AO *et al.*; Spraggs PDR *et al.*
Gallow I *see* Fagan and Gallow; Jones TA *et al.*
Gamea A, Fathi M, El-Guindy A, The use of the rigid endoscope in trans-sphenoidal pituitary surgery. *Orig. Art.* **108**: 19
Gamea A, *see also* El-Guindy A *et al.*
Gamea AM, Role of endoscopy in diagnosing scleroma in its uncommon sites. *Orig. Art.* **104**: 619
Gamea AM, El-Tatawi FAY, Ethmoidal scleroma: endoscopic diagnosis and treatment. *Orig. Art.* **106**: 807
Gamea AM, El-Tatawi FAY, The effect of rifampicin on rhinoscleroma: an electron microscopic study. *Orig. Art.* **104**: 772
Gamea AM, *see also* Hagrass MAE *et al.*
Gameiro dos Santos A *see* Xavier R *et al.*
Gamero C *see* Esteban F *et al.*
Gamoletti R, Sanna M, Zini C, Taibah A-K, Pasanisi E, Vassalli L, Inner ear cholesteatoma and the preservation of cochlear function. *Orig. Art.* **104**: 945
Gamoletti R, *see also* Sanna M *et al.*
Ganesan S, Harar RPS, Dawkins RS, Prior AJ, Invasive laryngeal candidiasis: a cause of stridor in the previously irradiated patient. *Clin. Rec.* **112**: 575
Ganesan S, Harar RPS, Owen RA, Dawkins RS, Prior AJ, Horner's syndrome: a rare presentation of cervical sympathetic chain schwannoma. *Path. Focus* **111**: 493
Ganesan S, *see also* Srinivasan V *et al.*
Gangopadhyay K, Abuzeid MO, Kfoury H, Hydatid cyst of the pterygopalatine-infratemporal fossa. *Clin. Rec.* **110**: 978
Gangopadhyay K, McArthur PD, Larsson SG, Unusual anterior course of the sigmoid sinus: report of a case and review of the literature. *Rad. Focus* **110**: 984
Gangopadhyay K, Mahasin ZZ, Kfoury H, Ashraf Ali M, Inflammatory myofibroblastic tumour of the tonsil. *Path. Focus* **111**: 880
Gangopadhyay K, *see also* Abuzeid M *et al.*; Mahasin ZZ *et al.*; Rayappa CS *et al.*
Ganiwalla TMJ *see* Courteney-Harris RG *et al.*
Gantz BJ *see* Redleaf MI *et al.*
Garap JP *see* Dubey and Garap
Garb M *see* Fagan JJ *et al.*
Garcia A *see* Llorente JL *et al.*
Garcia D *see* Crevier-Buchman L *et al.*; Laccourreye O *et al.*
Garcia F *see* Merino E *et al.*
Garcia M *see* Dueñas L *et al.*; Navarette ML *et al.*
Garcia O *see* Mesko TW *et al.*
Garcia Sarandeses A *see* Yebra Pimental M *et al.*
Garcia-Caballero T *see* López-Amado M *et al.*
Garcia-Polo J *see* Tomás MD *et al.*
Gardiner DS *see* Murray A *et al.*
Gardiner Q, Oluwole M, Tan L,, White PS, An animal model for training in endoscopic nasal and sinus surgery. *Orig. Art.* **110**: 425
Gardiner Q, Tan L, Oluwole M White PS, The 'Darling' elbow rest — an aid to a stable operating position in endoscopic sinus surgery. *Short Comm.* **110**: 360
Gardiner Q, *see also* Benson-Mitchell R *et al.*; Dilkes MG *et al.*; Hadley J *et al.*
Gardner PM, Jentzen JM, Komorowski RA, Harb JM, Asphyxial death caused by laryngeal schwannoma. *Clin. Rec.* **111**: 1171
Gareth-Williams R *see* Mills RG *et al.*
Garg I *see* Nayar RC *et al.*
Garg LN, Yadav SPS, Lal H, Serum leucine aminopeptidase in head and neck cancer. *Orig. Art.* **108**: 660
Garozzo A, Rossi M, Glottic reconstruction by implant of homologous laryngeal cartilages. *Orig. Art.* **107**: 427
Garth RJN, Blast injury of the auditory system: a review of the mechanisms and pathology. *Rev. Art.* **108**: 925
Garth RJN, Squamous liver metastases from a carcinoma arising within a pleomorphic adenoma of the parotid gland. *Clin. Rec.* **104**: 152
Garth RJN, Brightwell AP, A comparison of packing materials used in nasal surgery. *Orig. Art.* **108**: 564
Garth RJN, Coddington R, Brightwell AP, Primary cerebral lymphoma presenting with bilateral cerebellopontine angle lesions. *Clin. Rec.* **107**: 937
Garth RJN, Fenton CJ, Pearson CR, Riden K, Thomas MR, The tracheostomal washer: a simple aid for tracheo-oesophageal speakers with a large tracheostome. *Short Comm.* **107**: 824
Garth RJN, McRae A, Rhŷs Evans PH, Tracheo-oesophageal puncture: a review of problems and complications. *Orig. Art.* **105**: 750
Garth RJN, *see also* **Andaz C** *et al.*; Fenton CJV *et al.*; Ingelaere PPC *et al.*; Pearson CR *et al.*; Thomas MR *et al.*
Gatehouse SG *see* Dempster JH *et al.*; Giles M *et al.*
Gatei D *see* Bjerregaard B *et al.*
Gatland D *see* Benson-Mitchell R *et al.*; Kalan A *et al.*
Gatland DJ *see* Laskiewicz B *et al.*; Murrant and Gatland
Gatot A *see* Bar-Lavie Y *et al.*; Goldenberg D *et al.*; Noghreyan A *et al.*; Tovi F *et al.*
Gattamaneni HR *see* Ramamurthy L *et al.*
Gautama P *see* Dilkes MG *et al.*
Gavilán C *see* Tomás MD *et al.*
Gavilán J *see* Bernáldez R *et al.*; Moñuz A *et al.*

Gaze MN *see* Hill DS *et al.*; Shadaba A *et al.*
Gbolade BA, Recurrent lower motor neurone facial paralysis in four successful pregnancies. *Clin. Rec.* **108**: 587
Gebbers J-O *see* Vavrina J *et al.*
Geist RY *see* Nichols C *et al.*
Gendah BS, Dhillon MK, Hamzah M, Bilateral internal jugular vein ectasia: a report of 2 cases. *Clin. Rec.* **108**: 256
Gendeh BS, Gibb AG, Khalid BAK, How I do it: an improved temporal bone holder. *Short Comm.* **109**: 644
Gendeh BS, Said H, Gibb AG, Aziz NS, Kong N, Zahir ZM, Gentamicin ototoxicity in continuous ambulatory peritoneal dialysis. *Orig. Art.* **107**: 681
Gendeh BS, Said H, Gibb AG, Aziz NS, Zahir ZM: Gentamicin administration via peritoneal dialysis fluid: the risk of ototoxicity. *Orig. Art.* **105**: 999
George MK, Mansour P, Pahor AL, Terminal parotid duct carcinoma. *Clin. Rec.* **105**: 780
George MK, O'Connell JE, Batch AJ, Paradoxical vocal cord motion: an unusual cause of stridor. *Clin. Rec.* **105**: 312
George MK, *see also* Mansour P *et al.*; O'Connell JE *et al.*
Gersdorff M *see* Cao M-Y *et al.*
Gerstoft J *see* Petersen BL *et al.*
Gertner R, Barlel E, Fradis M, Podoshin L, Unusual complication of an ingested foreign body. *Clin. Rec.* **105**: 146
Gertner R, *see also* Podoshin L *et al.*
Geyer G, Baier G, Helms J, Epidural application of ionomeric cement implants. Experimental and clinical results. *Orig. Art.* **112**: 344
Geyer G, Dazert S, Helmes J, Performance of ionomeric cement in the reconstruction of the posterior meatal wall after curative middle ear surgery. *Orig. Art.* **111**: 1130
Geyer G, *see also* Helms and Geyer
Ghanaam B *see* Al-Hady MR *et al.*
Ghareeb MA *see* Abu Shara KA *et al.*
Gherardi G, Marveggio C, Cola C, Redaelli G, Decisive role of immunocytochemistry in aspiration cytology of chordoma of the clivus: a case report with review of the literature. *Clin. Rec.* **108**: 426
Ghiacy S *see* Lim JC *et al.*; Vowles RH *et al.*
Ghosh BB *see* Chatterjee D *et al.*
Ghosh S *see* Anwar R *et al.*
Ghosh TB *see* Chatterjee D *et al.*
Ghufoor K, Almeyda J, Mochloulis G, Montgomery PQ, Tolley NS, Infectious pseudomonas subglottic stenosis occurring in a patient with acquired immunodeficiency syndrome. *Clin. Rec.* **111**: 70
Ghufoor K, *see also* Gonzalez-Garcia J *et al.*; Patel SK *et al.*; Sarker SK *et al.*
Gianoli GJ, Miller RH, Crohn's disease of the larynx. *Clin. Rec.* **108**: 596
Gibb AG, Tan KK, Sim RST, The Singapore swing. *Orig. Art.* **111**: 5274
Gibb AG, *see also* Gendeh BS *et al.*
Gibb JG *see* El-Naggar M *et al.*
Gibbin K *see* Mason J *et al.*
Gibbin KP, Evidence based medicine in Otolaryngology. *Edit. Rev.* **111**: 415
Gibbin KP, Fox GC, Smelt GJC, Hong Kong and back 1991 **106**: 1105
Gibbin KP, *see also* Bateman ND *et al.*; Bath AP *et al.*; Hughes RGM *et al.*; Lim PVH *et al.*; Mason JDT *et al.*; Murty GE *et al.*; Shinkwin CA *et al.*; Shinkwin and Gibbin
Gibson AR, McCombe AW, Psychological morbidity following laryngectomy: a pilot study. *Orig. Art.* **113**: 349
Gibson WP *see* O'Leary and Gibson
Gibson WPR, The effect of surgical removal of the extraosseous portion of the endolymphatic sac in patients suffering from Ménière's disease. *Orig. Art.* **110**: 1008
Gibson WPR, Harrison HC, Further experience with a straight, vertical incision for placement of cochlear implants. *Orig. Art.* **111**: 924
Gibson WPR, Harrison HC, Prowse C, A new incision for placement of cochlear implants. *Orig. Art.* **109**: 821
Gibson WPR, *see also* Birman and Gibson; Harrison HC *et al.*; Low WK *et al.*; Mitchell and Gibson
Gilbert LM *see* Catalfumo FJ *et al.*; Golz A *et al.*
Gilbody JS, Errors of deglutition – real and imagined. *Rev. Art.* **105**: 807
Giles E *see* Ramsden R *et al.*; Ramsden RT *et al.*
Giles EC *see* Mawman DJ *et al.*
Giles M, Asher I, Prevalence and natural history of otitis media with perforation in Maori school children. *Orig. Art.* **105**: 257
Giles M, Browning GG, Gatehouse SG, Problems in assessing the audiogram in patients with severe hearing imnpairment. *Orig. Art.* **110**: 727
Gilhooly M *see* Reddy KTV *et al.*
Gill HS *see* Bhatoe HS *et al.*
Gill KS *see* Midwinter KI *et al.*
Gillespie JE *see* Herdman RCD *et al.*; O'Keeffe LJ *et al.*
Gillmore K *see* Callanan V *et al.*
Gimenez F, Marco-Algarra J, The prognostic value of mucociliary clearance in predicting success in tympanoplasty. *Orig. Art.* **107**: 895
Gimenez F, *see also* Marco-Algarra J *et al.*
Girgis B *see* Sood S *et al.*
Girling AC *see* Mitchell and Girling
Gissons G *see* El Jassar P *et al.*
Giusano B *see* Moulin G *et al.*
Glaholm J *see* Brooks JP *et al.*
Glaser M *see* Russell JD *et al.*
Glassford N *see* Ruske DR *et al.*
Gleeson MJ *see* McGlashan JA *et al.*; Pracy JPM *et al.*; Walsh RM *et al.*
Glover GW *see* Cumberworth VL *et al.*; Curtin JJ *et al.*; Fairley JW *et al.*; Hadfield PJ *et al.*; Russell JD *et al.*
Gluckman P *see* Davis JP *et al.*; Tariq M *et al.*
Gluckman PGC, Chu TWF, van Hasselt CA, Neonatal vallecular cysts and failure to thrive. *Clin. Rec.* **106**: 448
Gluckman PGC, *see also* Choy ATK *et al.*; Woo JKS *et al.*
Gnanamuthu C *see* Job A *et al.*
Gober AE *see* Brook and Gober
Gobitti C *see* Barzan L *et al.*
Godballe C *see* Sørensen JA *et al.*
Goddard MJ *see* Courtenay-Harris and Goddard; Lau DPC *et al.*; White and Goddard
Godey B, Morandi X, Le Gall F, Feat S, Brassier G, Le Cleche G, Pituitary adenomas with infra-sellar extension into the nasopharynx. *Clin. Rec.* **113**: 1109
Goel S, Moorjani V, Kulkarni P, Patange V, Sharma OP, Plasmacytoma of the hyoid. *Clin. Rec.* **108**: 604
Goepfert H *see* El-Naggar AK *et al.*
Goh CHK *see* Chong VFH *et al.*
Goh E-K *see* Roh H-J *et al.*
Goh YH, Sethi DS, Submandibular gland excision: a five-year review. *Orig. Art.* **112**: 269
Goh YH, Tan NG, Penetrating oesophageal foreign bodies in the thyroid gland. *Clin. Rec.* **113**: 769
Goh YH, *see also* Low and Goh
Golan-Porat N, Lipitz S, Porat M, Achiron R, Prenatal sonographic diagnosis of upper airway obstruction: a challenge that can be achieved. *Clin. Rec.* **110**: 583
Goldberg G *see* Rubin JS *et al.*
Goldberg S *see* Lanza J *et al.*
Goldenberg D, Gatot A, Barki Y, Leiberman A, Fliss DM, Computerized tomographic and ultrasonographic features of Kimura's disease. *Rad. Focus* **111**: 389
Goldenberg D, Golz A, Flax-Goldenberg R, Joachims HZ, Severe laryngeal injury caused by blunt trauma to neck. *Clin. Rec.* **111**: 1174
Goldenberg D, Golz A, Joachims HZ, Retropharyngeal abscess: a clinical review. *Orig. Art.* **111**: 546
Goldenberg D, Karam M, Danino J, Flax-Goldenberg R, Joachims HZ, Temporal bone fracture following blunt trauma caused by flying fish. *Clin. Rec.* **112**: 959
Goldenberg D, *see also* Catalfumo FJ *et al.*
Golding S *see* Leighton SEJ *et al.*
Golding-Wood DG, Temporal bone dissection for display. *Rev. Art.* **108**: 3
Golding-Wood DG, Holmstrom M, Darby Y, Scadding GK, Lund VJ, The treatment of hyposmia with intranasal steroids. *Orig. Art.* **110**: 132
Golding-Wood DG, Williams HOL, Brookes GB, Tegmental dehiscence and brain herniation into the middle ear cleft. *Clin. Rec.* **105**: 477
Golding-Wood DG, *see also* Croft and Golding-Wood; Williams HOL *et al.*

Goldsmith P, Soames JV, Meikie D, Leiomyomatous hamartoma of the posterior tongue: a case report. *Clin. Rec.* **109**: 1190
Goldsmith P, Zammit-Maempel I, Meikle D, Ramsay Hunt syndrome mimicking acoustic neuroma on MRI. *Rad. Focus* **109**: 1013
Goldstein Y *see* David YB *et al.*
Goligher JE, Lloyd GAS, Fractures of the petrous temporal bone. *Path. Focus* **104**: 438
Golledge J, Ellis H, The aetiology of lateral cervical (branchial) cysts: past and present theories. *Orig. Art.* **108**: 653
Golledge J, *see also* Moffatt DA *et al.*
Golz A, Thomas Westerman S, Gilbert LM, Joachims HZ, Netzer A, Effect of middle ear effusion on the vestibular labyrinth. *Orig. Art.* **105**: 987
Golz A, *see also* Catalfumo FJ *et al.*; Gaitini L *et al.*; Goldenberg D *et al.*; Hefer T *et al.*
Gòmez Estancoma N, Tena AG, Torca J, Urruticoechea L, Muñiz L, Aristimuño D, Unanue JM, Torca J, Urruticoechea A, Solar recharging system for hearing aid cells. *Short Comm.* **108**: 768
Gómez J, *see* Rodrigo JP *et al.*
Gomez M *see* Esteban F *et al.*
Gomez-Angel D *see* Galera-Ruiz H *et al.*
Gondret R *see* Dominici L *et al.*
Gonzalez-Campora R, Rodriquez JLV, Ramirez FV, Cano SD, Ruiz HG, Glomus tumour of the oropharynx. *Clin. Rec.* **109**: 63
Gonzalez-Compta X, Mañós-Pujol M, Foglia-Fernandez M, Peral E, Condom E, Claveguera T, Dicenta-Sousa M, Oncogenic osteomalacia: case report and review of head and neck associated tumours. *Clin. Rec.* **112**: 389
Gonzalez-Garcia J, Ghufoor K, Sandhu G, Thorpe PA, Hadley J, Primary extramedullary plasmacytoma of the parotid gland: a case report and review of the literature. *Clin. Rec.* **112**: 179
Gonzalez-Hachero J *see* Galera-Ruiz H *et al.*
Good CD, Phelps PD, Lim DP, Case report: greatly enlarged jugular fossa with progressive sensorineural hearing loss. *Rad. Focus* **109**: 353
Goode RL *see* Williams Z *et al.*
Goodwin A *see* Ingrams D *et al.*
Gopalakrishna R *see* Puranik KR *et al.*
Gordon CR, Shupak A, Spitzer O, Doweck I,, Melamed Y, Nonspecific vertigo with normal otoneurological examination. The role of vestibular laboratory tests. *Orig. Art.* **110**: 1133
Gordon MT, Pearson L, Paton F, Montgomery R, Predictive assessment of vocal efficiency (PAVE). *Orig. Art.* **111**: 129
Gordts F, Abu Nasser I, Pierard D, Meyvisch P, Clement PAR, Microbiology of the middle meatus in children requiring adenotonsillectomy. *Orig. Art.* **113**: 24
Gormley PK *see* Adams DA *et al.*; Callanan V *et al.*; Callanan VP *et al.*; Hone SW *et al.*
Gortan D *see* Handžić-Ćuk J *et al.*
Goshen S, Ophir D, Cystic hygroma of the parotid gland. *Rad. Focus* **107**: 855
Goto H *see* Kasuga Y *et al.*
Götte K *see* Bergler W *et al.*
Gou-Tsu K *see* Tsunoda A *et al.*
Gould G, A history of the Royal National Throat, Nose and Ear Hospital 1874–1982, Suppl. 22, Vol. 112
Gould S *see* Mckiernan DC *et al.*
Gouliamos A *see* Vlahos L *et al.*
Gouliamos AD *see* Athanassopoulou AC *et al.*
Goumas P, Kokkinis K, Petrocheilos J, Naxakis S, Mochloulis G, Cricothyroidotomy and the anatomy of the cricothyroid space: an autopsy study. *Orig. Art.* **111**: 354
Goumas PD, Naxakis SS, Rentzis GA, Tsiotos PD, Papadas TA, Lateral neck abscess caused by *Streptococcus bovis* in a patient with undiagnosed colon cancer. *Clin. Rec.* **111**: 666
Gov-Ari E *see* Hefer T *et al.*
Govaerts P *see* Somers T *et al.*
Goyal A, Nagarkar NM, Uppal KS, Mohan H, Dass A, Tuberculosis of the pyriform fossa: a rare entity. *Clin. Rec.* **112**: 782
Göze F *see* Almaç A *et al.*
Graamans K, Pirsig W, Biefel K, The shift in the indications for the tracheotomy between 1940 and 1955: an historical review. *Hist. Art.* **113**: 624
Grace ARG *see* Strachan DR *et al.*
Grace ARH, Pfleiderer AG, Dysequilibrium and otitis media with effusion. *Orig. Art.* **104**: 682
Grace ARH, *see also* Hussain SSM *et al.*
Graham CT, Roberts AHN, Padel AF, Pleomorphic lipoma of the parotid gland. *Path. Foc.* **112**: 202
Graham J, Lynch C, Weber B, Stollwerck L, Wei J, Brookes G, The magnetless Clarion cochlear implant in a patient with neurofibromatosis 2. *Clin. Rec.* **113**: 458
Graham J, *see also* Ingrams D *et al.*
Graham JM, Formal reintubation for incipient neonatal subglottic stenosis. *Orig. Art.* **108**: 474
Graham JM, *see also* Irving and Graham; Shadaba and Graham
Graham SM, Hoffman HT, McCulloch TM, Funk GF, Intra-operative ultrasound-guided drainage of parotid abscess. *Rad. Focus* **112**: 1098
Graham SM, Launspach JL, Welsh MJ, Zabner J, Sequential magnetic resonance imaging analysis of the maxillary sinuses: implications for a model of gene therapy in cystic fibrosis. *Orig. Art.* **113**: 329
Granström G *see* Heo SJ *et al.*; Tjellström and Granström
Grant A, Spraggs PDR, Grant HR, Bryceson ADM, Laryngeal leishmaniasis. *Clin. Rec.* **108**: 1086
Grant DG, Hussain A, Burgel R, Frontal sinolith. *Clin. Rec.* **112**: 570
Grant DG, Hussain A, Hurman D, Pre-treatment anaemia alters outcome in early squamous cell carcinoma of the larynx treated by radical radiotherapy. *Orig. Art.* **113**: 829
Grant H *see* East C *et al.*; Harkness P *et al.*; Macnamara M *et al.*
Grant HR *see* East CA *et al.*; Grant A *et al.*; Hill DS *et al.*; McFerran DJ *et al.*; Mochloulis G *et al.*; Robinson PJ *et al.*; Shadaba A *et al.*; Spraggs PDR *et al.*
Grant WE, Grant WJ, Stapedius tendon ossification: a rare cause of congenital conductive deafness.*Clin. Rec.* **105**: 763
Grant WE, Hopper C, Speight PM, Macrobert AJ, Bown SG, Photodynamic therapy of malignant and premalignant lesions in patients with 'field cancerization' of the oral cavity. *Orig. Art.* **107**: 1140
Grant WE, *see also* Alusi GH *et al.*; Delap TG *et al.*; Molony NC *et al.*
Grant WJ *see* Grant and Grant
Gray P, An unusual case of traumatic haematoma of soft palate. *Clin. Rec.* **105**: 1116
Gray RF, Baguley DM, Harries MLI, Court I, Lynch C, Profound deafness treated by the Ineraid multichannel intracochlear implant. *Orig. Art.* **107**: 673
Gray RF, Evans RA, Freer CEL, Szutowicz HE, Maskell DG, Radiology for cochlear implants. *Orig. Art.* **105**: 85
Gray RF, Ray J, Baguley DM, Vanat Z, Begg J, Phelps PD, Cochlear implant failure due to unexpected absence of the eighth nerve: a cautionary tale. *Clin. Rec.* **112**: 646
Gray RF, Ray J, McFerran DJ, Further experience with fat graft obliteration of mastoid cavities for cochlear implants. *Orig. Art.* **113**: 881
Gray RF, *see also* Farrell and Gray; Quine SM *et al.*; Ray J *et al.*; Wareing and Gray; Wareing MJ *et al.*
Gredmark T *see* Paulsson B *et al.*
Green B *see* Panarese A *et al.*
Green JA *see* Siodlak MA *et al.*
Green KMJ, Board T, Mason JDT, Alar haematoma. *Clin. Rec.* **113**: 1104
Green KMJ, de Carpentier JP, Are pre-operative vocal fold checks necessary? *Orig. Art.* **113**: 642
Green KMJ, de Carpentier JP, Curley JWA, An unusual complication of T-tubes. *Clin. Rec.* **111**: 282
Green KMJ, Lappin DWP, Curley JWA, de Carpentier JP, Systemic absorption of gentamicin ear drops. *Clin. Rec.* **111**: 960
Green KMJ, Pantelides E, de Carpentier JP, Tonsillar metastasis from a renal cell carcinoma presenting as a quinsy. *Clin. Rec.* **111**: 379
Green KMJ, *see also* Bhandarkar P *et al.*; Pahade A *et al.*
Green NK, McNeish IA, Principles of gene therapy: prospects for the treatment of head and neck cancer. *Mol. Biol.* **112**: 913
Greenberg E *see* Cohen-Kerem R *et al.*
Greenberg MP *see* Jones E *et al.*
Greenhalgh RM *see* Journeaux SF *et al.*
Gregor RT, Loftus-Coll B, Myxoma of the paranasal sinuses. *Clin. Rec.* **108**: 679
Gregor RT, Ninnin D, Rosai–Dorfman disease of the paranasal sinuses. *Clin. Rec.* **108**: 152

Gregor RT, *see also* Dijkstra MD *et al.*; Knappe and Gregor; Leemans CR *et al.*; van der Laan BFAM *et al.*
Gregory DeSautel M *see* Gadre AK *et al.*
Greig AVH, Papesch ME, Rowsell AR, Parental perceptions of grommet insertion in children with cleft palate. *Orig. Art.* **113**: 1068
Greig AVH, Spraggs PDR, Mannion E, Rhys-Evans PH, Fisher C, Solitary fibrous tumour of the deep soft tissues of the neck. *Path. Focus* **112**: 503
Grénman R *see* Atula T *et al.*
Grenman R *see* Joensuu H *et al.*
Grewal DS, Bhargava P, Mistry B, Gaikwad N, Tuberculoma of the mastoid. *Clin. Rec.* **109**: 232
Grewal DS, *see also* Baser B *et al.*; Hathiram BT *et al.*
Grey P, The clinical significance of the communicating branches of the somatic sensory supply of the middle and external ear. *Rev. Art.* **109**: 1141
Grey PL *see* Baguley DM *et al.*
Griffith G *see* Neary WJ *et al.*
Griffith H *see* Cuddihy PJ *et al.*
Griffith IP *see* Shone and Griffith; Stoney PJ *et al.*
Griffiths MV *see* Jardine AH *et al.*
Griffiths TD *see* Ravikumar A *et al.*
Grigg RG *see* Reynolds JM *et al.*
Grime PD, Giant enterocystoma within an infant's tongue.*Clin. Rec.* **104**: 814
de Grip A, Schofield JB, Shotton JC, An unusual cutaneous presentation of Hodgkin's disease. *Clin. Rec.* **113**: 765
Grocutt M *see* Wilson PS *et al.*
Groisman GM *see* Hefer T *et al.*
Grossenbacher R *see* Sutter and Grossenbacher
Grotenhuis JA *see* van Leeuwen JPPM *et al.*
Grymer LF, Illum P, Hilberg O, Septoplasty and compensatory inferior turbinate hypertrophy: a randomized study evaluated by acoustic rhinometry. *Orig. Art.* **107**: 413
Guan X-L *see* Wang D-H *et al.*
Guatimosin MH *see* Bento RF *et al.*
Gudwani S *see* Chaudhary N *et al.*
Guedea F, Vega M, Canals E, Montserrat JM, Valdano J, Role of radiation therapy for "juvenile" angiofibroma. *Clin. Rec.* **104**: 725
Guedon C *see* Marmuse JP *et al.*
Guffin TN *see* Singh B *et al.*
Gulisano M, Polli G, Dallai S, Altavilla E, Pacini P, Scanning electron microscopic study of nasopharyngeal carcinoma. *Orig. Art.* **105**: 349
Gullane P *see* Timon CVI *et al.*
Gumpert L, Kalach N, Dupont C, Contencin P, Hoarseness and gastroesophageal reflux in children. *Orig. Art.* **112**: 49
Günbay MU *see* Güneri A *et al.*; Sütay S *et al.*
Günbay U *see* Güneri A *et al.*
Gundogdu C *see* Karasen RM *et al.*; Murat Karasen R *et al.*
Güneri A, Ceryan K, Igci E, Kovanlikaya A, Lingual thyroid: The diagnostic value of magnetic resonance imaging. *Rad. Focus* **105**: 493
Güneri A, Günbay MU, Güneri EA, Ceryan K, Sütay S, Management of parapharyngeal space cysts. *Clin. Rec.* **108**: 795
Güneri A, Günbay U, Deniz I, Demirdoven K, Cutaneous sebaceous gland carcinoma in the postauricular region. *Clin. Rec.* **105**: 954
Güneri EA, Ikiz AO, Atabey N, Izci O, Sütay S, Polymerase chain reaction in the diagnosis of parotid gland tuberculosis. *Clin. Rec.* **112**: 494
Güneri EA, *see also* Güneri A *et al.*; Sütay S *et al.*
Güneş M *see* Şekercioğlu N *et al.*
Güney E, Yiğitbaşi OG, Canöz K, Öztürk M, Ersoy A, Functional neck dissection: cure and functional results. *Orig. Art.* **112**: 1176
Güney E, *see also* Erkan M *et al.*
Günhan Ö, Yildiz FR, Celasun B, Önder T, Finci R, Solitary fibrous tumour arising from sublingual gland: report of a case. *Clin. Rec.* **108**: 998
Günhan Ö, *see also* Özünlü A *et al.*
Guo Y, Wu Y, Chen W, Lin J, Endotoxic damage to the stria vascularis: the pathogenesis of sensorineural hearing loss secondary to otitis media? *Orig. Art.* **108**: 310
Gupta A, Shinde KJ, Bhardwaj I, Primary lingual tuberculosis: a case report. *Clin. Rec.* **112**: 86
Gupta AC, Murthy DP, Pulotu ML, Unusual type of foreign body in the maxillary sinus. *Clin. Rec.* **104**: 718
Gupta AC, *see also* Murthy DP *et al.*
Gupta AK, Gupta PC, Abrol R, Mann SBS, Pseudoaneurysm of subclavian artery — atypical presentation. *Clin. Rec.* **112**: 1095
Gupta AK, Mann SBS, Nagarkar N, Surgical management of bilateral immobile vocal folds and long-term follow-up. *Clin. Rec.* **111**: 474
Gupta AK, Mann SBS, Singh KB, Joshi K, Sajeeda S, Kakkar N, Laryngeal malakoplakia. *Clin. Rec.* **111**: 978
Gupta AK, Nagarkar NM, Mann SBS, Gupta SK, Bilateral otogenic temporal lobe and post-aural abscesses. *Clin. Rec.* **111**: 284
Gupta AK, Singhal SK, Mann SBS, Bapuraj JR, Saran AK, Pleomorphic adenoma as a base of tongue mass. *Clin. Rec.* **111**: 1177
Gupta NK *see* Slevin NJ *et al.*
Gupta PC *see* Gupta AK *et al.*
Gupta S *see* Bhargava SK *et al.*
Gupta SC, Ahluwalia H, Fractured tracheostomy tube: an overlooked foreign body. *Clin. Rec.* **110**: 1069
Gupta SC, *see also* Ahluwalia H *et al.*
Gupta SK *see* Gupta AK *et al.*
Gupta Y *see* Maru YK *et al.*
Guragain R *see* Little P *et al.*
Gurr P, Callanan V, Baldwin D, Laser-Doppler blood flowmetry measurement of nasal mucosa blood flow after injection of the greater palatine canal. *Orig. Art.* **110**: 124
Gurr P, *see also* Callanan V *et al.*
Gursel B *see* Sennaroğlu L *et al.*
Gúrzumar A *see* Akin I *et al.*
Gustavesen KM *see* Elbrønd O *et al.*
Guttman R *see* Englender M *et al.*
Gyo K, Honda N, Delayed facial palsy after middle-ear surgery due to reactivation of varicella-zoster virus. *Clin. Rec.* **113**: 914
Gyo K, Sasaki Y, Solubilization of keratin debris in conservative treatment of middle ear cholesteatoma: an in vitro study. *Orig. Art.* **108**: 13
Gyo K, Sasaki Y, Hinohira Y, Configuration of experimentally produced cholesteatoma by transplantation of a free skin graft. *Orig. Art.* **110**: 629

Haapaniemi JJ, Adenoids in school-aged children. *Orig. Art.* **109**: 196
Habashi S, Benign thyroid adenoma causing recurrent laryngeal nerve palsy in a child. *Clin. Rec.* **105**: 141
Habashi S, Croft CB, Intracordal Teflon injection: a question of timing. *Clin. Rec.* **105**: 128
Habashi S, *see also* Martin-Hirsch DP *et al.*
Habashi SMZ *see* Pace-Balzan A *et al.*
Habermann W, Anderhuber W, Humer-Fuchs U, Stammberger H, Simultaneous occurrence of metastatic tonsillar squamous cell carcinoma and angioimmunoblastic T-cell lymphoma in a cervical lymph node. *Clin. Rec.* **111**: 580
Habermann W, Eherer A, Lindbichler F, Raith J, Friedrich G, Ex juvantibus approach for chronic posterior laryngitis: results of short-term pantoprazole therapy. *Orig. Art.* **113**: 734
Habib F *see* Neal AJ *et al.*
Hacking J *see* Harries M *et al.*
Hadar H *see* Cohen O *et al.*
Hadar T, Yaniv E, Shvero J, Isolated sphenoid sinus changes - history, CT and endoscopic finding. *Orig. Art.* **110**: 850
Hadar T, *see also* Shvero J *et al.*
Haddad FF *see* Atiyeh BS *et al.*
Hadfield PJ, Fisher C, Archer DJ, Adenoid cystic carcinoma of the maxilla - the value of histopathology in diagnosing a second primary. *Path. Focus* **110**: 503
Hadfield PJ, Motamed M, Glover GW, Synergistic necrotizing cellulitis resulting from peritonsillar abscess. *Clin. Rec.* **110**: 887
Hadfield PJ, Shah BK, Glover GW, Facial palsy due to tuberculosis: the value of CT. *Rad. Focus* **109**: 1010
Hadfield PJ, *see also* Lim JC *et al.*
Hadley DM *see* Cooke and Hadley
Hadley J, Coady AT, Milford CA, Pseudotumour of the maxillary antrum. *Clin. Rec.* **104**: 244
Hadley J, Gardiner Q, Dilkes M, Boyle M, Myxoma of the larynx: a case report and a review of the literature. *Path. Focus* **108**: 811
Hadley J, *see also* Gonzalez-Garcia J *et al.*; Morgan DW *et al.*

Haebara H *see* Kaga K *et al.*
Haglund S *see* Dueñas L *et al.*
Hagrass M *see* El-Guindy A *et al.*
Hagrass MAE, Gamea AM, El-Sherief SG, El-Guindy AS, El-Tatawi FAV, Radiological and endoscopic study of the maxillary sinus in primary atrophic rhinitis. *Orig. Art.* **106**: 702
Haguet J-F *see* Koka VN *et al.*
Haider-Ali AM, MacGregor F, Stewart M, Myasthenia gravis presenting with dysphagia and post-operative ventilatory failure. *Clin. Rec.* **112**: 1194
Haight JS *see* Tvinnereim M *et al.*
Hainau B *see* Saleem M *et al.*
Haixia J *see* Hongzheng and Haixia
Hajioff D, Snow MH, Thaker H, Wilson JA, Primary tuberculosis of the posterior oropharyngeal wall. *Clin. Rec.* **113**: 1029
Hajjaj M, Linthicum FH, Facial nerve schwannoma: nerve fibre dissemination. *Orig. Art.* **110**: 632
Halaka AN *see* Ahmed YS *et al.*
Hald J, Larsen PL, Nasopharyngeal carcinoma in an HIV-positive patient causing severe morbidity and early death. *Clin. Rec.* **107**: 149
Hald J, Milroy CM, Damkjaer Jensen J, Parving A, Human temporal bone findings in acquired hypothyroidism. *Orig. Art.* **105**: 886
Halder D *see* Sharma HS *et al.*
Halford JBS, Anderson SD, Tinnitus severity measured by a subjective scale, audiometry and clinical judgement. *Orig. Art.* **105**: 89
Halimi P *see* Laccourreye O *et al.*
Hall-Craggs MA *see* Irving RM *et al.*
Halpern M *see* Talmi YP *et al.*
Halvorson DJ, Kuhn FA, Tracheoesophageal speech following transmucosal pharyngeal myotomy with the potassium-titanyl-phosphate laser. *Clin. Rec.* **111**: 659
Hamans E *see* Van Laer C *et al.*
Hamid AM, Alshaikhly A, Granular cell tumour of the larynx in an eight-year-old girl. *Clin. Rec.* **107**: 940
Hamid AM, *see also* Alshaikhly A *et al.*
Hamilton J *see* Hartley C *et al.*; Jones AS *et al.*; Nandapalan V *et al.*; Ramsden RT *et al.*
Hammerlin S, Kapadia R, An unusual foreign body in the larynx. *Clin. Rec.* **110**: 679
Hampal S, Flood LM, Jones RA, Chordoma of the parapharyngeal space. *Clin. Rec.* **106**: 549
Hampal S, Flood LM, Kumar BU, The mini-grommet and tympanosclerosis. *Orig. Art.* **105**: 161
Hampal S, Hawthorne M, Hypopharyngeal inverted papilloma. *Clin. Rec.* **104**: 432
Hampal S, Oswal VH, The laryngeal box: an aid to laser microlaryngeal surgery. *Short Comm.* **105**: 946
Hampal S, *see also* Agrawal R *et al.*; Dingle AF *et al.*; Roberts DN *et al.*
Hampson K, Bourn D, Principles of molecular genetics. *Mol.Biol.* **112**: 128
Hampton S *see* Camilleri AE *et al.*
Hampton SM, Cinnamond MJ, Subcutaneous-emphysema as a complication of tonsillectomy. *Clin. Rec.* **111**: 1077
Hampton SM, Toner JG, Small J, Cochlear implant extrusion in a child with keratitis, ichthyosis and deafness syndrome. *Clin. Rec.* **111**: 465
Hamzah M *see* Gendah BS *et al.*
Han JW *see* Kim K-S *et al.*
Hanafi Z *see* Lancaster JL *et al.*
Hancock K *see* McAllister RMR *et al.*
Hand DW *see* Irani BS *et al.*
Handžić-Čuk J, Čuk V, Risavi R, Katić V, Katušić D, Bagatin M, Štajner-Katušić S, Gortan D, Pierre Robin syndrome: characteristics of hearing loss, effect of age on hearing level and possibilities in therapy planning. *Orig. Art.* **110**: 830
Hanif H *see* Oluwole and Hanif
Hanly M *see* Louis N *et al.*
Hanna GS *see* Singh KB *et al.*
Hanning CD *see* Prichard AJN *et al.*
Hansel TT *see* Snow DG *et al.*
Hansen HS *see* Munk-Nielsen and Hansen
Hansen LT, Kristensen S, Moesner J, Polypoidal carcinosarcoma of the oropharynx: a clinicopathological and immunohistochemical study of two cases. *Path. Focus* **109**: 459
Hansen RK *see* Tvinnereim M *et al.*
Hanson DR *see* Ahmed YS *et al.*
Happonen R-P *see* Atula T *et al.*
Haqqani MT *see* Khan MHZ *et al.*; Sherman IW *et al.*
Har-El C *see* Sabin SL *et al.*
Har-El G, Heffner K, Ruffy M, Haemangioma in a cervical lymph node. *Clin. Rec.* **104**: 513
Har-El G, Josephson JS, Infectious mononucleosis complicated by lingual tonsillitis. *Clin. Rec.* **104**: 651
Har-El G, *see also* Lanza J *et al.*; Singh B *et al.*
Hara A, Kusakari J, Shinohara A, Yamada Y, Sato N, Intrusion of an incisor tooth into the contralateral frontal sinus following trauma. *Clin. Rec.* **107**: 240
Harabuchi Y *see* Ohguro S *et al.*
Harada H, Kashiwagi S, Fujiura H, Kusukawa J, Morimatsu M, Epithelial-myoepithelial carcinoma — report of a case arising in the nasal cavity. *Path. Focus* **110**: 397
Harada H, Kashiwagi S, Morimatsu M, Kameyama T, Takahashi M, Tonsillar lipoma: a case report. *Clin. Rec.* **109**: 662
Harada H, Morimatsu M, Kusukawa J, Kameyama T, A harmartoma-like mass on the palate? A possible discussion regarding components of pigmented naevus and hyperplastic salivary gland. *Path. Focus* **111**: 296
Harada H, Shiraishi K, Kato T, Soda T, Coherence analysis of EEG changes during odour stimulation in humans. *Orig. Art.* **110**: 652
Harada Y *see* Hirakawa K *et al.*; Suzuki M *et al.*
Haraguchi H, Hentona H, Tanaka H, Komatuzaki A, Pleomorphic adenoma of the external auditory canal: a case report and review of the literature. *Clin. Rec.* **110**: 52
Haraguchi H, Ohgaki T, Hentona H, Komatsuzaki A, Schwannoma of the posterior pharyngeal wall: a case report. *Clin. Rec.* **110**: 170
Haraguchi H, *see also* Noguchi Y *et al.*
Harar RPS, Kalan A, Brown CL, Kenyon GS, A unique tumour of the geniohyoid muscle: an intramuscular haemangioma. *Clin. Rec.* **111**: 769
Harar RPS, *see also* Ganesan S *et al.*; Kalan A *et al.*
Harb JM *see* Gardner PM *et al.*
Harcourt J *see* Stangerup S-E *et al.*; Worley GA *et al.*
Harcourt JP, Gallimore AP, Leiomyoma of the paranasal sinuses. *Clin. Rec.* **107**: 740
Harcourt JP, Lennox P, Phelps PD, Brookes GB, CT screening for temporal bone abnormalities in idiopathic bilateral sensorineural hearing loss. *Orig. Art.* **111**: 117
Harcourt JP, Tungekar MF, Schwannoma of the external auditory canal. *Path. Focus* **109**: 1016
Harcourt JP, Vijaya-Sekaran S, Loney E, Lennox P, The incidence of symptoms consistent with cerebello-pontine angle lesions in a general ENT outpatient clinic. *Orig. Art.* **113**: 518
Harcourt JP, *see also* McBrien F *et al.*
Harding L *see* Walsh RM *et al.*
Hardisson D *see* De Diego JI *et al.*
Hardisty RE, Fleming J, Steel KP, The molecular genetics of inherited deafness: current knowledge and recent advances. *Mol. Biol.* **112**: 432
Hardjasudarma M *see* Qiu WW *et al.*
Hardy D *see* Moffat DA *et al.*
Hardy DG *see* Baguley DM *et al.*; Moffat DA *et al.*; Morris DP *et al.*; Reece PH *et al.*
Harell M *see* Berger G *et al.*
Hargreaves S *see* de Carpentier JP *et al.*
Hargreaves SP *see* de Carpentier JP *et al.*; Morris DP *et al.*
Hari CK, Brown MJKM, Thompson I, Tall cell variant of papillary carcinoma arising from ectopic thyroid tissue in the trachea. *Path. Focus* **113**: 183
Hari CK, Roblin DG, Brown MJKM, Thompson I, An unusual presentation of an encephalocele to the otolaryngologist. *Clin. Rec.* **113**: 369
Hari CK, Roblin DG, Clayton MI, Nair RG, Acute angle closure glaucoma precipitated by intranasal application of cocaine. *Clin. Rec.* **113**: 250
Hari Madhavan KN *see* Natarajan B *et al.*
Haribhakti VV *see* Howard and Haribhakti
Harihar V, An unusual treatment for a rare dilemma (oesophageal foreign body). *Clin. Rec.* **105**: 46
Hariri MA, Vice PA, Septic shock and death due to occult sinusitis. *Clin. Rec.* **104**: 990

Hariri MA, *see also* Small and Hariri
Harkness P, Submandibular salivary disease: a proposed allergic aetiology. *Clin. Rec.*. **109**: 66
Harkness P, Brown P, Fowler S, Grant H, Topham J, A confidential comparative audit of stapedectomies: results of the Royal College of Surgeons of England Comparative Audit of ENT Surgery 1994. *Aud. Art.* **109**: 317
Harkness P, Dossetor R, Weighill J, Papilloedema, an unusual complication of mastoidectomy. *Clin. Rec.* **110**: 878
Harmse JL, Saleh HA, Odutoye T, Alsanjari NA, Mountain RE, Recurrent canalicular adenoma of the minor salivary glands in the upper lip. *Path. Focus* **111**: 985
Harrell M *see* Englender M *et al.*
Harries M, Hawkins S, Hacking J, Hughes I, Changes in the male voice at puberty. Vocal fold length and its relationship to the fundamental frequency of the voice. *Orig. Art.* **112**: 451
Harries M, *see also* Lennox PA *et al.*
Harries ML, Laryngeal framework surgery. *Edit. Rev.* **111**: 103
Harries ML, Unilateral vocal fold paralysis: a review of the current methods of surgical rehabilitation. *Rev. Art.* **110**: 111
Harries ML, Morrison M, The role of stroboscopy in the management of a patient with a unilateral vocal fold paralysis. *Orig. Art.* **110**: 141
Harries ML, *see also* Farrell ML *et al.*; Spraggs and Harries
Harries MLL, Lam S, MacAulay C, Qu J, Palcic B, Diagnostic imaging of the larynx: autofluorescence of laryngeal tumours using the helium–cadmium laser. *Orig. Art.* **109**: 108
Harries MLJ *see* Gray RF *et al.*; Rudd MJ *et al.*
Harries PG, Retropharyngeal abscess and acute torticollis. *Clin. Rec.* **111**: 1183
Harries PG, Antonios DA, Carruth JS, Carruth JAS, The surgical treatment of snoring. *Rev. Art.* **110**: 1105
Harries PG, Brockbank MJ, Shakespeare PG, Carruth JAS, Treatment of hereditary haemorrhagic telangiectasia by the pulsed dye laser. *Orig. Art.* **111**: 1038
Harries PG, Mason PS, Ramsay AD, Carruth JAS, Idiopathic tracheal stenosis. *Clin. Rec.* **110**: 973
Harries PG, Randall CJ, Adult floppy epiglottis: a simple surgical remedy. *Clin. Rec.* **109**: 871
Harris C, Richards C, Functional aphonia in young people. *Orig. Art.* **106**: 610
Harris D *see* Sim DW *et al.*
Harris JRW *see* French PD *et al.*
Harris R *see* Evans DGR *et al.*; Huson SM *et al.*; Neary WJ *et al.*
Harris WE, A lingual thyroid cyst complicating a foreign body in the oesophagus. *Clin. Rec.* **104**: 508
Harrison D, Benjamin Guy Babington and his mirror. *Hist. Art.* **112**: 235
Harrison DFN, Laryngeal morphology in sudden unexpected death in infants. *Orig. Art.* **105**: 646
Harrison DFN, The head and neck surgeon–activist or moralist? *Clin. Rec.* **105**: 1121
Harrison HC, Gibson WPR, Thompson PG, Cochlear implant extrusion in a young child — a preventative procedure. *Clin. Rec.* **109**: 425
Harrison HC, Lammi A, Adenoidectomy in a girl with haemophilia. *Clin. Rec.* **105**: 957
Harrison HC, Tindall B, McCarthy SW, Cooper DA, Nasopharyngeal cyst simulating Kaposi's sarcoma in an HIV-infected patient. *Clin. Rec.* **104**: 498
Harrison HC, *see also* Gibson and Harrison; Gibson WPR *et al.*
Harrison M *see* Gaffney RJ *et al.*
Harrison R *see* Elwany and Harrison; Wake M *et al.*
Harrison RF *see* Liddington MI *et al.*
Harrison Sir Donald, Has the speciality of ENT-Head and Neck Surgery a future? *Edit. Art.* **110**: 717
Harrison Sir Donald, The Garnet Passe and Rodney Williams Memorial Foundation *Edit. Art.* **110**: 717
Harsten G, Nettelbladt U, Schalén L, Kalm O, Prellner K, Language development in children with recurrent acute otitis media during the first three years of life: follow-up study from birth to seven years of age. *Orig. Art.* **107**: 407
Harsten G, Prellner K, Löfgren B, Kalm O, Serum antibodies against respiratory tract viruses in episodes of acute otitis media. *Orig. Art.* **105**: 337
Harsten G, *see also* Lagerholm S *et al.*
Hartley BEJ, Bottrill ID, Howard DJ, A third decade's experience with the gastric pull-up operation for hypopharyngeal carcinoma: changing patterns of use. *Orig. Art.* **113**: 241
Hartley BEJ, Fagan JJ, Rhŷs-Evans PH, Excision of adenoid cystic carcinoma of the cervical trachea via an anterior castellated approach. *Clin. Rec.* **109**: 774
Hartley BEJ, Rowe-Jones J, Uvulectomy to prevent throat infections. *Clin. Rec.* **108**: 65
Hartley BEJ, Searle AE, Breach NM, Rhŷs-Evans PH, Henk JM, Aggressive cutaneous squamous cell carcinoma of the head and neck in patients with chronic lymphocytic leukaemia. *Clin. Rec.* **110**: 694
Hartley C, Ascott F, Laryngeal involvement in mitochondrial myopathy. *Clin. Rec.* **108**: 685
Hartley C, Axon PR, The Foley catheter in epistaxis management — a scientific appraisal. *Clin. Rec.* **108**: 399
Hartley C, Hamilton J, Birzgalis AR, Farrington WT, Recurrent respiratory papillomatosis — the Manchester experience, 1974-1992. *Orig. Art.* **108**: 226
Hartley C, Mendelow AD, Post-traumatic bilateral facial palsy. *Clin. Rec.* **107**: 730
Hartley C, Saeed SR, Farrington WT, Post-laryngectomy neopharyngeal diverticulae. *Orig. Art.* **108**: 479
Hartley C, Saeed SR, Lyons TJ, Non-cholesteatomatous suppurative otitis media: facial nerve palsy in an immunocompromised patient. *Clin. Rec.* **109**: 755
Hartley C, Willatt DJ, Cryotherapy in the treatment of nasal obstruction: indications in adults. *Orig. Art.* **109**: 729
Hartley C, *see also* Axon PR *et al.*; Lobo CJ *et al.*; Saeed SR *et al.*; Simo R *et al.*
Harun S *see* Ajulo SO *et al.*
Harvey G *see* Parton M *et al.*
Harvey L *see* El-Silimy and Harvey
Hasan S, Dutt SN, Kini U, Shariff S, Nalinesha KM, Prasad D, Laryngeal carcinoma ex-papilloma in a non-irradiated, non-smoking patient : a clinical record and review of the literature. *Clin. Rec.* **109**: 762
Hasan S, Kannan V, Shenoy AM, Nanjundappa MS, Naresh KN, Chondrosarcoma of the hyoid. *Clin. Rec.* **106**: 273
Hasan SH *see* Aijaz F *et al.*
Hasçelik G, *see* Şener B *et al.*
Hasegeli L *see* Öncel S *et al.*
Hasham A *see* Asiri S *et al.*
Hashiguchi K, Ogawa H, Kazuyama Y, Seroprevalence of *Chlamydia pneumoniae* infections in otolaryngeal diseases. *Orig. Art.* **106**: 208
Hashiguchi K, *see also* Ogawa H *et al.*
Hashimoto S *see* Watanabe K *et al.*
Hashmi SMH *see* Chitre VV *et al.*
Hashmonai M *see* Hefer T *et al.*
Hasleton PS *see* Ramamurthy L *et al.*
Hasnie A *see* Hern JD *et al.*
Hassan WU, Henderson AE, Cough and stridor: who should investigate the patient? *Clin. Rec.* **107**: 639
van Hasselt CA, Mastoid surgery and the Hong Kong Flap **108**: 825
Van Hasselt CA, Ng HK, Papillary adenocarcinoma of the nasopharynx. *Clin. Rec.* **105**: 853
van Hasselt CA, *see also* Chalstrey SE *et al.*; Chi Fai Tong M *et al.*; Choy ATK *et al.*; Gluckman PGC *et al.*; John DG *et al.*; Ku PKM *et al.*; Pak MW *et al.*; Porter MJ *et al.*; Rushton HC *et al.*; Scott PMJ *et al.*; Sham CL *et al.*; Syed A *et al.*; Tang NLS *et al.*; Tong MCF *et al.*; Tsang RKY *et al.*; Woo JKS *et al.*
Hastings DL *see* Slevin NJ *et al.*
Hathiram BT, Grewal DS, Irani DK, Tankwal PM, Patankar M, Tuberculoma of the cheek: a case report. *Clin. Rec.* **111**: 872
Hauben E *see* de Varebeke SJ *et al.*
Hauser R *see* Maier W *et al.*
Havlat MF *see* Fergie N *et al.*
Hawke M *see* Khanobthamchai K *et al.*; McCombe A *et al.*; Pace-Balzan and Hawke
Hawkins S *see* Harries M *et al.*
Hawthorne M, El-Naggar M, Fenestration and occlusion of posterior semicircular canal for patients with intractable benign paroxysmal positional vertigo. *Orig. Art.* **108**: 935
Hawthorne M, *see also* Collins M *et al.*; El-Naggar and Hawthorne; Hampal and Hawthorne; Kale U *et al.*; Morgan M *et al.*; Rashad U *et al.*; Richardson HC *et al.*

Hawthorne MR, Nunez DA, Clarke GP, Robertshaw D, Direct referral hearing aid provision in the over sixties age group. *Orig. Art.* **105**: 825
Hawthorne MR, *see also* Abou-Elhmd KA *et al.*; Maw and Hawthorne
Haybittle JL *see* Alcock GJ *et al.*
Haye R, Aanesen JP, Burtin B, Donnelly F, Duby C, The effect of cetirizine on symptoms and signs of nasal polyposis. *Orig. Art.* **112**: 1042
Haynes H *see* Rubin JS *et al.*
Haynes RJ *see* Mason JDT *et al.*
Hayward KA *see* Rajenderkumar D *et al.*
Hazarika P, Nayak DR, Sahota JS, Rao D, Kapadia RD, Osteogenic sarcoma of the sphenoid bone: an extended lateral skull base approach. *Clin. Rec.* **109**: 1101
Hazarika P, Siddiqui SA, Pujary K, Shah P, Nayak DR, Balakrishnan R, Dual ectopic thyroid: a report of two cases. *Clin. Rec.* **112**: 393
Hazarika P, *see also* Balakrishnan R *et al.*
Hazuka M *see* Talmi YP *et al.*
He P *see* Mu L *et al.*
Healy GB *see* Ikeda M *et al.*; Kitahara S *et al.*; Takayama E *et al.*
Healy K *see* Curley TWA *et al.*
Heaton JM, Barton J, Ranalli P, Tyndel F, Mai R, Rutka JA, Evaluation of the dizzy patient: experience from a multidisciplinary neurotology clinic. *Orig. Art.* **113**: 19
Heaton JM, Bingham BJG, Osborne J, A comparison of performance of Shepard and Sheehy collar button ventilation tubes. *Orig. Art.* **105**: 896
Heaton JM, Blair RL, Shadbolt C, Christmas H, An assessment of the incidence of iron deficiency in paediatric otolaryngology inpatients. *Orig. Art.* **105**: 1021
Heaton JM, Parker AJ, *In vitro* comparison of the Groningen high resistance, Groningen low resistance and Provox speaking valves. *Orig. Art.* **108**: 321
Heaton JM, Sanderson D, Dunsmore IR, Parker AJ, Speech assessment of patients using three types of indwelling tracheo-oesophageal voice prostheses. *Orig. Art.* **110**: 343
Heaton JM, *see also* Prichard AJN *et al.*
Hefer T, Joachims HZ, Eitan A, Golz A, Brown J, Highly invasive papillary thyroid carcinoma. *Clin. Rec.* **108**: 889
Hefer T, Joachims HZ, Hashmonai M, Ben-Arieh V, Brown J, Highly aggressive behaviour of occult papillary thyroid carcinoma. *Clin. Rec.* **109**: 1109
Hefer T, Joachims HZ, Munichor M, Eitan A, Are the morphology of papillary thyroid carcinoma and tumour's behaviour correlated? *Path. Focus* **110**: 704
Hefer T, Manor R, Joachims HZ, Groisman GM, Peled M, Gov-Ari E, Laufer D, Metastatic follicular thyroid carcinoma to the maxilla. *Clin. Rec.* **112**: 69
Hefer T, Nir D, Joachims HZ, More about pain in the neck: thyroid cartilage and mastoid process syndromes. *Clin. Rec.* **111**: 1190
Hefer T, *see also* Danino J *et al.*
Heffner DK *see* Williams SB *et al.*
Heffner K *see* Har-El G *et al.*
Hegde R, Bhargava S, Bhargava KB, Pseudocyst of the auricle: a new method of treatment. *Clin. Rec.* **110**: 767
Hehar S *see* Baer S *et al.*
Hehar SS, Dugar J, Sharp J, The changing faces of a parotid mass. *Clin. Rec.* **113**: 938
Hehar SS, Johnson IJM, Jones NS, Glossal abscess presenting as unilateral tongue swelling. *Clin. Rec.* **110**: 389
Hehar SS, Jones NS, Fronto-ethmoid osteoma: the place of surgery. *Clin. Rec.* **111**: 372
Hehar SS, Jones NS, Sadiq SA, Downes RN, Endoscopic holmium: YAG laser dacryocystorhinostomy - safe and effective as a day-case procedure. *Orig. Art.* **111**: 1056
Hehar SS, *see also* Mason JDT *et al.*
Heimann P *see* Saussez S *et al.*
Hein D *see* Ingrams D *et al.*
Heineman E *see* Vos GD *et al.*
Helidonis E *see* Velegrakis G *et al.*
Helidonis ES *see* Velegrakis GA *et al.*
Hellier W *see* Whittam and Hellier
Hellier WPL, Brookes GB, Vestibular nerve dysfunction and decompression in Engelmann's disease. *Clin. Rec.* **110**: 462
Hellier WPL, Crockard HA, Cheesman AD, Metastatic carcinoma of the temporal bone presenting as glomus jugulare and glomus tympanicum tumours: a description of two cases. *Clin. Rec.* **111**: 963
Hellier WPL, McCombe A, Extracapsular haemorrhage from a parathyroid adenoma presenting as a massive cervical haematoma. *Clin. Rec.* **111**: 585
Hellin D *see* Merino E *et al.*
Hellin-Meseguer D *see* Melgarejo-Moreno and Hellin-Meseguer; Melgarejo-Moreno PJ *et al.*
Hellquist HB, Lundgreen J, Neurogenic sarcoma of the sinonasal tract. *Orig. Art.* **105**: 186
Hellquist HB, *see also* Davidsson Å *et al.*
Hellström MS *see* Spandow O *et al.*
Helmes J *see* Geyer G *et al.*
Helms J, Geyer G, Closure of the petrous apex of the temporal bone with ionomeric cement following translabyrinthine removal of an acoustic neuroma. *Clin. Rec.* **108**: 202
Helms J, *see also* Geyer G *et al.*
Hemani DD *see* Soni and Hemani
Hemsley S *see* Maharaj D *et al.*
Henderson A *see* Ravi and Henderson
Henderson AF *see* Hassan and Henderson
Henein RR *see* Meehan and Henein; Sood S *et al.*
Henk JM *see* Hartley BEJ *et al.*; Mitchell G *et al.*
Henne K *see* Maier W *et al.*
Hennessy TPJ *see* Lacy PD *et al.*
Henriksen AO *see* Senfors and Henriksen; Senfors LE *et al.*
Hentona H *see* Haraguchi H *et al.*
Heo SJ, Sennerby L, Granström G, Tjellström A, Meredith N, Stability measurements of craniofacial implants by means of resonance frequency analysis: a clinical pilot study. *Orig. Art.* **112**: 537
Herberger S *see* Riley DN *et al.*
Herdman RCD, Charlton A, Hinton AE, Freemont AJ, An *in vitro* comparison of the erbium: YAG laser and the carbon dioxide laser in laryngeal surgery. *Orig. Art.* **107**: 908
Herdman RCD, Gillespie JE, Ramsden RT, Facial palsy after glomus tumour embolization. *Rad. Focus* **107**: 963
Herdman RCD, Morgan K, Holt PJL, Ramsden RT, Type 11 collagen autoimmunity and Ménière's disease. *Orig. Art.* **107**: 994
Herdman RCD, *see also* Koay and Herdman; Ramsden RT *et al.*
Herman P *see* Marianowski R *et al.*
Hermans R, Sciot R, Delaere P, Van Damme B, Baert AL, Callus originating in the laryngeal skeleton, presenting as a neck lump: case report. *Rad. Focus* **108**: 354
Hern J *see* Hollis LJ *et al.*; Lennox P *et al.*
Hern JD, Almeyda J, Thomas DM, Main J, Patel KS, Malignant otitis externa in HIV and AIDS. *Clin. Rec.* **110**: 770
Hern JD, Coley SC, Hollis LJ, Jayaraj SM, Delayed massive epistaxis due to traumatic intracavernous carotid artery pseudoaneurysm. *Rad. Focus* **112**: 396
Hern JD, Hasnie A, Shah NS, A long-term review of the Shah Permavent tube. *Orig. Art.* **109**: 277
Hern JD, Hollis LJ, Mochloulis G, Montgomery PQ, Tolley NS, Early diagnosis of Wegener's granulomatosis presenting with facial nerve palsy. *Clin. Rec.* **110**: 459
Hern JD, *see also* Hollis LJ *et al.*; Jayaraj SM *et al.*; Mochloulis G *et al.*; Worley GA *et al.*
Hernández AM *see* Campos A *et al.*
Herskovitz P *see* Cohen O *et al.*
Hertzanu Y *see* Tovi F *et al.*
Van de Heyning P *see* Van Laer C *et al.*
Van de Heyning PH *see* de Varebeke SJ *et al.*; Vanden Abeele D *et al.*
Heyworth T *see* Koay CB *et al.*
Hickey SA, Buckley JG, Macartney JC, Adenoidal hypertrophy as the presenting feature of HIV infection. *Path. Focus* **104**: 58
Hickey SA, Clarke PM, Hazardous party trick (Infolding of the pinna). *Clin. Rec.* **105**: 362
Hickey SA, FitzGerald O'Connor AF, Measurement of drill-generated noise levels during ear surgery. *Orig. Art.* **105**: 732
Hickey SA, Ford GR, Buckley JG, Fitzgerald O'Connor AF, Unterberger stepping test: a useful indicator of peripheral vestibular dysfunction? *Orig. Art.* **104**: 599

Hickey SA, Ford GR, Evans JNG, Patrick JA, Spencer GT, Tracheostomy closure in restrictive respiratory insufficiency. *Orig. Art.* **104**: 883
Hickey SA, Mitchell DB, Buckley JG, Fitzgerald O'Connor AF, Wunderlich JL, Electrocochleography: a new technique. *Short Comm.* **104**: 326
Hickey SA, Scott GA, Traub P, Defects of the first branchial cleft. *Clin. Rec.* **108**: 240
Hickey SA, *see also* Buckley JG *et al.*; Skia B *et al.*; Wittig FJ *et al.*
Hicklin L, Tostevin PMJ, Wyatt ME, Parental satisfaction with paediatric day-case ENT surgery. *Orig. Art.* **113**: 1072
Hickman J *see* Mayall F *et al.*; Mayall FG *et al.*
Hier MP *see* Yoskovitch A *et al.*
Hierro C *see* Solanellas J *et al.*
Higashi K, Edo M, Conductive deafness in aglossia. *Clin. Rec.* **110**: 1057
Higashi K, Matsuki C, Coffin–Lowry syndrome with sensorineural deafness and labyrinthine anomaly. *Clin. Rec.* **108**: 147
Higashikawa M *see* Takasaki T *et al.*
Higgins N *see* Reece PH *et al.*
Hilberg O *see* Grymer LJ *et al.*
Hildesheimer M *see* Cinamon U *et al.*
Hilger AW, Prichard AJ, Jones T, Adenocarcinoma of the larynx: a distant metastasis from a rectal primary. *Path. Foc.* **112**: 199
Hilger AW, Thompson SD, Smallman LA, Watkinson JC, Papillary carcinoma arising in a thyroglossal duct cyst: a case report and literature review. *Path. Focus* **109**: 1124
Hilgers FJM *see* Balm AJM *et al.*; Dijkstra MD *et al.*; Elias MM *et al.*; Leemans CR *et al.*; Mak-Kregar S *et al.*; van der Laan BFAM *et al.*
Hill BT *see* Price LA *et al.*
Hill DS, Gaze MN, Grant HR, A simple reconstructive procedure for radiation-induced necrosis of the external auditory canal. *Orig. Art.* **112**: 1142
Hill J, Allan W, Malhan D, Williams ED, Pressure exerted by head bandages used in otological surgery. *Orig. Art.* **107**: 1110
Hill J, Elliott C, Colquhoun I, Audiological, vestibular and radiological abnormalities in Kallman's syndrome. *Clin. Rec.* **106**: 530
Hill J, *see also* Deans JAJ *et al.*; Richardson H *et al.*; Watson MG *et al.*
Hillier VF *see* Neary WJ *et al.*
Hillier VG *see* Newton VE *et al.*
Hilmi O *see* Baird AR *et al.*
Himi T *see* Ohguro S *et al.*
Himmelfarb M *see* Berger G *et al.*
Hinchcliffe R, Medical examiner variability. *Rev. Art.* **111**: 8
Hinchcliffe R, WHO and its role in the prevention of deafness and hearing impairment. *Edit. Rev.* **111**: 699
Hinohira Y *see* Gyo K *et al.*
Hinton AE, O'Connell JM, van Besouw JP, Wyatt ME, Neonatal paediatric fibre-optic laryngoscopy and bronchoscopy using the laryngeal mask airway. *Orig. Art.* **111**: 349
Hinton AE, Ramsden RT, Lye RH, Dutton JEM, Criteria for hearing preservation in acoustic Schwannoma surgery: the concept of useful hearing. *Orig. Art.* **106**: 500
Hinton AE, *see also* Coales UF *et al.*; Herdman RCD *et al.*; Martin-Hirsch DP *et al.*; Saeed SR *et al.*; Worley GA *et al.*
Hirakawa K, Harada Y, Tatsukawa T, Nagasawa A, Fujii M, A case of vascular leiomyoma of the larynx. *Clin. Rec.* **108**: 593
Hirakawa K, *see also* Suzuki M *et al.*
Hiranandani NL *see* Baser B *et al.*
Hirano M *see* Ito S *et al.*; Shimazaki T *et al.*; Tanaka Y *et al.*
Hiroshige K *see* Ikeda M *et al.*
Hisa Y., Tatemoto K, Dejima K, Nishiyama Y, Masuda Y, Ikuta H, Magnetic resonance imaging for aspirated peanut in the bronchus. *Clin. Rec.* **108**: 804
Hisashi K, Komune S, Inoue H, Komiyama S, Sugimoto T, Miyoshi M, Co-existance of MALT-type lymphoma and squamous cell carcinoma of the larynx. *Clin. Rec.* **108**: 995
Ho CM *see* Yuen APW *et al.*
Ho SF *see* Stoney PJ *et al.*
Ho TP, Samuel PR, Jeannon J-P, Malignant peripheral nerve sheath tumour of the spinal accessory nerve. *Clin. Rec.* **113**: 942
Ho WK *see* Tsang WYW *et al.*
Hoare TJ, Aldren CJ, Morgan DW, Bull TR, Unusual case of bilateral conductive deafness. *Clin. Rec.* **104**: 560
Hoare TJ, Pre-operative haemoglobin estimation in paediatric ENT surgery. *Orig. Art.* **107**: 1146
Hoare TJ, *see also* Morgan DW *et al.*; Wilson PS *et al.*
Hobson JA *see* Stevenson DS *et al.*
Hodge M *see* Quiney RE *et al.*
Hodgson J *see* Hughes AP *et al.*
Hoel T *see* Nordahl SHG *et al.*
Hoepelman AIM *see* Lohuis PJFM *et al.*
Hoeve HLJ *see* Bailey CM *et al.*
Hoffman HT *see* Devaiah AK *et al.*; Graham SM *et al.*; Victoria LV *et al.*
Hogan R *see* Welsh J *et al.*
Hogg RP, Ayshford C, Watkinson JC, Parotid duct carcinoma arising in bilateral chronic sialadenitis. *Path. Focus* **113**: 686
Hogg RP, Kuo MJ, Olliff J, Das Gupta AR, Invasion of the recurrent laryngeal nerve by adenoid cystic carcinoma. An unusual cause of true vocal fold paralysis. *Clin. Rec.* **113**: 260
Hogg RP, Pillay H, Mitchell R, Johnson AP, Idiopathic CSF rhinorrhoea presenting with tension pneumocephalus and hemiparesis. *Clin. Rec.* **112**: 654
Hojo H *see* Ishibashi T *et al.*; Murakami M *et al.*
Højslet PE, Moesgard-Nielsen V, Karlsmose M, Smoking cessation in chronic Reinke's oedema. *Orig. Art.* **104**: 626
Holden M *see* Mason JDT *et al.*
Holding JD *see* Vreeburg GCM *et al.*
Holecek BU *see* Schipper JH *et al.*
Holgate CS *see* Soussi AC *et al.*
Holgate ST, Mavroleon G, The molecular and cell biology of allergy. *Mol. Biol.* **112**: 1126
Holland IM *see* Mason JDT *et al.*
Holland NJ *see* Myatt HM *et al.*
Holland S, Thaha MA, Nilssen ELK, White PS, Coagulation studies in patients admitted with epistaxis — current practice in Scotland. *Orig. Art.* **113**: 1086
Hollis LJ, Almeyda JS, Mochloulis G, Patel KS, An *in vitro* study of tracheostomy tube cuff herniation and inflation characteristics. *Orig. Art.* **110**: 1142
Hollis LJ, Bailey CM, Albert DM, Hosni A, Nasal lipomas presenting as part of a syndromic diagnosis. *Clin. Rec.* **110**: 269
Hollis LJ, El-Alami M, Pyke R, Pharyngo-oesophageal haemangioma with a positive cough impulse. *Clin. Rec.* **113**: 172
Hollis LJ, McGlashan JA, Walsh RM, Bowdler DA, Massive epistaxis following sphenoid sinus exploration. *Rad. Focus* **108**: 171
Hollis LJ, Montgomery PQ, Hern JD, Mahadeva U, Tolley NS, Invasive candidiasis of a late presentation laryngeal chondroradionecrosis. *Clin. Rec.* **110**: 789
Hollis LJ, Poole S, Hern J, Patel KS, Primitive neuroectodermal tumour of the masseter muscle. *Path. Focus* **110**: 1179
Hollis LJ, *see also* Hern JD *et al.*; Mochloulis G *et al.*; Tostevin PMJ *et al.*
Holloway TE *see* Drysdale AJ *et al.*
Holm E, Seibaek M, Iversen PB, Two cases of otolaryngeal tuberculosis in a Danish married couple. *Clin. Rec.* **109**: 1080
Holmes AH *see* Shinkin CA *et al.*
Holmstrom M *see* Golding-Wood DG *et al.*; Lund VJ *et al.*
Holt PJL *see* Herdman RCD *et al.*
Holten I *see* Petri and Holten
Holzki J *see* Berkovits RNP *et al.*
Homer JJ, Johnson IJM, Jones NS, Middle ear infection and sixth nerve palsy. *Clin. Rec.* **110**: 872
Homer JJ, Jones NS, Renal cell carcinoma presenting as a solitary paranasal sinus metastasis. *Clin. Rec.* **109**: 986
Homer JJ, *see also* Bradwell RA *et al.*
Homoe P, Lynnerup N, Skovgaard LT, Rasmussen N, Estimation of otitis media in ancient populations: a study of past and present Greenlandic Inuit. *Orig. Art.* **110**: 1114
Honda N *see* Gyo and Honda
Honda Y *see* Moriyama H *et al.*
Hone R *see* Hone SW *et al.*
Hone SW, Moore J, Fenton J, Gormley PK, Hone R, The role of *Chlamydia pneumoniae* in severe acute tonsillitis. *Orig. Art.* **108**: 135
Hong A *see* Morris DP *et al.*
Hong KH, Moon WS, Chung GH, Radiological appearance of primary branchial cleft cyst carcinoma. *Rad. Focus* **113**: 1031
Hong KH, Seo SY, Lee DG, Chondrolipoma on the nasopharynx. *Clin. Rec.* **112**: 75

Hong Y, Chong VFH, Low WK, Temporal bone tumours in patients irradiated for nasopharyngeal neoplasm. *Orig. Art.* **113**: 222
Hongzheng S, Haixia J, Combined therapy for carcinoma of the nasopharynx: a report of 49 cases. *Orig. Art.* **107**: 201
Hönig M *see* Bergler W *et al.*
Hope-Stone HF *see* Neal AJ *et al.*
Hopewell JW *see* Alcock GJ *et al.*
Hopkinson JM *see* Hussain and Hopkinson
Hopkinson L *see* Mirza S *et al.*
Hopper C *see* Grant WE *et al.*
Hopper I *see* Lindsey and Hopper
Hordijk GJ *see* Lohuis PJFM *et al.*; Ravasz LA *et al.*
Hore I, Mitchell RB, Radcliffe G, Quiney R, Walker T, Langerhans' cell histiocytosis — a rare cause of sudden onset unilateral sensorineural hearing loss. *Clin. Rec.* **113**: 1098
Horgan K *see* Sood S *et al.*
Horikawa T *see* Yoshizaki T *et al.*
Hörmann K, Baker-Schreyer A, Keilmann A, Biermann G, Functional results after CO_2 laser surgery compared with conventional phonosurgery. *Orig. Art.* **113**: 140
Hörmann K, *see also* Bergler W *et al.*; Keilmann A *et al.*
Horowitz Z *see* Talmi YP *et al.*
Horrocks CL *see* Ford and Horrocks
Horrocks JM *see* Hussain SSM *et al.*
Hoşal AS *see* Ünal ÖF *et al.*
Hosal S *see* Sözeri B *et al.*
Hoshino T, Ishizaki H, Iwasaki S, Sakai T, Osteoplastic changes in attic cholesteatoma. *Orig. Art.* **109**: 703
Hoshino T, Miyashito H, Asai V, Computed tomography of the temporal bone in tuberculous otitis media. *Rad. Focus* **108**: 702
Hoshino T, Ueda Y, Mukohdaka H, Mizuta K, Acute granulomatous myringitis. *Orig. Art.* **112**: 150
Hosni A, Fisher C, Rhŷs-Evans P, Two malignant salivary gland tumours of different type in one patient. *Clin. Rec.* **108**: 798
Hosni A, *see also* Hollis LJ *et al.*; Hosney A *et al.*; Tostevin PMJ *et al.*
Hosni AA, Innes AJ, Hereditary haemorrhagic telangiectasia: Young's procedure in the management of epistaxis. *Orig. Art.* **108**: 754
Hosni AA, Rhŷs-Evans P, Cervical osteomyelitis and cord compression complicating pharyngeal myotomy. *Clin. Rec.* **108**: 511
Hosni AA, *see also* Barker and Hosni; Kedjanyi WK *et al.*; Rowe and Hosni
Hosny A, Bhendwal S, Hosni A, Transection of cervical trachea following blunt trauma. *Clin. Rec.* **109**: 250
Hosoi H, Murata K, Kimura H, Tsuta Y, Long-term observation after soft posterior meatal wall reconstruction in ears with cholesteatoma. *Orig. Art.* **112**: 31
Hosokawa H *see* Miyaguchi M *et al.*
Houghton D *see* Parton M *et al.*
Houghton DJ, Camilleri AE, Stone P, Adult obstructive sleep apnoea syndrome and tonsillectomy. *Orig. Art.* **111**: 829
Houghton DJ, White PS, The carcinogenic risk of exposure to sulphuric acid fumes from lead acid batteries. *Clin. Rec.* **108**: 881
Housui M *see* Tsunoda K *et al.*
van Houten RJ, Premachandra DJ, Topical active H_1-antihistamines and their effect on nasal airway resistance. *Orig. Art.* **109**: 841
Howard D *see* Lloyd G *et al.*
Howard DJ, Haribhakti VV, Primary tumours of the trachea: analysis of clinical features and treatment results. *Orig. Art.* **108**: 230
Howard DJ, Lund VJ, The midfacial degloving approach to sinonasal disease. *Orig. Art.* **106**: 1059
Howard DJ, Lund VJ, The role of midfacial degloving in modern rhinological practice. *Orig. Art.* **113**: 885
Howard DJ, *see also* Bottrill ID *et al.*; Briggs RJS *et al.*; Fisher and Howard; Hartley BEJ *et al.*; Jones E *et al.*; Lennox PA *et al.*; Lund and Howard; Macgregor FB *et al.*
Howarth KL *see* Camilleri AE *et al.*
Howat AJ *see* Osammor and Howat
Howell A *see* Curley RT *et al.*
Howitt RJ *see* Tay and Howitt
Howlett DC *see* Buckland JR *et al.*
Hsu C-Y *see* Jiang R-S *et al.*
Hsu C *see* Lau SK *et al.*
Hu JH *see* Huang H *et al.*
Huang H, Jing D, Li Z, Zhou S, Xiao S, Ma D, Zhang R, Analysis of lectin receptors in normal nasal mucosa, nasal polyp, inverted papilloma and papillary adenocarcinoma. *Orig. Art.* **107**: 600
Huang H, Zhou JH, Zhou SM, Hu JH, Pan XH, Kong XT, Yu L, Sun XY, Wu W, EpsteinBarr virus BHRF1 prohibits the cells of nasopharyngeal carcinoma from apoptosis. *Orig. Art.* **111**: 1147
Huang TS *see* Yen PT *et al.*
Huchzermeyer P, Birchall MA, Kendall B, Bailey CM, Parotid haemangiomas in childhood: a case for MRI. *Rad. Focus* **108**: 892
Huchzermeyer P, *see also* Al-Shahi R *et al.*
Huggare J *see* Niemelä M *et al.*
Hughes AP, Appleton RE, Hodgson J, Acquired aphasia without deafness in childhood — the Landau–Kleffner syndrome. *Clin. Rec.* **107**: 623
Hughes I *see* Harries M *et al.*
Hughes JB *see* Lightfoot and Hughes
Hughes KB *see* Carrie S *et al.*
Hughes M *see* Fairley and Hughes
Hughes RGM, Gibbin KP, Lowe J, Vocal fold abductor paralysis as a solitary and fatal manifestation of multiple system atrophy. *Clin. Rec.* **112**: 177
Hughes RGM, Jones NS, Robertson IJA, The endoscopic treatment of cerebrospinal fluid rhinorrhoea: the Nottingham experience. *Orig. Art.* **111**: 125
Hughes RGM, Morgan DW, B-cell lymphoma with extensive cutaneous involvement presenting to the ENT surgeon. *Clin. Rec.* **112**: 186
Hughes RGM, Oates J, Capillary haemangioma of the parotid in an adult: an unusual case and a review of the literature. *Clin. Rec.* **111**: 588
Hughes RGM, *see also* Lim PVM *et al.*
Hughes RJ *see* Mason JDT *et al.*
Hui Y *see* Lau SK *et al.*
Huizing EH *see* Lohuis PJFM *et al.*
Hultcrantz E, Johansson K, Bengston H, The effect of uvulopalatopharyngoplasty without tonsillectomy using local anaesthesia: a prospective long-term follow-up. *Orig. Art.* **113**: 542
Humer U *see* Koc C *et al.*; Walch C *et al.*
Humer-Fuchs U *see* Habermann W *et al.*
Hung HY *see* Lin and Hung
Hunt BJ *see* Fairley JW *et al.*
Huppmann A *see* Weber R *et al.*
Hurman D *see* Grant DG *et al.*
Husband A *see* Castelli and Husband
Husband D *see* Jones AS *et al.*
Husby M *see* Svendstrup and Husby
Huson SM *see* Evans DGR *et al.*
Hussain A, Kay N, Tragal cartilage inferior turbinate mucoperiosteal sandwich graft technique for repair of nasal septal perforations. *Orig. Art.* **106**: 893
Hussain A, Lee MSW, Para-incisional tattooing with electrocautery. *Short Comm.* **113**: 244
Hussain A, Murthy P, Modified tragal cartilage — temporoparietal and deep temporal fascia sandwich graft technique for repair of nasal septal perforations. *Orig. Art.* **111**: 435
Hussain A, *see also* Grant DG *et al.*
Hussain SI *see* Muzaffer M *et al.*
Hussain SSM, Conservative treatment in the management of inflammatory aural polyp. *Orig. Art.* **106**: 313
Hussain SSM, Histology of aural polyp as a predictor of middle ear disease activity. *Orig. Art.* **105**: 268
Hussain SSM, Relapsing polychondritis presenting with stridor from bilateral vocal cord palsy. *Clin. Rec.* **105**: 961
Hussain SSM, Hopkinson JM, Mast cells in aural polyps: a preliminary report. *Orig. Art.* **109**: 491
Hussain SSM, Laljee HCK, Horrocks JM, Tec H, Grace ARH, Monitoring of intra-operative visual evoked potentials during functional endoscopic sinus surgery (FESS) under general anaesthesia. *Orig. Art.* **110**: 31
Hussain SSM, Raine CH, Caldicott LD, Wade MJ, An open safety pin in the larynx: a case report. *Clin. Rec.* **108**: 254
Hussain SSM, *see also* Pahor and Hussain; Santana-Hernandez DJ *et al.*; Tay and Hussain

Hussan WU, Keaney NP, Bilateral thoracic empyema complicating adult epiglottitis. *Clin. Rec.* **105**: 858
Huygen PLM *see* Marres HAM *et al.*
Hvala A *see* Zidar N *et al.*
Hwang C-F, Wu C-M, Su C-W, Cheng L, A long-standing cystic lymph node metastasis from occult thyroid carcinoma — report of a case. *Path. Focus* **106**: 932
Hwang C-F, *see also* Su and Hwang; Wu C-M *et al.*
Hyde JAJ *see* Davis and Hyde

Ibrahim D *see* Wake M *et al.*
Ichimiya I *see* Suzuki M *et al.*
Ichimura K, Ohta Y, Tayama N, Surgical management of the plunging ranula: a review of seven cases. *Orig. Art.* **110**: 554
Ichimura K, Tanaka T, Trismus in patients with malignant tumours in the head and neck. *Orig. Art.* **107**: 1017
Idikula J *see* Raman R *et al.*
Igci E *see* Güneri A *et al.*
Ignace Wei W *see* Ming Li X *et al.*
Ii K *see* Li D-J *et al.*
Iida J *see* Kato I *et al.*
Ikeda M, Hiroshige K, Abiko Y, Onoda K, Impaired specific cellular immunity to the varicella-zoster virus in patients with herpes zoster oticus. *Orig. Art.* **110**: 918
Ikeda M, Katsura Y, Tsuru S, Inouye T, Healy GB, AIDS-like disproportion of minor T-cell subsets in Japanese patients with Wegener's granulomatosis. *Orig. Art.* **106**: 133
Ikeda M, Morgernstern C, Immunohistochemical findings of IgG recognised in the planum semilunatum of the Guinea pig. *Orig. Art.* **106**: 93
Ikeda M, Takahashi H, Karaho T, Kitahara S, Inouye T, Amelanotic melanoma metastatic to the epiglottis. *Clin. Rec.* **105**: 776
Ikeda M, Tsuru S, Ohmori T, Kitahara S, Inouye T, Healy GB, CO–N reaction — a new serological activity index — on Wegener's granulomatosis. *Orig. Art.* **107**: 607
Ikeda M, *see also* Kitahara S *et al.*; Takayama E *et al.*; Watanabe Y *et al.*
Ikiz AO *see* Güneri EA *et al.*
Ikuta H *see* Hisa Y *et al.*
Illum P *see* Aggerholm and Illum; Grymer LJ *et al.*; Johansen and Illum; Outzen and Illum
Imakiire T *see* Deguchi K *et al.*
Imamura Y *see* Tsunoda K *et al.*
Inamitsu M, Nakashima T, Uemura T, Immunopathology of olfactory mucosa following injury to the olfactory bulb. *Orig. Art.* **104**: 959
Inbar E *see* Raveh E *et al.*
Indudharan R, Arni T, Myint KK, Jackson N, Lymphoblastic lymphoma/leukaemia presenting as perichondritis of the pinna. *Path. Focus* **112**: 592
Indudharan R, Ashraful Haq J, Use of pre-reduced swabs in bacteriology of chronic suppurative otitis media. *Short Comm.* **110**: 950
Indudharan R, Valuyeetham KA, Kannan T, Sidek DS, Nasopharyngeal carcinoma: clinical trends. *Orig. Art.* **111**: 724
Indudharan R, Win MN, Noor AR, Laryngeal paralysis in organophosphorus poisoning. *Clin. Rec.* **112**: 81
Ingelaere PPC, Simpson RHW, Garth RJN, Metastatic renal cell carcinoma presenting as an aural polyp. *Clin. Rec.* **111**: 1066
Ingels K, Vermeersch H, Verhoye C, De Potter C, Schwannoma of the larynx: a case report. *Path. Focus* **110**: 294
Ingels K, *see also* Ameye F *et al.*
Ingels KJAO *see* Albers and Ingels
van Ingen G, Stel HV, Tiwari RM, Atypical leiomyoma of the choana. *Clin. Rec.* **105**: 1065
Ingle MV *see* Bhattacharyya AK *et al.*; Mankekar G *et al.*; Nayak SR *et al.*
Ingrams D, Burton M, Goodwin A, Graham J, Acute pulmonary oedema complicating laryngospasm. *Clin. Rec.* **111**: 482
Ingrams D, Hein D, Marks N, Laryngocele: an anatomical variant. *Clin. Rec.* **113**: 675
Ingrams D, Walsh RM, JLO Travelling Scholarship Reports **III**: 1094
Ingrams DR, Spraggs PDR, Pringle MB, Croft CB, CO_2 laser palatoplasty: early results. *Orig. Art.* **110**: 754
Ingrams DR, Stafford ND, Creagh TM, Angiolymphoid hyperplasia with eosinophilia. *Path. Focus* **109**: 262
Ingrams DR *see also* McFerran DJ *et al.*
Innes AJ *see* Bath AP *et al.*; Courteney-Harris RG *et al.*; Hosni and Innes; Mitchell TE *et al.*
Inoue H *see* Hisashi K *et al.*
Inouye T *see* Ikeda M *et al.*; Kitahara S *et al.*; Takayama E *et al.*
Iqbal K, Saqulain G, Udaipurwala IH, Ashraf J, Aijaz F, Jalisi M, Cranial fasciitis: presentation as a post-auricular mass. *Clin. Rec.* **109**: 255
Iqbal SM, Murthy JG, Banerjee PK, Vishwanathan KA, Metronidazole ototoxicity — report of two cases. *Clin. Rec.* **113**: 355
Irani B *see* Martin-Hirsch DP *et al.*
Irani BS, Martin-Hirsch D, Lannigan E, Infection of the neck spaces: a present day complication. *Clin. Rec.* **106**: 455
Irani BS, Martin-Hirsch DP, Clark D, Hand DW, Vize CE, Black J, Relapsing polychondritis — a study of four cases. *Clin. Rec.* **106**: 911
Irani BS, *see also* Blair RL *et al.*; Mills RP *et al.*
Irani DK *see* Hathiram BT *et al.*
Iriarte MTG *see* O'Connor Reina C *et al.*
Ironside JW *see* Lane and Ironside
Irvine B *see* Al-Khabori MJJ *et al.*
Irvine BW *see* Natarajan B *et al.*
Irvine BWH *see* Natarajan B *et al.*
Irvine GH *see* McFall MR *et al.*
Irvine MCG, Solomons NB, Atypical supraglottitis caused by *Streptococcus sanguis*. *Clin. Rec.* **104**: 430
Irving RM, The molecular pathology of tumours of the ear and temporal bone. *Mol. Biol.* **112**: 1011
Irving RM, Ford GR, Jones NS, Tuberous sclerosis with primary meningioma of the maxillary antrum. *Clin. Rec.* **105**: 481
Irving RM, Graham JM, Cochlear implantation in superficial siderosis. *Clin. Rec.* **110**: 1151
Irving RM, Jones NS, Bailey CM, Melville J, A guide to the selection of paediatric tracheostomy tubes. *Orig. Art.* **105**: 1046
Irving RM, Jones NS, Hall-Craggs MA, Kendall B, CT and MR imaging in lateral sinus thrombosis. *Rad. Focus* **105**: 693
Irving RM, Parikh A, Coumbe A, Albert DM, Melanotic neuroectodermal tumour of infancy. *Clin. Rec.* **107**: 1045
Irving RM, Richards A, Fisher EW, Pulmonary tuberculosis presenting as suspected foreign body aspiration. *Clin. Rec.* **106**: 453
Irving RM, *see also* Ahmed SK *et al.*; Cook and Irving; Ford GR *et al.*; Mochloulis G *et al.*; Moffat DA *et al.*; Moffat and Irving; Wareing MJ *et al.*
Irwin CJR *see* Slevin NJ *et al.*
Irwin J *see* Vaughan-Jones RH *et al.*
Isaacs S *see* Mortimore S *et al.*
Íseri M *see* Aydin Ö *et al.*
Ishak EA *see* Kamel and Ishak
Ishibashi T, Hojo H, Spindle cell carcinoma of the parotid gland. *Path. Focus* **109**: 683
Ishii T *see* Suzuki Y *et al.*; Yoshihara T *et al.*
Ishikawa M *see* Tsunoda K *et al.*
Ishikawa N, Komatsuzaki A, Tokano H, Meningioma of the internal auditory canal with extension into the vestibule. *Clin. Rec.* **113**: 1101
Ishikawa S *see* Noshimura T *et al.*
Ishimaru T, Miwa T, Nomura M, Iwato M, Furukawa M, Reversible hyposmia caused by intracranial tumour. *Clin. Rec.* **113**: 750
Ishimaru T, Mizuno Y, Shiga H, Nagayama I, Furukawa M, Patient with primary tonsillar and gastric syphilis. *Clin. Rec.* **111**: 766
Ishiyama T *see* Sakaguchi M *et al.*
Ishizaki H *see* Hoshino T *et al.*
Ison K *see* Tolley NS *et al.*
Israel L, Sadigh M, *Candida* epiglottitis in an adult with acquired immunodeficiency syndrome treated with oral fluconazole. *Clin. Rec.* **109**: 337
Ito H, Baba S, Pulsed dye laser lithotripsy of submandibular gland salivary calculus. *Orig. Art.* **110**: 942
Ito S, Tanaka H, Hirano M, Osteoma of the middle ear. *Clin. Rec.* **104**: 803
Itoh K, Nobori T, Fukuda K, Furuta S, Ohyama M, Chondrosarcoma of the hyoid bone. *Clin. Rec.* **107**: 642
Itoh M *see* Takimoto and Itoh; Yoshihara T *et al.*
Iversen PB *see* Holm E *et al.*

Iwasaki S *see* Hoshino T *et al.*; Kaga K *et al.*
Iwasawa H *see* Kato I *et al.*
Iwato M *see* Ishimaru T *et al.*
Izci O *see* Güneri EA *et al.*
Iznaga N *see* Dueñas L *et al.*
Izumo T *see* Kato S *et al.*
Izzat M, Sharma PD, Isolated bilateral paralysis of the soft palate in an adult. *Clin. Rec.* **106**: 839
Izzat S *see* Luff DA *et al.*

Jackson IJB *see* Strachan DR *et al.*
Jackson N *see* Indudharan R *et al.*
Jackson SR, Roland NJ, Clarke RW, Jones AS, Recurrent pleomorphic adenoma. *Orig. Art.* **107**: 546
Jackson SR, *see also* Lancaster JL *et al.*
Jacob A, Ledingham JD, Kerr AIG, Ford MJ, Ulcerative colitis and giant cell arteritis associated with sensorineural deafness. *Clin. Rec.* **104**: 889
Jacobs JB *see* van Veen ED *et al.*
Jacobs JR *see* Lolachi CM *et al.*
Jacobsen SD *see* Christensen and Jacobsen
Jaffe ES *see* Kreel B *et al.*
Jain A *see* Chaudhary N *et al.*
Jalaludin MA, Rajadurai P, Va R, Prasad U, Thyroid metastasis from nasopharyngeal carcinoma: a case report. *Clin. Rec.* **108**: 886
Jalisi M *see* Iqbal K *et al.*
Jalloh S *see* Commins DJ *et al.*
Jamal A, Ebrahim RA, Tammam N, Kanekar S, Wegener's granulomatosis. First case report in Bahrain. *Clin. Rec.* **112**: 664
Jamal MN, Clinical evaluation of nasopharyngeal carcinoma in Jordan. *Orig. Art.* **105**: 432
Jamal MN, Schwannoma of the larynx: case report and review of the literature. *Clin. Rec.* **108**: 788
Jamal MN, *see also* Labadi and Jamal
Jamal TS *see* Daghistani KJ *et al.*
Jambart S *see* Abboud B *et al.*
James AL, O'Malley S, Milford CA, Extracranial internal carotid artery aneurysm in a child: a diagnostic and surgical challenge. *Clin. Rec.* **113**: 373
James EMV *see* Douglas-Jones AG *et al.*
James PL, O'Regan MB, Speight PM, Well-differentiated intra-osseous osteosarcoma in the mandible of a six-year-old child. *Clin. Rec.* **104**: 335
Jan Y-J *see* Jiang R-S *et al.*
Janahi WM, Darwish A, Paulose KO, Al-Khalifa S, Infantile fibromatosis. *Clin. Rec.* **113**: 246
Jang J-W *see* Jiang R-S *et al.*
Jani P, Koltai P, Ochi JW, Bailey CM, Surgical treatment of laryngomalacia. *Orig. Art.* **105**: 1040
Jani P, *see also* Arullendran P *et al.*; Lale AM *et al.*; Mansell NJ *et al.*
Jani PJ *see* Lale AM *et al.*
Jänig U *see* Brademann G *et al.*; Mahnke CG *et al.*
Jankauskas R *see* Sakalinskas and Jankauskas
Jankelowitz GA *see* Srinivasan V *et al.*
Janot F *see* Koka VN *et al.*; Salvan D *et al.*
Janssens de Varebeke S *see* Somers T *et al.*
Janssens M *see* Vos GD *et al.*
Jardine A *see* Mason JDT *et al.*
Jardine AH, Griffiths MV, Midgley E, The acceptance of hearing aids for children with otitis media with effusion. *Orig. Art.* **113**: 314
Jarmulowicz MR *see* Prinsley PR *et al.*
Järund M *see* Ejnell H *et al.*
Jaspan T *see* Conboy PJ *et al.*
Jaspersen D *see* Weber R *et al.*
Jassar P, Murray DP, Lee MSW, The use of toluidine blue gargles to aid the detection of impacted pharyngeal fish bones. *Short Comm.* **113**: 909
Jassar P, Stafford ND, MacDonald AW, Pleomorphic adenoma of the nasal septum. *Path. Focus* **113**: 483
Jawad J, Blayney AW, Spontaneous tonsillar haemorrhage in acute tonsillitis. *Clin. Rec.* **108**: 791
Jawad J, El-Zuebi F, Primary lingual tuberculosis: a case report. *Clin. Rec.* **110**: 177
Jawad J, Lang J, Leader M, Keane T, Extraskeletal myxoid chondrosarcoma of the maxillary sinus. *Clin. Rec.* **105**: 676
Jay S, Ruddy J, Cullen RJ, Laryngectomy: the patient's view. *Orig. Art.* **105**: 934
Jayakumar CR *see* Elango and Jayakumar
Jayakumar KL *see* Cherian T *et al.*
Jayaraj SM, Frosh AC, Abramovich S, Irrigation during temporal bone surgery. *Short Comm.* **113**: 740
Jayaraj SM, Hern JD, Mochloulis G, Porter GC, Malignant melanoma arising in the frontal sinuses. *Clin. Rec.* **111**: 376
Jayaraj SM, Levine T, Frosh AC, Almeyda JS, Ancient schwannoma masquerading as parotid pleomorphic adenoma. *Path. Focus* **111**: 1088
Jayaraj SM, Lloyd J, Frosh AC, Patel KS, Kikuchi-Fujimoto's syndrome masquerading as tuberculosis. *Path. Focus* **113**: 82
Jayaraj SM, *see also* Hern JD *et al.*; Patel SK *et al.*
Jayarajan V, Rangan S, Delayed deterioration of hearing following bacterial meningitis. *Clin. Rec.* **113**: 1011
Jayaram M, Baguley DM, Moffat DA, Speech in noise: a practical test procedure. *Orig. Art.* **106**: 105
Jayaramachandran S *see* Kapur and Jayaramachandran; Kapur and Jayaramchandran
Jeannon J-P, Temporal bones for dissection: a diminishing asset? *Orig. Art.* **110**: 219
Jeannon J-P, *see also* Ho TP *et al.*
Jefferis AF *see* Martinez Devesa P *et al.*; Reddy KTV *et al.*; Thomas DM *et al.*; Vowles RH *et al.*
Jefferis AJ *see* Pringle MB *et al.*
Jekunen AP *see* Ramsay HA *et al.*
Jeleń M *see* Krecicki and Jeleń
Jenkins A *see* Enion DS *et al.*
Jenkins J *see* Osborne J *et al.*
Jennings CR, O'Donoghue GM, Posterior fossa endoscopy. *Edit. Rev.* **112**: 227
Jensen H *see* Bjerregaard B *et al.*
Jentzen JM *see* Gardner PM *et al.*
Jepson RH, Alderson DJ, Clegg RT, Parker AJ, The Jepson whistle: a simple device for laryngectomees. *Short Comm.* **109**: 137
Ješić S *see* Petrović Z *et al.*
Jiang R-S, Liang K-L, Jang J-W, Hsu C-Y, Bacteriology of endoscopically normal maxillary sinuses. *Orig. Art.* **113**: 825
Jiang R-S, Wu C-Y, Jan Y-J, Hsu C-Y, Primary ethmoid sinus craniopharyngioma: a case report. *Path. Focus* **112**: 403
Jimenez JM *see* Solanellas J *et al.*
Jing D *see* Huang H *et al.*
Joachims HZ *see* Catalfumo FJ *et al.*; Danino J *et al.*; Goldenberg D *et al.*; Golz A *et al.*; Hefer T *et al.*; Nir D *et al.*
Job A, Raman R, Medical management of pseudocyst of the auricle. *Clin. Rec.* **106**: 159
Job A, Raman R, Gnanamuthu C, Laryngeal stridor in myasthenia gravis. *Clin. Rec.* **106**: 633
Job A, Venkateswaran S, Mathan M, Krishnaswami H, Raman R, Medical therapy of rhinosporidiosis with dapsone. *Orig. Art.* **107**: 809
Job A, Walter N, David TM, Solitary fibrous tumour of the nasopharynx. *Clin. Rec.* **105**: 213
Job A, *see also* Rupa V *et al.*
Joensuu H, Grenman R, Suonpaa J, Aitasalo K, Puhakka H, Nordman E, Few surgical complications after 5000 to 6500 cGy pre-operative irradiation for carcinoma of the tongue. *Orig. Art.* **106**: 712
Joensuu H, *see also* Atula T *et al.*
Joesner J *see* Hansen LT *et al.*
Johannsen HS *see* Brosch and Johannsen
Johansen ECJ, Illum P, Rhabdomyoma of the larynx: a review of the literature with a summary of previously described cases of rhabdomyoma of the larynx and a report of a new case. *Clin. Rec.* **109**: 147
Johansen M, Overgaard E, Toft A, Severe chronic inflammation of the mucous membranes in the eyes and upper respiratory tract due to work-related exposure to hexavalent chromium. *Clin. Rec.* **108**: 591
Johansson K *see* Hultcrantz E *et al.*
John AB *see* Ga Sze H *et al.*
John DG, Felder CP, The feeding pharyngostomy. *Orig. Art.* **105**: 451
John DG, Porter MJ, van Hasselt CA, Beware bleeding from the ear. *Clin. Rec.* **107**: 137

John DG, Rhys Williams S, Ahuja A, Evans R, To KF, King WWK, van Hasselt CA, Palpation compared with ultrasound in the assessment of malignant cervical lymph nodes. *Orig. Art.* **107**: 821
John DG, *see also* Choy ATK *et al.*; Porter MJ *et al.*; Tang NLS *et al.*
John G *see* Toner JG *et al.*
John H *see* Dutt SN *et al.*
Johns AN *see* Al-Sinawi and Johns
Johnsen NJ *see* Katholm M *et al.*
Johnson AP *see* Babu Manohar M *et al.*; Hogg RP *et al.*; Nigam and Johnson; Wilson PS *et al.*
Johnson IJM, Ravi M, Campbell JB, Renal derived epistaxis. *Clin. Rec.* **107**: 144
Johnson IJM, Soames JV, Birchall JP, Fourth branchial arch fistula. *Clin. Rec.* **110**: 391
Johnson IJM, Soames JV, Marshall HF, Nasal tuberculosis — an increasing problem? *Clin. Rec.* **109**: 326
Johnson IJM, Tadpatrikar MH, Sharp JF, Chondroma of the external auditory canal. *Clin. Rec.* **112**: 278
Johnson IJM, Warfield AT, Smallman LA, Watkinson JC, Primary malignant melanoma of the pharynx. *Path. Focus* **108**: 275
Johnson IJM, *see also* Bateman ND *et al.*; Conboy PJ *et al.*; Hehar SS *et al.*; Homer JJ *et al.*; Prior MJ *et al.*; Sonsale A *et al.*
Johnson JT *see* Fujii H *et al.*
Johnson PJE *see* Al-Fallouji HK *et al.*
Johnson RJ *see* Slevin NJ *et al.*
Johnstone A *see* Natarajan B *et al.*; Palmer O *et al.*
Jokinen K *see* Lilja M *et al.*
Jokinen KE *see* Siniluoto TMJ *et al.*
Jonathan D, Baer S, Cervical osteophytes: their significance in ENT practice (ankylosing vertebral hyperostosis–Forestier's disease). *Orig. Art.* **104**: 236
Jonathan DA *see* Roberts DN *et al.*
Jones AS, Neoplastic chemotherapy and head and neck cancer. *Edit. Rev.* **111**: 607
Jones AS, McRae RD, Phillips DE, Hamilton J, Field JK, Husband D, The treatment of node negative squamous cell carcinoma of the postcricoid region. *Orig. Art.* **109**: 114
Jones AS, Ravi M, Stell PM, The treatment of primary recurrence following laryngectomy for laryngeal carcinoma. *Orig. Art.* **107**: 611
Jones AS, Roland NJ, Caslin AW, Cooke TG, Cooke LD, Forster G: A comparison of cellular proliferation markers in squamous cell carcinoma of the head and neck. *Orig. Art.* **108**: 859
Jones AS, *see also* Ahmed K *et al.*; Clarke and Jones; Clarke RW *et al.*; Flanagan PM *et al.*; Jackson SR *et al.*; Khan MHZ *et al.*; Kinsella AR *et al.*; McCombe and Jones; Nandapalan V *et al.*; Parton M *et al.*; Roland NJ *et al.*; Sherman IW *et al.*; Viani L *et al.*; Wilde AD *et al.*
Jones B *see* East C *et al.*
Jones E, Lund VJ, Howard DJ, Greenberg MP, McCarthy M, Quality of life of patients treated surgically for head and neck cancer. *Orig. Art.* **106**: 238
Jones EL *see* Dhaliwal J *et al.*; Dutt SN *et al.*
Jones JM, Owen GO, Morar P, Spontaneous retropharyngeal haematoma attributable to Epstein-Barr virus infection. *Clin. Rec.* **110**: 1075
Jones K *see* Prior MJ *et al.*; Robson AK *et al.*
Jones N *see* Laskiewicz B *et al.*
Jones NS, Current concepts in the management of paediatric rhinosinusitis. *Rev. Art.* **113**: 1
Jones NS, Principles for correcting the septum in septorhinoplasty: two-point fixation. *Rev. Art.* **113**: 405
Jones NS, Visual evoked potentials in endoscopic and anterior skull base surgery: a review *Rev. Art.* **111**: 513
Jones NS, Carney AS, Davis A, The prevalence of allergic rhinosinusitis: a review. *Rev. Art.* **112**: 1019
Jones NS, Lannigan FJ, Salama NY, Foreign bodies in the throat: a prospective study of 388 cases. *Orig. Art.* **105**: 104
Jones NS, Rog D, Olfaction: a review. *Rev. Art.* **112**: 11
Jones NS, *see also* Bateman and Jones; Beasley and Jones; Beasley NJP *et al.*; Conboy PJ *et al.*; Fergie N *et al.*; Ford GR *et al.*; Hehar and Jones; Hehar SS *et al.*; Homer JJ *et al.*; Homer and Jones; Hughes RGM *et al.*; Irving RM *et al.*; Lloyd and Jones; Lloyd RV *et al.*; Mason JDT *et al.*; Muneer and Jones; Saunders and Jones; Saunders MW *et al.*; Shinkwin CA *et al.*; Simo and Jones; Wansa SA *et al.*
Jones PH *see* Camilleri AE *et al.*; Wheatley AH *et al.*
Jones PW *see* Walsh PM *et al.*
Jones RA *see* Hampal S *et al.*
Jones RL, Chavda SV, Pahor AL, Parapharyngeal abscess secondary to an external auditory meatus foreign body. *Rad. Focus* **111**: 1086
Jones RL, Violaris NS, Chavda SV, Pahor AL, Intracranial complications of sinusitis: the need for aggressive management. *Orig. Art.* **109**: 1061
Jones RL, *see also* Adams WM *et al.*
Jones T *see* Hilger AW *et al.*
Jones TA, Gallow I, Sellars SL, Kranold DH, Sealy GR, Major surgery of oral and oropharyngeal carcinoma. *Orig. Art.* **106**: 127
Jones V *see* Drake-Lee A *et al.*
de Jong D *see* Ceha HM *et al.*
Joosten FBM *see* Marres HAM *et al.*
Jørgensen K *see* Sørensen JA *et al.*
Jørgensen KE *see* Nyrop M *et al.*
Jori J *see* Szilvassy J *et al.*
Jortay A *see* Saussez S *et al.*
Jorysz G *see* Lorenz and Jorysz
Joseph T *see* Spraggs PDR *et al.*
Josephson JS *see* Har-El and Josephson
Joshi K *see* Gupta AK *et al.*
Jouffre V *see* Crevier-Buchman L *et al.*
Journeaux SF, Master B, Greenhalgh RM, Bull TR, Sudden sensorineural hearing loss as a complication of non-otologic surgery. *Clin. Rec.* **104**: 711
Jugpershad Maharaj T *see* Singh B and Jugpershad Maharaj
Julieron M *see* Koka VN *et al.*; Salvan D *et al.*
Juman S, Robinson P, Balkissoon A, Kelly K, B-cell non-Hodgkin's lymphoma of the paranasal sinuses. *Rad. Focus* **108**: 263
Jungehülsing M, Wagner M, Damm M, Turban tumour with involvement of the parotid gland. *Path. Focus* **113**: 779
Jungehülsing M, *see also* Eckel and Jungehülsing
Jurkovič I *see* Böör A *et al.*

Kaberos A *see* Ferekidis E *et al.*; Robinson AC *et al.*
Kaberos AK *see* Balatsouras DG *et al.*
Kacker A, Bahadur S, Singh M, Melanotic neuro-ectodermal tumour of infancy arising from the squamous and occipital bone. *Clin. Rec.* **107**: 843
Kacker A, Komisar A, Kakani RS, Reich E, Rothman L, Tongue paralysis following head trauma. *Clin. Rec.* **109**: 770
Kacker A, Taskin M, Atypical intramuscular lipoma of the tongue. *Path. Focus* **110**: 189
Kacker A, Thaker A, Singh M, Bahadur S, Primary neuroendocrine carcinoma of the skin arising from the post aural region. *Clin. Rec.* **106**: 258
Kaddour H *see* Meehan T *et al.*
Kaddour HS, Recurrent meningitis due to congenital fistula of the stape footplate. *Clin. Rec.* **107**: 931
Kaddour HS, Smelt GJC, Necrotizing fasciitis of the neck. *Clin. Rec.* **106**: 1008
Kaddour HS, Woodhead CJ, Transitional papilloma of the middle ear. *Clin. Rec.* **106**: 628
Kaga K, Iwasaki S, Tamura A, Suzuki J-I, Haebara H, Temporal bone pathology of acoustic neuroma correlating with presence of electrocochleography and absence of auditory brainstem response. *Clin. Rec.* **111**: 967
Kaga K, Ono M, Yakumaru K, Owada M, Mizutani T, Brainstem pathology of infantile Gaucher's disease with only Wave I and II of auditory brainstem response. *Clin. Rec.* **112**: 1069
Kaga K, *see also* Suzuki Y *et al.*
Kahle G *see* Keerl R *et al.*
Kailidou ED *see* Athanassopoulou AC *et al.*
Kairemo KJA *see* Ramsay HA *et al.*
Kaiser C *see* Bernáldez R *et al.*; Moñuz A *et al.*
Kakani RS, Bahadur S, Kumar S, Tandon DA, Parapharyngeal lipoma. *Clin. Rec.* **106**: 279
Kakani RS, *see also* Kacker A *et al.*
Kakkar N *see* Gupta AK *et al.*
Kakoi H *see* Kitamura K *et al.*
Kalach N *see* Gumpert L *et al.*

Kalan A, Kenyon GS, Seemungal TAR, Wedzicha JA, Adverse effects of nasal continuous positive airway pressure therapy in sleep apnoea syndrome. *Orig. Art.* **113**: 888
Kalan A, Tariq M, Harar RPS, Gatland D, Spontaneous internal jugular vein thrombosis and recurrent laryngeal nerve palsy: a rare simultaneous presentation of an occult malignant neoplasm. *Clin. Rec.* **110**: 1166
Kalan A, *see also* Akkielah A *et al.*; Harar RPS *et al.*
Kalderon N *see* Gaitini LA *et al.*
Kale S *see* El Naggar M *et al.*
Kale U, El-Naggar M, Hawthorne M, Verbal auditory agnosia with focal EEG abnormality: an unusual case of a child presenting to an ENT surgeon with 'deafness'. *Clin. Rec.* **109**: 431
Kale US, Raje SG, Wight RG, The management of massive pneumocephalus and cerebrospinal fluid rhinorrhoea as a consequence of biopsy in a patient with inverted papilloma. *Clin. Rec.* **112**: 657
Kalm O *see* Harsten G *et al.*
Kaloterakis AN *see* Kandiloros DC *et al.*
Kamal MF, Samarrai SM, Presentation and epidemiology of nasopharyngeal carcinoma in Jordan. *Orig. Art.* **113**: 422
Kamal SA, Experience with the xylocaine test as a prognostic aid for surgery in Sluder's neuralgia. *Orig. Art.* **109**: 193
Kamal SA, Surgery of tympanosclerosis. *Orig. Art.* **111**: 917
Kamal SA, Othman EO, Diagnosis and treatment of parotid tumours. *Rev. Art.* **111**: 316
Kamal SA, Othman EO, Granular cell tumour of the larynx. *Clin. Rec.* **112**: 83
Kamath B *see* Strachan D *et al.*
Kambič V *see* Zidar N *et al.*
Kamei T *see* Kawashima O *et al.*; Shidara K *et al.*
Kamel R *see* Khalifa MS *et al.*
Kamel RH, Transnasal endoscopic surgery in juvenile nasopharyngeal angiofibroma. *Clin. Rec.* **110**: 962
Kamel RH, Ishak EA, Enlarged adenoid and adenoidectomy in adults: endoscopic approach and histopathological study. *Orig. Art.* **104**: 965
Kameswaran M, Fibre-optic endoscopy in atrophic rhinitis. *Orig. Art.* **105**: 1014
Kameswaran M, Al-Wadei A, Khurana P, Okafor BC, Rhinocerebral aspergillosis. *Orig. Art.* **106**: 981
Kameswaran M, *see also* Sheikha A *et al.*; Soufi HE *et al.*; Thomas R *et al.*
Kameyama T *see* Harada H *et al.*
Kammal MM *see* Saleh EM *et al.*
Kampouridis S *see* Delbrouck C *et al.*
Kan SW *see* Neary WJ *et al.*
Kanaseki T *see* Tanaka Y *et al.*
Kandil TM *see* Khalifa MS *et al.*
Kandiloros D *see* Adamopoulos G *et al.*; Balatsouras DG *et al.*; Ferekidis E *et al.*; Manolis E *et al.*
Kandiloros DC, Nikolopoulos TP, Ferekidis EA, Kaloterakis AN, Adamopoulos GK, Papadimitriou CP: Primary extramedullary plasmacytoma in the middle ear: differential diagnosis and management. *Clin. Rec.* **108**: 868
Kandiloros DC, Nikolopoulos TP, Ferekidis EA, Tsangaroulakis A, Yiotakis JE, Davilis D, Adamopoulos GK, Laryngeal tuberculosis at the end of the 20th century. *Orig. Art.* **111**: 619
Kanekar S *see* Jamal A *et al.*
Kaneko T *see* Nomoto M *et al.*
Kanellopoulou M *see* Manolis E *et al.*
Kangsanarak J, Fooanant S, Ruckphaopunt K, Navacharoen N, Teotrakul S, Extracranial and intracranial complications of suppurative otitis media: report of 102 cases. *Orig. Art.* **107**: 999
Kannan T *see* Indudharan R *et al.*
Kannan V *see* Hasan S *et al.*; Shenoy AM *et al.*
Kansanen M *see* Nuutinen J *et al.*
Kantrowitz AB *see* Feghali and Kantrowitz
Kapadia R *see* Hammerlin and Kapadia
Kapadia RD *see* Hazarika P *et al.*
Kapadia SB *see* Fujii H *et al.*
Kapila K *see* Tandon DA *et al.*
Kaplan HY, Kessler A, Feibel M, Nass D, Tsur H, Nasal bone haemangioma. *Path. Focus* **105**: 389
Kapoor L *see* Lakhia TS *et al.*
Kapoor R *see* Chaudhary N *et al.*
Kapur TR, Causes of failure of combined approach tympanoplasty in the treatment of acquired cholesteatomas of the middle ear and the mastoid. *Orig. Art.* **109**: 710
Kapur TR, The deep oval window. *Orig. Art.* **105**: 721
Kapur TR, The fate of bone grafts in deep oval windows. *Orig. Art.* **105**: 725
Kapur TR, Jayaramachandran S, Long-term results of total ossicular chain reconstruction using autografts. *Orig. Art.* **106**: 688
Kapur TR, Jayaramachandran S, Unusual complication of pharyngeal pouch inversion. *Clin. Rec.* **104**: 344
Karaho T *see* Ikeda M *et al.*
Karam M *see* Goldenberg D *et al.*
Karampekios SK *see* Velegrakis GA *et al.*
Karasalihoglu AR *see* Uzun C *et al.*
Karasen RM *see* Sutbeyaz Y *et al.*
Karaşen RM, Sutbeyaz Y, Gundogdu C, Atkan B, Leiomyosarcoma of the auricle: case report and literature review. *Clin. Rec.* **112**: 166
Karaşen RM, Varoğlu E, Yildirim M, Eryilmaz K, Sütbeyaz Y, Şirin S, Evaluation of Eustachian tube function with ventilation scintigraphy by using Xe-133. *Orig. Art.* **113**: 509
Karaşen RM, *see also* Altas E *et al.*
Kareem BA *see* Elango S *et al.*
Karhuketo TS, Puhakka HJ, Laippala PJ, Tympanoscopy to increase the accuracy of diagnosis in conductive hearing loss. *Orig. Art.* **112**: 154
Karim ABMF *see* Patel P *et al.*
Kariya S, Nishizaki K, Aoji K, Akagi H, Primary malignant lymphoma in the cerebellopontine angle. *Clin. Rec.* **112**: 476
Karjalainen S *see* Vartiainen E *et al.*; Vartiainen and Karjalainen; Virtaniemi J *et al.*
Karkanevatos A, Beasley NJP, Swift AC, Acute non-tuberculous retropharyngeal abscess in an adult — a case report and review of the literature. *Clin. Rec.* **111**: 169
Karkanevatos A, Lesser THJ, Grommet insertion in children: a survey of parental perceptions. *Orig. Art.* **112**: 732
Karlsmose M *see* Højslet PE *et al.*
Karmarkar S *see* Bhatia S *et al.*; Sanna M *et al.*
Karnad D *see* de Souza C *et al.*
Karnad DR *see* de Souza CE *et al.*
Kashiwagi S *see* Harada H *et al.*
Kastanioudakis I, Skevas A, Danielidis V, Tsiakou E, Drosos AA, Moustopoulos MH, Inner ear involvement in rheumatoid arthritis: a prospective clinical study. *Orig. Art.* **109**: 713
Kasuga Y, Nakai A, Matsunaga Y, Toi M, Goto H, Nimura Y, Kurasawa R, Moriyama S-i, Adenocarcinoma of the submandibular gland with positive serum and tissue immunohistochemical staining for both CEA and CA 125: report of a case. *Path. Focus* **108**: 719
Kasumoto K, Miyagi C, Nakashima T, Baba H, Katsuta Y, Papillary and follicular thyroid carcinoma: the treatment results of 357 patients at the National Kyushu Cancer Centre of Japan. *Orig. Art.* **110**: 657
Katariya S *see* Narayana HM *et al.*
Kataura A *see* Ohguro S *et al.*
Katholm M, Johnsen NJ, Siim C, Willumsen L, Bilateral sudden deafness and acute acquired toxoplasmosis. *Clin. Rec.* **105**: 115
Katić V *see* Handžić-Ćuk J *et al.*
Katircioglu OS *see* Süoglu Y *et al.*
Kato L, Uesugi K, Kikuchihara M, Iwasawa H, Iida J, Tsutsumi K, Iwatake H, Takeyama I, Tracheostomy–the horizontal tracheal incision. *Orig. Art.* **104**: 322
Kato S, Sakura M, Takooda S, Sakurai M, Izumo T, Primary non-Hodgkin's lymphoma of the larynx. *Clin. Rec.* **111**: 571
Kato T *see* Harada H *et al.*
Katoh H *see* Nagayama I *et al.*
Katori Y *see* Watanabe K *et al.*
Katsuno S *see* Sakaguchi M *et al.*
Katsura Y *see* Ikeda M *et al.*
Katsuta Y *see* Yasumoto K *et al.*
Katušić D *see* Handžić-Ćuk J *et al.*
Kaur A, Shetty SC, Prasad D, Nirmala V, Primary ectopic meningioma of the palatine tonsil - a case report. *Path. Focus* **111**: 179
Kavečanský V *see* Böör A *et al.*
Kavutcu M *see* Canbolat O *et al.*
Kawahara E *see* Nishimura T *et al.*

Kawaida M, Fukuda H, Kohno N, Multidirectional observations of the larynx using transurethral rigid endoscopes during direct laryngoscopy. *Short Comm.* **112**: 464
Kawashima O, Kamei T, Shimizu Y, Shizuka T, Nakayama M, Malignant mesenchymoma of the larynx. *Path. Focus* **104**: 440
Kawata T *see* Cui P-C *et al.*
Kay N *see* Hussain and Kay
Kazuyama Y *see* Hashiguchi K *et al.*; Ogawa H *et al.*
Keane T *see* Jawad J *et al.*
Keaney NP *see* Hussan and Keaney
Keay DG *see* Barr-Hamilton *et al.*; Barr-Hamilton RM *et al.*
Kedjanyi WK, Bath AP, Ball RY, Hosni AA, Wickstead M, Metastic adenocarcinoma of the temporal bone. *Path. Focus* **108**: 710
Keen CE *see* Daoud A *et al.*
Keen EN *see* Sellars and Keen
Keene MH *see* Evans KL *et al.*
Keerl R, Weber R, Kahle G, Draf W, Constantinidis J, Saha A, Magnetic resonance imaging after frontal sinus surgery with fat obliteration. *Rad. Focus* **109**: 1115
Keerl R, *see also* Weber R *et al.*
Keidan RD, Recurrent laryngeal nerve palsy secondary to massive venous thrombosis. *Clin. Rec.* **107**: 54
Keilmann A, Bergler W, Artzt M, Hörmann K, Vocal function following laser and conventional surgery of small malignant vocal fold tumours. *Orig. Art.* **110**: 1138
Keilmann A, *see also* Hörmann K *et al.*
Keir G *see* Porter MJ *et al.*
Keith AO *see* Dabrowski and Keith; Dutton JEM *et al.*; Pace-Balzan A *et al.*
Keles N *see* Temple RH *et al.*
Kell RA *see* Fergie N *et al.*
Kelly G, Lee P, Nasendoscopically-assisted placement of a nasogastric feeding tube. *Short Comm.* **113**: 839
Kelly G, *see also* Ah-See KW *et al.*
Kelly K *see* Juman S *et al.*
Kelly P *see* Fenton JE *et al.*
Kemink JL *see* Shone G *et al.*
Kemp BL, Batsakis JG, El-Naggar AK, Kotliar SN, Luna MA, Terminal duct adenocarcinomas of the parotid gland. *Path. Focus* **109**: 466
Kemper J, Kuijper EJ, Mirck PGB, Balm AJM, Recovery from rhinocerebral mucormycosis in a ketoacidotic diabetic patient: a case report. *Clin. Rec.* **107**: 233
Kenawi B *see* Rifai and Kenawi
Kendall B *see* Huchzermeyer P *et al.*; Irving RM *et al.*
Kent SE, Rock WP, Nahl SS, Brain DJ, Relationship of nasal septal deformity and palatal symmetry in neonates. *Orig. Art.* **105**: 424
Kent SE, Watson MG, Laryngeal foreign bodies. *Orig. Art.* **104**: 131
Kenyon G *see* Benson-Mitchell R *et al.*; McRae D *et al.*
Kenyon GS *see* Akkielah A *et al.*; Al-Khayat and Kenyon; Al-Khayat M *et al.*; Benson-Mitchell R *et al.*; Dilkes MG *et al.*; Harar RPS *et al.*; Kalan A *et al.*; Morrison GAJ *et al.*; O'Reilly BJ *et al.*; O'Reilly and Kenyon
Keogh P *see* Cassidy M *et al.*
Kerr AG, James Yearsley: Reflections of an otologist. *Orig. Art.* **105**: 249
Kerr AG, *see also* Adams DA *et al.*; Chan YM *et al.*; Kinsella and Kerr; Pereira and Kerr; Tewary AK *et al.*; Toner JG *et al.*
Kerr AIG *see* Jacob A *et al.*; Sharp JF *et al.*
Kerr J *see* Ah-See KW *et al.*
Kerr PD, Dort JC, Primary extramedullary plasmacytoma of the salivary glands. *Clin. Rec.* **105**: 687
Kesse WK, Shehab ZP, Courteney-Harris R, A megalith of the parotid salivary gland. *Clin. Rec.* **112**: 784
Kessler A, Yellin A, Kessler A, Kronenberg J, Use of a metal detector in the location of a swallowed razor blade in the oesophagus. *Clin. Rec.* **104**: 435
Kessler A, *see also* Berenholz LP *et al.*; Kaplan HY *et al.*
Ketenci İ *see* Ünlü Y *et al.*
Keus RB *see* Balm AJM *et al.*; Elias MM *et al.*
Kew J *see* KU PKM *et al.*; Scott PMJ *et al.*
Kfoury H *see* Gangopadhyay K *et al.*
Khalfan Al Abri R *see* Bhargava D *et al.*
Khalid BAK *see* Gendeh BS *et al.*
Khalifa A, El-Guindy A, Erfan F, Stapedectomy for far-advanced otosclerosis. *Orig. Art.* **112**: 158
Khalifa MA *see* Moustafa and Khalifa
Khalifa MCh *see* Abu Shara KA *et al.*
Khalifa MS, Kamel R, Zikry MA, Kandil TM, Effect of enlarged adenoids on arterial blood gases in children. *Orig. Art.* **105**: 436
Khalifa SA *see* Pamaraju N *et al.*
Khambata AS *see* Ajulo SO *et al.*
Khan IA *see* Stringfellow HF *et al.*
Khan JI *see* Montgomery PQ *et al.*
Khan MHZ, Jones AS, Haqqani MT, Angioleiomyoma of the nasal cavity — report of a case and review of the literature. *Clin. Rec.* **108**: 244
Khan NA, McKerrow WS, Palmer TJ, Mucous membrane plasmacytosis of the upper aerodigestive tract, a case report with effective treatment. *Path. Focus* **111**: 293
Khan NA, Shenoy PK, McClymont L, Palmer TJ, Exophthalmos and facial swelling: a case of limited Churg–Strauss syndrome. *Clin. Rec.* **110**: 578
Khan NA, *see also* Murthy P *et al.*
Khan RM *see* Maroof M *et al.*
Khanna S *see* Baser B *et al.*
Khanobthamchai K, Bingham B, Hawke M, Quelprud's nodule: a post-auricular cartilaginous nodule. *Orig. Art.* **104**: 860
Khashaba A, De Donato G, Vassallo G, Landolfi M, Russo A, Taibah A, Sanna M, Benign osteoblastoma of the mastoid part of the temporal bone: case report. *Path. Focus* **109**: 565
Khine MM *see* Roland NJ *et al.*
Khurana P *see* Kameswaran M *et al.*; Thomas R *et al.*
Kieserman SP, Finn DG, Non-Hodgkin's lymphoma of the external auditory canal in an HIV-positive patient. *Clin. Rec.* **109**: 751
Kikuchi T *see* Watanabe K *et al.*
Kikuchihara M *see* Kato I *et al.*
Kim K-S, Kim S-S, Yoon J-H, Han JW, The effect of botulinum toxin type A injection for intrinsic rhinitis. *Orig. Art.* **112**: 248
Kim S-S *see* Kim K-S *et al.*
Kimura H *see* Hosoi H *et al.*; Nakagawa H *et al.*
Kimura Y, Miwa H, Furukawa M, Mizukami Y, Relapsing polychondritis presented as inner ear involvement. *Clin. Rec.* **110**: 154
Kimura Y, Miwa T, Furukawa M, Immunophenotypes of the palatal tonsil lymphocytes in Cowden's disease. *Clin. Rec.* **106**: 640
Kimura Y, Tanaka S, Furukawa M, Angiosarcoma of the nasal cavity. *Clin. Rec.* **106**: 368
Kimura Y, *see also* Tanaka S *et al.*
King TT *see* Baldwin DL *et al.*; Callanan V *et al.*; Evans DGR *et al.*; Huson SM *et al.*
King W *see* Ahuja A *et al.*
King WWK *see* Chow LTC *et al.*; John DG *et al.*
Kingston H *see* Dodds A *et al.*
Kini U *see* Hasan S *et al.*
Kinsella AR, Bowie GL, Field JK, Jones AS, Expression of the cell–cell adhesion molecule E-cadherin in tongue carcinoma cell lines. *Orig. Art.* **108**: 957
Kinsella JB, Kerr AG, Familial stapes superstructure fixation. *Clin. Rec.* **107**: 36
Kiratli H *see* Özyar E *et al.*
Kirham N *see* Athow and Kirham
Kirkland PM, Solomons NB, Ratcliffe NA, Microcystic adnexal carcinoma. *Path. Focus* **111**: 674
Kirkland PM, Tostevin P, A new alternative to the operating microscope in the temporal bone laboratory. *Short Comm.* **111**: 958
Kirtane MV *see* Bhattacharyya AK *et al.*; Mankekar G *et al.*; Nayak SR *et al.*
Kishore K *see* Nehru VI *et al.*
Kiss JG *see* Szilvassy J *et al.*
Kitahara S, Ikeda M, Inouye T, Matsunaga T, Yamaguchi K, Takayama E, Healy GB, Tsukuda M, Inhibition of head and neck metastatic and/or recurrent cancer by local administration of multi-cytokine inducer OK-432. *Orig. Art.* **110**: 449
Kitahara S, Ikeda M, Ohmae Y, Nakanoboh M, Inouye T, Healy GB, Laryngeal closure at the level of the false cord for the treatment of aspiration. *Short Comm.* **107**: 826
Kitahara S, *see also* Ikeda M *et al.*; Takayama E *et al.*

Kitamura K, Miyata M, Wanamaker HH, Silverstein H, Seidman M, Vestibular neurectomy: a histological and clinical study of results. *Orig. Art.* **110**: 211
Kitamura K, Takahashi K, Kakoi H, Sugimoto T, Silverstein H, The morphological and morphometrical study of the peripheral process of the human vestibular nerve following posterior cranial fossa neurectomy. *Orig. Art.* **113**: 967
Kitamura K, *see also* Tamagawa Y *et al.*
Kitaoku S *see* Miyaguchi M *et al.*
Kitslaar PJEHM *see* Meulenbroeks AAWM *et al.*
Klap P *see* Ayache D *et al.*
Kleinsasser O, Revision of classification of laryngeal cancer, is it long overdue? *Orig. Art.* **106**: 197
Klemi P-J *see* Atula T *et al.*
Klijanienko J, Vielh P, Duvillard P, Luboinski B, True carcinosarcoma of the larynx. *Clin. Rec.* **106**: 58
Klima A, Bergmann I, Szepezi S, Multimodality treatment in stage IV squamous cell carcinoma of the head and neck. A long-term follow-up. *Orig. Art.* **106**: 234
Klokker M *see* Stangerup S-E *et al.*
Klossek JM, Dubreuil L, Richet H, Richet B, Beutter P, Bacteriology of chronic purulent secretions in chronic rhinosinusitis. *Orig. Art.* **112**: 1162
Klossek JM, Dubreuil L, Richet H, Richet B, Sedallian A, Beutter P, Bacteriology of the adult middle meatus. *Orig. Art.* **110**: 847
Klumpp TR, Mohr RM, Silverman CL, Tang C-K, Elfenbein IB, Dardick I, Malignant myoepithelioma of the parotid gland: case report and review of the literature. *Clin. Rec.* **109**: 995
Knappe MV, Gregor RT, Luc's abscess - a rare complication of middle ear infection. *Clin. Rec.* **111**: 461
Knight C *see* Mayall FG *et al.*
Knowles CH *see* Dilkes MG *et al.*
Knowles JEA, Inhalation of dental plates–a hazard of radiolucent materials. *Clin. Rec.* **105**: 681
Koay B, Bates G, Elston J, Endoscopic orbital decompression for dysthyroid eye disease. *Orig. Art.* **111**: 946
Koay B, *see also* Mckiernan DC *et al.*
Koay CB, Commins D, Bates GJ, The role of endoscopic stapling diverticulotomy in recurrent pharyngeal pouch. *Short Comm.* **112**: 954
Koay CB, Freeland AP, Athanasou NA, Chondromyxoid fibroma of the nasal bone with extension into the frontal and ethmoidal sinuses. *Path. Focus* **109**: 258
Koay CB, Herdman RCD, Nasendoscopy guided removal of fish bones from the base of tongue and the vallecula. *Short Comm.* **109**: 534
Koay CB, Heyworth T, Burden P, Lemierre syndrome — a forgotten complication of acute tonsillitis. *Clin. Rec.* **109**: 657
Koay CB, Norval C, An unusual presentation of an unusual complication of infectious mononucleosis: haematemesis and melaena. *Clin. Rec.* **109**: 335
Koay CB, Whittet HB, Ryan RM, Lewis CE, Giant cell reparative granuloma of the concha bullosa. *Clin. Rec.* **109**: 555
Koay CB, *see also* Lee SJ *et al.*
Kobayashi S *see* Wang Q *et al.*
Koc C, Luxenberger W, Humer U, Friedrich G, Bilateral ventricular neurofibroma of the larynx. *Clin. Rec.* **110**: 385
Kocer I *see* Altas E *et al.*
Kochar AS *see* Ferreiro and Kochar
Kochhar S *see* Chandra Jha B *et al.*
Kodama A *see* Shimizu and Kodama
Kohno N *see* Kawaida M *et al.*
Kojima H *see* Shiwa M *et al.*
Kojima M *see* Muraoka H *et al.*
Koka V, Vericel R, Lartigau E, Lusinchi A, Schwaab G, Sarcomas of nasal cavity and paranasal sinuses: chondrosarcoma, osteosarcoma and fibrosarcoma. *Orig. Art.* **108**: 947
Koka VN, Deo R, Lusinchi A, Roland J, Schwaab G, Osteoradionecrosis of the mandible: Study of 104 cases treated by hemimandibulectomy. *Orig. Art.* **104**: 305
Koka VN, Julieron M, Bourhis J, Janot F, Le Ridant AM, Marandas P, Luboinski B, Schwaab G, Aesthesioneuroblastoma. *Orig. Art.* **112**: 628
Koka VN, Veber F, Haguet J-F, Rachinel O, Freche C, Liguory-Brunaud M-D, Chondrosarcoma of the larynx. *Path. Focus* **109**: 168
Koka VN, *see also* Marmuse JP *et al.*
Kokkinis K *see* Goumas P *et al.*
Köksal H *see* Yildiz K *et al.*
Koltai P *see* Jani P *et al.*
Komatsuzaki A *see* Haraguchi H *et al.*; Ishikawa N *et al.*; Muraoka H *et al.*; Noguchi Y *et al.*; Tsunoda A *et al.*; Tsutsumi and Komatsuzaki; Tsutsumi T *et al.*; Yamada M *et al.*
Komisar A *see* Kacker A *et al.*
Komiyama S *see* Hisashi K *et al.*; Nakashima T *et al.*
Komorowski RA *see* Gardner PM *et al.*
Komune S *see* Hisashi K *et al.*
Kong N *see* Gendeh BS *et al.*
Kong Sang Woo J *see* Chi Fai Tong M *et al.*
Kong XT *see* Huang H *et al.*
Konno A *see* Nomoto M *et al.*
Kosaki H, Nakamura N, Toriyama Y, Penetrating injuries to the oropharynx. *Orig. Art.* **106**: 813
Kosmidis P *see* Nikolaou A *et al.*
Kotecha B *see* Morrison GAJ *et al.*
Koten M *see* Uzun C *et al.*
Kothari P, Bartella L, Carter J, Chan O, Piper K, Tuberculosis of the mandible in a child. *Clin. Rec.* **112**: 585
Kotliar SN *see* Kemp BL *et al.*
Kotoulas G *see* Vlahos L *et al.*
Kouloulas A *see* Nikolaou A *et al.*
Koutsoubi KG *see* Velegrakis GA *et al.*
Kovačić M *see* Skitarelić N *et al.*
Kovanlikaya A *see* Guneri A *et al.*
Koyunchu M *see* O'Donoghue and Koyunchu
Koyuncu M, Mason SM, Shinkwin C, Effect of hearing loss in electrocochleographic investigation of endolymphatic hydrops using tone-pip and click stimuli. *Orig. Art.* **108**: 125
Krajcár R *see* Böör *et al.*
Krajina Z, Vertical partial laryngectomy on demand. *Orig. Art.* **104**: 879
Kranold DH *see* Jones TA *et al.*
Kraus M, Fliss DM, Argov S, Leiberman A, Benharroch D, Burkitt's lymphoma of the tonsil. *Clin. Rec.* **104**: 991
Krause CJ *see* Talmi YP *et al.*
Krebs A *see* Maier W *et al.*
Kręcicki T, Jeleń N, Proliferating cell nuclear antigen in laryngeal cancer. *Path. Foc.* **112**: 310
Kręcicki T, Kukieńczuk T, Zalesska-Kręcicka M, Balcerzak W, Acute bilateral vocal fold paresis as a symptom of benign thyroid disease. *Clin. Rec.* **108**: 433
Kręcicki T, Leluk M, Acute phase reactant proteins — an aid to monitoring surgical treatment of laryngeal carcinoma. *Orig. Art.* **106**: 613
Kreel B, Rubin JS, Jaffe ES, Pseudolymphoma of the parapharyngeal space. *Clin. Rec.* **105**: 137
Krejović B *see* Petrović Z *et al.*
Krengli M *see* Pisani P *et al.*
Krishnaswami H *see* Job A *et al.*; Rupa V *et al.*
Kristensen S, Spontaneous healing of traumatic tympanic membrane perforations in man: a century of experience. *Orig. Art.* **106**: 1037
Kristensen S, *see also* Hansen LT *et al.*
Kristo A *see* Alho O-P *et al.*
Kronenberg J, Bendet E, Findler G, Roth Y, Cerebrospinal fluid (CSF) otorhinorrhoea following vestibular schwannoma surgery treated by extended subtotal petrosectomy with obliteration. *Orig. Art.* **107**: 1122
Kronenberg J, *see also* Cinamon U *et al.*; Kessler A *et al.*; Talmi YP *et al.*
Kruger J *see* Thorp MA *et al.*
Ku PKM, Kew J, van Hasselt CA, Paranasal sinus enlargement in Sturge–Weber syndrome. *Rad. Focus* **113**: 177
Ku PKM, Tong MCF, Leung CY, Pak MW, van Hasselt CA, Nasal manifestation of extranodal Rosai–Dorfman disease — diagnosis and management. *Path. Focus* **113**: 275
Ku PKM, *see also* Pak MW *et al.*
Kubba H, How uncomfortable are the various positions recommended for the instillation of nose drops? *Orig. Art.* **113**: 326
Kubo T *see* Miyaguchi M *et al.*
Kuga M *see* Watanabe Y *et al.*
Kuhn FA *see* Halvorson and Kuhn
Kuijper EJ *see* Kemper J *et al.*
Kujala V, Pirilä T, Niinimäki A, Reijula K, Latex-induced allergic rhinitis in a laboratory nurse. *Clin. Rec.* **109**: 1094
Kukieńczuk T *see* Kręcicki T *et al.*

Kukimoto N *see* Watanabe Y *et al.*
Külahli I, Öztürk M, Bilen Ç, Cüreoglu S, Merhametsiz A, Çagil N, Evaluation of hearing loss with auditory brainstem responses, early/late period, bacterial meningitis in children. *Orig. Art.* **111**: 223
Kulapaditharom B *see* Kunachak S *et al.*
Kulkarni P *see* Goel S *et al.*
Kumar BN, Walsh RM, Courteney-Harris RG, Laryngeal foreign body: unusual complication of percutaneous tracheostomy. *Clin. Rec.* **111**: 652
Kumar BN, Walsh RM, Courteney-Harris RG, Wilson PS, Treatment of chronic otitis externa by laser. *Orig. Art.* **111**: 1126
Kumar BN, Walsh RM, Sinha A, Courteney-Harris RG, Carlin WV, Benign necrotizing osteitis of the external auditory meatus. *Clin. Rec.* **111**: 269
Kumar BN, Walsh RM, Walter NM, Tse A, Little JT, Intraparotid facial nerve schwannoma in a child. *Clin. Rec.* **110**: 1169
Kumar BN, Walsh RM, Wilson PS, Carlin WV, Sensorineural hearing loss and ulcerative colitis. *Clin. Rec.* **111**: 277
Kumar BN, *see also* Cocks HC *et al.*; Walsh RM *et al.*
Kumar BU, Naisby G, Flood LM, Acquired involution of the maxillary antrum. *Rad. Focus* **108**: 74
Kumar BU *see also* Dingle AF *et al.*; Hampal S *et al.*
Kumar EV *see* Thomas R *et al.*
Kumar M *see* Wittig FJ *et al.*
Kumar P *see* Shenoy AM *et al.*
Kumar RV *see* Bhargava AK *et al.*; Shenoy AM *et al.*
Kumar S *see* Bahadur S *et al.*; Kakani RS *et al.*
Kumar U *see* Rashad U *et al.*
Kumoi T *see* Minatogawa T *et al.*
Kumta SM *see* Chow LTC *et al.*
Kun Lam L *see* Ming Li X *et al.*
Kunachak S, Anterior cervical pain syndromes: hyoid, thyroid and cricoid cartilage syndromes and their treatment with triamcinolone acetonide. *Orig. Art.* **109**: 49
Kunachak S, Sithisarn P, Kulapaditharom B, Are laryngeal papilloma virus-infected cells viable in the plume derived from a continuous mode carbon dioxide laser, and are they infectious? A preliminary report on one laser mode. *Orig. Art.* **110**: 1031
Kunt T, Ozturkcan S, Egilmez R, Cholesterol granuloma of the maxillary sinus: six cases from the same region. *Clin. Rec.* **112**: 65
Kuo M *see* Zeitoun H *et al.*
Kuo MJ, Drago PC, Proops DW, Chavda SV, Early diagnosis and treatment of Ramsay Hunt syndrome: the role of magnetic resonance imaging. *Rad. Focus* **109**: 777
Kuo MJ, Reid AP, Smith JE, Unilateral nasal obstruction: an unusual presentation of a complication of nasotracheal intubation. *Clin. Rec.* **108**: 991
Kuo MJ, Warfield AT, Nye KJ, Crocker J, Invasive candidiasis of the tonsil. *Path. Focus* **111**: 1199
Kuo MJ *see also* Al-Fallouji HK *et al.*; Hogg RP *et al.*
Kupferberg A *see* Ostfeld and Kupferberg
Kurane I *see* Takasaki T *et al.*
Kurasawa R *see* Kasuga Y *et al.*
Kurien M, Anandi V, Raman R, Brahmadathan KN, Maxillary sinus fusariosis in immunocompetent hosts. *Clin. Rec.* **106**: 733
Kurien M, Seshadri MS, Zachariah A, Inherited degenerative chondropathy — an autosomal dominant new clinical entity: report of two cases and follow-up of four cases. *Clin. Rec.* **109**: 433
Kurien M, *see also* Varghese G *et al.*
Kurt A-M *see* Quinodoz D *et al.*
Kurtulmaz SY, Erkal HS, Serin M, Elhan AH, Çakmak A, Squamous cell carcinoma of the head and neck: descriptive analysis of 1293 cases. *Orig. Art.* **111**: 531
Kusakari J *see* Hara A *et al.*
Kusukawa J *see* Harada H *et al.*
Kutluhan A *see* Ünlü Y *et al.*
Kuwayama N *see* Nakagawa H *et al.*
Kuze S *see* Ohashi N *et al.*
Kwan CYW *see* Leong HK *et al.*
Kwan S *see* Lau SK *et al.*
Kwong DLW *see* Nicholls JM *et al.*
Kwong Fah K, Tan HKK, An unusual cause of stridor in a neonate. *Clin. Rec.* **108**: 63
La Rosa FC *see* Mannarà GM *et al.*
Laakso M *see* Virtaniemi J *et al.*
van der Laan BFAM, Baris G, Gregor RT, Hilgers EJM, Balm AJM, Radiation-induced tumours of the head and neck. *Onc. Focus* **109**: 346
Labadi MH, Jamal MN, Leeches in the larynx. *Clin. Rec.* **111**: 980
Labella-Caballero T *see* López-Amado M *et al.*
Laccourreye H *see* Laccourreye O *et al.*
Laccourreye O, Bely N, Crevier-Buchman L, Brasnu D, Halimi P, Computerized tomography of the glottis after intracordal autologous fat injection. *Clin. Rec.* **112**: 971
Laccourreye O, Chabardes E, Weinstein G, Carnot F, Brasnu D, Laccourreye H, Synchronous arytenoid and pancreatic neuroendocrine carcinoma. *Clin. Rec.* **105**: 373
Laccourreye O, Crevier-Buchman L, Le Pimpec-Barthes F, Garcia D, Riquet M, Brasnu D, Recovery of function after intracordal fat injection for unilateral recurrent laryngeal nerve paralysis. *Clin. Rec.* **112**: 1082
Laccourreye O, Merite-Drancy A, Chabardes E, Carnot F, Renard P, Donnadieu S, Brasnu D, Implantation metastasis following percutaneous endoscopic gastrostomy. *Clin. Rec.* **107**: 946
Laccourreye O, *see also* Crevier-Buchman L *et al.*
Lacey NK *see* Sparkes and Lacey
Lacy PD, Alderson DJ, Parker AJ, Late congenital syphilis of the larynx and pharynx presenting at endotracheal intubation. *Clin. Rec.* **108**: 688
Lacy PD, Donnelly MJ, McGrath JP, Byrne PJ, Hennessy TPJ, Timon CVI, Acute food bolus impaction: aetiology and management. *Orig. Art.* **111**: 1158
Lacy PD, Fenton JE, Smyth DA, Colreavy MP, Walsh MA, O'Dwyer TP, Timon CVI, The Westaby T-Y tracheobronchial stent in otolaryngology. *Orig. Art.* **113**: 652
Lacy PD, Timon CI, Ryan CD, Donnelly MP, McShane DP, Migrating foreign body: a new cause of trismus. *Clin. Rec.* **109**: 990
Van Laer C, Hamans E, Neetens I, Van Marck E, Van Oosterom A, Van de Heyning P, Benign fibrous histiocytoma of the larynx: presentation of a case and review of the literature. *Clin. Rec.* **110**: 474
Laforga JB, Vierna J, Adenoma of thyroid gland containing fat (thyrolipoma). Report of a case. *Path. Focus* **110**: 1088
Lagerholm S, Harsten G, Emgård P, Olsson B, Laser-turbinectomy: long-term results. *Orig. Art.* **113**: 529
Lai M-T, Ohmichi T, Yuen K, Egusa K, Yorizane S, Masude V, Superficial siderosis of the central nervous system: a case with an unruptured intracranial aneurysm. *Clin. Rec.* **109**: 549
Laing MR, Albert DM, Quiney RE, Bailey CM, Tracheal stenosis in infants and young children. *Orig. Art.* **104**: 229
Laing MR, *see also* Murthy and Laing; Neilly IJ *et al.*
Laing RBS, Wardrop PJC, Welsby PD, Brettle RP, Stridor in patients with HIV infection. *Clin. Rec.* **109**: 1197
Laippala P *see* Atula T *et al.*
Laippala PJ *see* Karhuketo TS *et al.*
Laitt RD *see* Lobo CJ *et al.*
Lakhia TS, Shah RB, Kapoor L, Fracture of the hyoid bone. *Clin. Rec.* **105**: 232
Lal H *see* Garg LN *et al.*
Lala M *see* Sanghvi V *et al.*
Laldina HC *see* Tandon DA *et al.*
Lale AM, Jani P, Coleman N, Ellis PDM, A palatal haemangioma in a child. *Clin. Rec.* **112**: 677
Lale AM, Jani PJ, Ellis PDM, An unusual complication of chemotherapy: an abscess in the pterygopalatine fossa. *Clin. Rec.* **112**: 296
Laljee HCK *see* Hussain SSM *et al.*
Lali GS, Walsh RM, Rowlands DC, Donaldson I, Schwannoma (neurilemmoma) of the tonsil. *Path. Focus* **113**: 585
Lallemant JG, Bonnin P, El-Sioufi I, Bousquet J, Cricohyoepiglottopexy: long-term results in 55 patients. *Orig. Art.* **113**: 532
Lam LK *see* Yuen APW *et al.*
Lam S *see* Harries MLL *et al.*
Lamb WT *see* Wareing MJ *et al.*
Lamballe P *see* Murty GE *et al.*
Lamey PJ *see* Thompson and Lamey
Lammi A *see* Harrison and Lammi
Lamont D *see* Simpson D *et al.*

Lancaster, JL, Alderson DJ, Sherman IW, Clark AH, Papillary endothelial hyperplasia (Masson's tumour) of the maxillary sinus. *Path. Focus* **112**: 500
Lancaster JL, Hanafi Z, Jackson SR, Adult presentation of a tracheoesophageal fistula with co-existing laryngeal cleft. *Clin. Rec.* **113**: 469
Lancaster JL, Makura ZGG, Porter G, McCormick M, Paediatric tympanoplasty. *Orig. Art.* **113**: 628
Lancaster JL, Makura ZGG, Porter G, McCormick M, Topical aminoglycosides in the management of active mucosal chronic suppurative otitis media. *Orig. Art.* **113**: 10
Lance GN *see* Maw AR *et al.*
Landolfi M *see* Naguib MB *et al.*; Sanna M *et al.*; *see* Chashaba A *et al.*
Lane S, Ironside JW, Extra-skeletal Ewing's sarcoma of the nasal fossa. *Clin. Rec.* **104**: 570
Läng H *see* Zbären P *et al.*
Lang J *see* Jawad J *et al.*
Lang S *see* Millar EKA *et al.*
Langman G *see* Thorp MA *et al.*
Lannigan E *see* Irani BS *et al.*
Lannigan F *see* Martin-Hirsch DP *et al.*
Lannigan FJ, O'Higgins P, McPhie P, The cellular mechanism of ossicular erosion in chronic suppurative otitis media. *Orig. Art.* **107**: 12
Lannigan FJ, *see also* Alderson and Lannigan; Daoud A *et al.*; Jones NS *et al.*; Martin-Hirsch DP *et al.*; Martin-Hirsch and Lannigan; Meehan T *et al.*
Lanza J, Wooh K, Goldberg S, Har-El G, Malignant head and neck germ cell tumours. *Clin. Rec.* **106**: 268
Laoide-Kemp SN *see* Neary WJ *et al.*
Lappin DWP *see* Green KMJ *et al.*
Larkin G *see* Lund VJ *et al.*
Larsen P *see* Franzmann M-B *et al.*
Larsen PL *see* Hald and Larsen
Larsson SG *see* Gangopadhyay K *et al.*
Lartigau E *see* Koka V *et al.*
Lascaratos J, Otorhinolaryngological diseases in Byzantium (AD 324-1453): unknown information from non-medical literary resources. *Hist. Art.* **110**: 913
Lascaratos J, Poulacou-Rebelacou E, Yiotakis J, Otolaryngological treatments in hagiographical Byzantine texts (324-1453A.D.): miracles or reality? *Hist. Art.* **112**: 25
Laskiewicz B, Chalstrey S, Gatland DJ, Jones N, Michaels L, Congenital cholesteatoma. *Orig. Art.* **105**: 995
Laszig R, Sollmann WP, Marangos N, The restoration of hearing in neurofibromatosis type 2. *Orig. Art.* **109**: 385
Laszig R, *see also* Maier W *et al.*
Lau DPC, Goddard MJ, Bottrill ID, Moffat DA, Epithelial-myoepithelial carcinoma of the parotid gland: an unusual cause of ear canal stenosis. *Path. Focus* **110**: 493
Lau DPC, Wharton SB, Antoun NM, Bottrill ID, Moffat DA, Chondrosarcoma of the petrous apex. Dilemmas in diagnosis and treatment. *Clin. Rec.* **111**: 368
Lau DPC, *see also* Sethi DS *et al.*
Lau SK, Kwan S, Lee J, Wei WI, Source of tubercle bacilli in cervical lymph node: A prospective study. *Orig. Art.* **105**: 558
Lau SK, Wei WI, Sham JST, Choy DTK, Hui Y, Early changes of auditory brain stem evoked response after radiotherapy for nasopharyngeal carcinoma — a prospective study. *Orig. Art.* **106**: 887
Lau SK, Wei WL, Hsu C, Engzell UCG, Efficacy of fine needle aspiration cytology in the diagnosis of tuberculous cervical lymphadenopathy. *Orig. Art.* **104**: 24
Lau T *see* Tos M *et al.*
Laubert A *see* Maier W *et al.*
Lauerma H, Paalassalo P, The need for excessive dietary sodium chloride following tympanoplasty. *Clin. Rec.* **109**: 324
Laufer D *see* Hefer T *et al.*
Laufer L *see* Puterman M *et al.*
Launspach JL *see* Graham SM *et al.*
Laurenson RD, Crown Prince Frederick of Prussia: Suez and syphilis. Un canard dévoilé. *Hist. Art.* **109**: 479
Laurenson RD, The Emperor who smoked a pipe. *Hist. Art.* **109**: 1
Lautala P *see* Niemelä M *et al.*
Lavery KM *see* Anwar R *et al.*
Lavrenčak B *see* Šmid L *et al.*
Law K *see* Riley DN *et al.*
Law S, Watters GWR, Penetrating oral foreign body presenting as an aural polyp. *Clin. Rec.* **111**: 749
Lazar RH *see* Mitchell RB *et al.*
Lazarus CR *see* Watkinson JC *et al.*
Le Cleche G *see* Godey B *et al.*
Le Gall F *see* Godey B *et al.*
Le Pimpec-Barthes, F *see* Laccourreye O *et al.*
Le Ridant AM *see* Koka VN *et al.*
Leader M *see* Al-Sader MH *et al.*; Cassidy M *et al.*; Jawad J *et al.*
Learmonth GM *see* Fagan JJ *et al.*
Leder L-D *see* Metz KA *et al.*
Ledingham JD *see* Jacob A *et al.*
Lee AHS, Ramsay AD, Cartilaginous metaplasia of the epiglottis. *Clin. Rec.* **104**: 903
Lee CA *see* Alusi GH *et al.*
Lee D-H *see* Cho J-H *et al.*
Lee D-J *see* Welsh J *et al.*
Lee D *see* Sabin SL *et al.*
Lee DG *see* Hong KH *et al.*
Lee HY *see* Yen PT *et al.*
Lee J *see* Lau SK *et al.*
Lee JA *see* Linton K *et al.*
Lee KC, Chan JKC, Chong YW, Ossifying pleomorphic adenoma of the maxillary antrum. *Clin. Rec.* **106**: 50
Lee MSW *see* Hussain and Lee; Jassar P *et al.*
Lee N-S *see* Cho J-H *et al.*
Lee P *see* Kelly and Lee
Lee PVC, Drysdale AJ, Tuberculous otitis media: a difficult diagnosis. *Clin. Rec.* **107**: 339
Lee R-C *see* Wang C-P *et al.*
Lee RJ *see* Bandason and Lee
Lee SJ, Koay CB, Thompson H, Nicolaides AR, Das Gupta AR, Adenocarcinoma arising in an oesophageal colonic interposition graft. *Path. Focus* **108**: 80
Lee STS, Anterior nasal stenosis from joss stick burns. *Clin. Rec.* **104**: 497
Lee STS, Niimi S, Vocal fold sulcus. *Orig. Art.* **104**: 876
Lee WC, Recurrent frontal sinusitis complicating orbital decompression in Graves' disease. *Clin. Rec.* **110**: 670
Lee WC, Duignan MC, Walsh RM, McRae-Moore JR, An audit of prophylactic antibiotic treatment following tonsillectomy in children. *Aud. Art.* **110**: 357
Lee WC, Manjaly G, Skinner DW, O'Neill PM, Cowpox infection of the nose. *Clin. Rec.* **110**: 782
Lee WC, Sharp JF, Bing–Neel syndrome or malignant external otitis in Waldenstrom's macroglobulinaemia? *Clin. Rec.* **108**: 492
Lee WC, Sharp JF, Complications of paediatric tonsillectomy post-discharge. *Orig. Art.* **110**: 136
Lee WC, Skinner DW, Prichard AJN, Complications of palatoplasty for snoring or sleep apnoea. *Orig. Art.* **111**: 1151
Lee WC, Walsh RM, Anaplastic thyroid carcinoma presenting as a pharyngeal mass with ball-valve type obstruction of the larynx. *Clin. Rec.* **110**: 1078
Lee WC, Walsh RM, Tse A, Squamous cell carcinoma of the pharynx and larynx presenting as a neck abscess or cellulitis. *Clin. Rec.* **110**: 893
Lee WC, Weiner GM, Campbell JB, Should nasopharyngeal biopsy be mandatory in adult unilateral glue ear? *Clin. Rec.* **110**: 62
Lee WC, *see also* Ahmed SK *et al.*
Leemans CR, Balm AJM, Gregor RT, Hilgers FJM, Management of carotid artery exposure with pectoralis major myofascial flap transfer and split thickness skin coverage. *Orig. Art.* **109**: 1176
Leen EJ *see* Walsh RM *et al.*
van Leeuwen JPPM, Cremers CWRJ, Thijssen HOM, Meyer HE, Unchanged unilateral hearing loss and ipsilateral growth of an acoustic neuroma from 1 to 4 cm. *Clin. Rec.* **107**: 230
van Leeuwen JPPM, Pruszczynski M, Marres HAM, Grotenhuis JA, Cremers CWRJ, Unilateral hearing loss due to a rhabdomyoma in a six-year-old child. *Clin. Rec.* **109**: 1186
Lefantzis D, Triantos S, Vontetsianos H, Dokianakis G, An unusual case of otogenic pneumocephalus. *Clin. Rec.* **112**: 1179
Lefrancq T *see* Benlyazid A *et al.*
Legakis NJ *see* Manolis E *et al.*
Lehmann W *see* Zbaeren P *et al.*

Lehnhardt E, Neuro-axonal recruitment: A result of selective compression. *Orig. Art.* **104**: 185
Leiba S *see* Cohen O *et al.*
Leiberman A *see* Goldenberg D *et al.*; Kraus M *et al.*
Leibermann A, Tovi F, Barki Y, Alkan M, Salmonella neck abscess associated with jugular vein thrombosis. *Clin. Rec.* **105**: 966
Leighton S *see* Whittet HW *et al.*
Leighton SEJ, Rees GL, McDonald B, Alun-Jones T, Metastatic meningioma in the neck. *Clin. Rec.* **105**: 229
Leighton SEJ, Whittet HB, Golding S, Freeland AP, Styloid apparatus anomaly causing dysphagia. *Clin. Rec.* **105**: 964
Leighton SEJ, *see also* Burton MJ *et al.*; Connolly AAP *et al.*; Papsin BC *et al.*; Rowe-Jones JM *et al.*; Rowe-Jones and Leighton
Leinonen ASS *see* Siniluoto TMJ *et al.*
Leluk M *see* Kręcicki and Leluk
Lennox P, Hern J, Birchall M, Lund V, Local anaesthesia in flexible nasendoscopy – a comparison between cocaine and cophenylcaine. *Orig. Art.* **110**: 540
Lennox P, *see also* Harcourt JP *et al.*
Lennox PA, Harries M, Lund VJ, Howard DJ, A retrospective study of the role of the argon laser in the management of epistaxis secondary to hereditary haemorrhagic telangiectasia. *Orig. Art.* **111**: 34
Lensky Y *see* Rakover Y *et al.*
Leone O *see* Tesei F *et al.*
Leong HK, The future of stapedectomy — the Singapore problem. *Aud. Art.* **109**: 225
Leong HK, Chong PV, Sinniah R, Temporal bone chondroblastoma: big and small. *Path. Focus* **108**: 1115
Leong HK, Kwan CYW, Stanley RE, Tow S, Malignant mesenchymoma of the retropharyngeal space. *Clin. Rec.* **107**: 1165
Leong J-L, Fong K-W, Low W-K, Factors contributing to delayed diagnosis in nasopharyngeal carcinoma. *Orig. Art.* **113**: 633
Leopold PW *see* Ohri AK *et al.*
Leović D *see* Danić D *et al.*
Leraci A *see* Galli J *et al.*
Leridant AM *see* Salvan D *et al.*
Lescanne E *see* Benlyazid A *et al.*
Lesser TH *see* Roland NJ *et al.*
Lesser THJ, Al-Jassim AHH, Day case surgery in otolaryngology: the setting up and first year of a freestanding unit. *Orig. Art.* **108**: 406
Lesser THJ, Dort JC, Simmen DPB, Ear, nose and throat manifestations of Lyme disease. *Orig. Art.* **104**: 301
Lesser THJ, Pollak A, Acoustic schwannoma of traumatic origin? A temporal bone study. *Path. Focus* **104**: 270
Lesser THJ, *see also* Karkanevatos and Lesser; Morrison D *et al.*; Nandapalan V *et al.*
Leung CY *see* Ku PKM *et al.*
Leung G *see* Shek TWH *et al.*
Leung SF *see* Ahuja A *et al.*; Porter MJ *et al.*
Levi H *see* Feinmesser M *et al.*
Levine T *see* Jayaraj SM *et al.*
Levy I, Barki Y, Tovi F, Giant cervical cyst: presenting symptom of an occult thyroid carcinoma. *Clin. Rec.* **105**: 863
Levy R *see* Shpitzer T *et al.*
Lewin I *see* Drake-Lee A *et al.*
Lewis C, Resouly A, Is a community-based mastoid microsuction service feasible?: the audit of a pilot project. *Aud. Art.* **109**: 971
Lewis CE *see* Koay CB *et al.*
Lewis FA *see* Nunez DA *et al.*
Lewis H *see* Pace-Balzan A *et al.*
Li D-J, Ohsaki K, Ii K, Ye Q, Nobuto Y, Tenshin S, Takano-Yamamoto T, Long-term observation of subcutaneous tissue reaction to synthetic auditory ossicle (Apaceram) in rats. *Orig. Art.* **111**: 702
Li G-D, Mu L, Yang S, Acoustic evaluation of Isshiki type III thyroplasty for treatment of mutational voice disorders. *Orig. Art.* **113**: 31
Li K *see* Cui P-C *et al.*
Li V, The relationship between SIgA and chronic granular pharyngitis. *Orig. Art.* **107**: 532
Li X, Rare cavernous haemangioma of the hypopharynx with numerous phleboliths. *Clin. Rec.* **104**: 262
Li Z *see* Huang H *et al.*
Liang K-L *see* Jiang R-S *et al.*
Liddington MI, Harrison RF, Booth AP, Das Gupta AR, Radiation-induced antrochoanal fibrosarcoma. *Clin. Rec.* **106**: 547
Liesnard C *see* Van Vooren JP *et al.*
Liew SH *see* Menown IBA *et al.*
Lightfoot GR, Hughes JB, Bone conduction errors at high frequencies: implications for clinical and medico-legal practice. *Orig. Art.* **107**: 305
Liguory-Brunaud M-D *see* Koka VN *et al.*
Lilja M, Räisänen S, Jokinen K, Stenfors L-E, Direct microscopy of effusion obtained from peritonsillar abscesses as a complement to bacterial culturing. *Path. Focus* **111**: 392
Lilja M, Räisänen S, Stenfors L-E, Immunoglobulin- and complement-coated bacteria in pus from peritonsillar abscesses. *Orig. Art.* **112**: 634
Lim DP *see* Good CD *et al.*
Lim JC, Hadfield PJ, Ghiacy S, Bleach NR, Medial orbital protrusion — a potentially hazardous anomaly during endoscopic sinus surgery. *Clin. Rec.* **113**: 754
Lim PVH, Curry AR, A new method for evaluating and reporting the severity of snoring. *Orig. Art.* **113**: 336
Lim PVH, Mason JDT, Walker D, Gibbin KP, Epistaxis, von Willebrand's type bleeding diathesis and Wilms' tumour: a case report. *Clin. Rec.* **108**: 1081
Lim PVM, Hughes RGM, Oates J, Hypersensitive allergic reactions to bismuht-iodoform-paraffin paste following ear surgery. *Orig. Art.* **112**: 335
Lim TA *see* Low WK *et al.*
Limb D *see* Ell SR *et al.*
Lin C-H, Chou J-C, Lin T-L, Lou P-J, Spontaneous resolution of internal jugular vein thrombosis in a salmonella neck abscess patient. *Clin. Rec.* **113**: 1122
Lin C-H, *see also* Wu C-M *et al.*
Lin J *see* Guo Y *et al.*
Lin T-L *see* Lin C-H *et al.*
Lin WS, Hung HY, Transnasal endoscopic surgery of sphenoid sinus aspergillosis. *Clin. Rec.* **107**: 837
Lindbichler F *see* Habermann W *et al.*
Lindeberg, H *see* Petersen BL *et al.*
Lindeman P *see* Ejnell H *et al.*
Linder A, Hamartoma of the larynx causing neonatal respiratory distress. *Clin. Rec.* **111**: 166
Linder A, Lindholm C-E, Vocal fold lateralisation using carbon dioxide laser and fibrin glue. *Orig. Art.* **106**: 226
Lindholm C-E *see* Linder and Lindholm
Lindsey LA, Hopper I, Temporal bone dissection using a low cost miniature electric drill. *Short Comm.* **107**: 721
Lindup WE *see* Vreeburg GCM *et al.*
Ling SY *see* Loh and Ling
Linthicum FH *see* Hajjaj and Linthicum
Linton K, Bath AP, Lee JA, Tonsillar metastasis from malignant pulmonary carcinoid tumour. *Clin. Rec.* **112**: 581
Lipitz S *see* Golan-Porat N *et al.*
Lipovsky MM *see* Lohuis PJFM *et al.*
Little JT *see* Kumar BN *et al.*
Little P, Bridges A, Guragain R, Friedman D, Prasad R, Weir N, Hearing impairment and ear pathology in Nepal. *Orig. Art.* **107**: 395
Liu C-M, Su C-Y, Post-operative pain control with topical steroid injection after hot dissection tonsillectomy. *Orig. Art.* **110**: 1038
Liu X, Newton V, Read A, Hearing loss and pigmentary disturbances in Waardenburg syndrome with reference to WS Type II. *Orig. Art.* **109**: 96
Liu X, Xu L, Zhang S, Xu Y, Prevalence and aetiology of profound deafness in the general population of Sichuan, China. *Orig. Art.* **107**: 990
Livesey J *see* Watson MG *et al.*
Livesey JR, Are haematological tests warranted prior to tonsillectomy? *Orig. Art.* **107**: 205
Livesey JR, V Soames JV, Cystic lymphangioma in the adult parotid. *Path. Focus* **106**: 566
Livesey JR, *see also* Solomons and Livesey
Livni N *see* Feinmesser R *et al.*
Lixiang Z, Zhanling T, Mingquan B, Application of the external perichondrium of the ala of the thyroid cartilage of the non-diseased side in laryngeal surgery. *Short Comm.* **108**: 770

Liziang Z, Xiuyun W, Histological examination of the auricular cartilage and pseudocyst of the auricle. *Orig. Art.* **106**: 103
Llavero MT *see* Raboso E *et al.*
Llorente JL, Suárez C, Seco M, Garcia A, Leiomyoma of the nasal septum: report of a case and review of the literature. *Clin. Rec.* **110**: 65
Lloyd G, Howard D, Phelps P, Cheesman A, Juvenile angiofibroma: the lessons of 20 years of modern imaging. *Orig. Art.* **113**: 127
Lloyd GAS, CT of the paranasal sinuses: study of a control series in relation to endoscopic sinus surgery. *Orig. Art.* **104**: 477
Lloyd GAS, Barker PB, Subtraction magnetic resonance for tumours of the skull base and sinuses: a new imaging technique. *Orig. Art.* **105**: 628
Lloyd GAS, Lund VJ, Scadding GK, CT of the paranasal sinuses and functional endoscopic surgery: a critical analysis of 100 symptomatic patients. *Orig. Art.* **105**: 181
Lloyd GAS, *see also* Goligher and Lloyd; Roberts DN *et al.*; Tolley NS *et al.*
Lloyd J *see* Jayaraj SM *et al.*
Lloyd RV, Jones NS, Paradoxical vocal fold movement: a case report. *Clin. Rec.* **109**: 1105
Lloyd RV, O'Flynn PE, Jones NS, Access to the traumatized vertebral artery: an unusual approach. *Clin. Rec.* **113**: 76
Lloyd RV *see also* van Eeden S *et al.*
Lo WWM *see* Frau GN *et al.*
Lobo CJ, Hartley C, Farrington WT, Closure of the nasal vestibule in atrophic rhinitis: a new non-surgical technique. *Orig. Art.* **112**: 543
Lobo CJ, Mehan R, Murugasu E, Laitt RD: Tinnitus as the presenting symptom in a case of Lhermitte–Duclos disease. *Clin. Rec.* **113**: 464
Lobo CJ, Timms MS, Puranik VC, Basal cell carcinoma of the external auditory canal and Gorlin–Goltz syndrome: a case report. *Clin. Rec.* **111**: 850
Lobo, VJ *see* Ray J *et al.*
Lödén B *see* Theander C *et al.*
Löfgren B *see* Harsten G *et al.*
Loftus BM *see* Dijkstra MD *et al.*
Loftus WK *see* Scott PMJ *et al.*
Loftus-Coll B *see* Gregor and Loftus-Coll
Logani KB *see* Bais AS *et al.*
Logue JP, Banerjee SS, Slevin NJ, Vasanthan S, Neuroendocrine carcinomas of the larynx. *Orig. Art.* **105**: 1031
Loh FC, Ling SY, Acute osteomyelitis of the maxilla in the newborn. *Clin. Rec.* **107**: 627
Lohela P *see* Tikkakoski T *et al.*
Lohuis, PJFM, Lipovsky MM, Hoepelman AIM, Hordijk GJ, Huizing EH, *Leishmania braziliensis* presenting as a granulomatous lesion of the nasal septum mucosa. *Clin. Rec.* **111**: 973
Lokman S, Sani A, Sidek DS, Pyopneumothorax — a rare sequelae of retropharyngeal abscess. *Clin. Rec.* **107**: 460
Lolachi CM, Madan SK, Jacobs JR, Ameloblastic carcinoma of the maxilla. *Path. Focus* **109**: 1019
Lomas DA *see* Barnes and Lomas
Lombardo F *see* Franco V *et al.*
Loney E *see* Harcourt JP *et al.*
Lonsdale RJ *see* Osinubi OA *et al.*
López Aguado D *see* Campos A *et al.*
López Amado M, García-Caballero T, Lozano-Ramirez A, Labella-Caballero T, Human papillomavirus and p53 oncoprotein in verrucous carcinoma of the larynx. *Orig. Art.* **110**: 742
López Amado M, Lorenzo Patiño MJ, López Blanco G, Arnal Monreal F, Giant primary amyloidoma of the tonsil. *Path. Focus* **110**: 613
López Amado M, *see also* Sarandeses-García A *et al.*; Yebra Pimental M *et al.*
López Blanco G *see* López Amado M *et al.*
Lopez JI, Perez A, Pharyngeal adenocarcinoma with intestinal features. *Clin. Rec.* **104**: 900
Lopez JI, *see also* Elizalde JM *et al.*; Eréno C *et al.*
Lopez MJS *see* De la C Mera A *et al.*
López Villarejo P *see* Navarro Cunchillos M *et al.*
López-Lacomba D *see* Solanellas J *et al.*
López-Rubio F *see* Navarro Cunchillos M *et al.*
López-Saura P *see* Dueñas L *et al.*
Lorente J *see* Navarette ML *et al.*
Lorenz R, Jorysz G, The globus syndrome: value of flexible endoscopy of the upper gastrointestinal tract. *Orig. Art.* **107**: 535
Lorenzo Patiño MJ *see* López Amado M *et al.*
Løtveit T *see* Boysen M *et al.*
Lou P-J *see* Lin C-H *et al.*; Young and Lou
Loughran S, McKee G, Carding P, Tracheo-oesophageal puncture by retrograde passage of a gastroscope via minilaparotomy and gastrotomy. *Clin. Rec.* **113**: 564
Louis N, Hanly M, Davidson NMcD, Kikuchi-Fujimoto disease: a report of two cases and an overview. *Clin. Rec.* **108**: 1001
Low C *see* Blair RL *et al.*
Low W-K *see* Leong J-L *et al.*
Low WK, Enhancing hearing preservation in endoscopic-assisted excision of acoustic neuroma via the retrosigmoid approach. *Orig. Art.* **113**: 973
Low WK, Middle ear pressures in patients with nasopharyngeal carcinoma and their clinical significance. *Orig. Art.* **109**: 390
Low WK, Fenton JE, Fagan PA, Gibson WPR, The influence of race on the position of the jugular bulb. *Orig. Art.* **109**: 610
Low WK, Fong KW, Hearing disability before and after radiotherapy for nasopharyngeal carcinoma. *Orig. Art.* **110**: 121
Low WK, Goh YH, Uncommon otological manifestations of nasopharyngeal carcinoma. *Clin. Rec.* **113**: 558
Low WK, Lim TA, Fan YF, Balakrishnan A, Pathogenesis of middle ear effusion in nasopharyngeal carcinoma: a new perspective. *Orig. Art.* **111**: 431
Low WK, Sng I, Balakrishnan A, Palatine tonsillar metastasis from carcinoma of the colon. *Path. Focus* **108**: 449
Low WK *see also* Hong Y *et al.*
Lowe DG *see* Evans KL *et al.*
Lowe J *see* Hughes RGM *et al.*
Lozano-Ramirez A *see* López-Amado M *et al.*
Lozupone E *see* Roberto M *et al.*
Lu S-J, Chang S-Y, Shiao G-M, Comparison between short-term and long-term post-operative evaluation of sleep apnoea after uvulopalatopharyngoplasty. *Orig. Art.* **109**: 308
Luangpitakchumpol P *see* Vaewvichit and Luangpitakchumpol
Luboinski B *see* Klijanienko J *et al.*; Koka VN *et al.*; Salvan D *et al.*
Ludman H *see* Andaz C *et al.*
Luff DA, Izzat S, Farrington WT, Viscoaugmentation as a treatment for leakage around the Provox 2 voice rehabilitation system. *Clin. Rec.* **113**: 847
Luff DA, *see also* Morris DP *et al.*
Lun Sham C *see* Chi Fai Tong M *et al.*
Luna MA *see* Carrillo R *et al.*; Cho KJ *et al.*; El-Naggar AK *et al.*; Kemp BL *et al.*
Lund V *see* Lennox P *et al.*
Lund VJ, Endoscopic management of paranasal sinus mucocoeles. *Orig. Art.* **112**: 36
Lund VJ, Extended applications of endoscopic sinus surgery - the territorial imperative. *Edit. Rev.* **111**: 313
Lund VJ, Holmstrom M, Scadding GK, Functional endoscopic sinus surgery in the management of chronic rhinosinusitis. *Orig. Art.* **105**: 832
Lund VJ, Howard DJ, Closure of the nasal cavities in the treatment of refractory hereditary haemorrhagic telangiectasia. *Orig. Art.* **111**: 30
Lund VJ, Howard DJ, Head and neck cancer in the young: A prognostic conundrum? *Orig. Art.* **104**: 544
Lund VJ, Larkin G, Fells P, Adams G, Orbital decompression for thyroid eye disease: a comparison of external and endoscopic techniques. *Orig. Art.* **111**: 1051
Lund VJ, Milroy CM, Fronto-ethmoidal mucocoeles: a histopathological analysis. *Orig. Art.* **105**: 921
Lund VJ, Scadding GK, Objective assessment of endoscopic sinus surgery in the management of chronic rhinosinusitis: an update. *Orig. Art.* **108**: 749
Lund VJ, *see also* Badia and Lund; Bhattacharyya and Lund; Fisher EW *et al.*; Golding-Wood DG *et al.*; Howard and Lund; Jones E *et al.*; Lennox PA *et al.*; Lloyd GAS *et al.*; Milford CA *et al.*; Scadding GK *et al.*; Whittet HB *et al.*
Lund WS *see* Burton and Lund; Burton MJ *et al.*
Lundell C *see* Woolford TJ *et al.*
Lundgreen J *see* Hellquist and Lundgreen
Luntz M, Bentacur TM, Sadé J, Tripod allograft in reconstruction of incudal lesions. *Orig. Art.* **108**: 206

Luntz M, Fuchs C, Sadé J, Correlation between retractions of the pars flaccida and the pars tensa. *Orig. Art.* **111**: 322
Luntz M, Sadé J, Value of middle ear inflation as a diagnostic indicator of Eustachian tube patency. *Short Comm.* **104**: 134
Luotonen J *see* Alho O-P *et al.*
Luotonen JP *see* Siniluoto TMJ *et al.*
Lupovitch A, Salama D, Batmanghelichi O, Benign hamartomatous polyp of the palatine tonsil. *Path. Focus* **107**: 1074
Lusinchi A *see* Koka V *et al.*; Koka VN *et al.*
Lutman ME *see* Coles RRA *et al.*
Luxenberger W *see* Koc C *et al.*
Luxford WM *see* Frau GN *et al.*; Ramsay and Luxford
Luxon L *see* Prasher D *et al.*
Luxon LM, Medical management of vertigo. *Edit. Rev.* **111**: 1114
Luxon LM, *see also* Mahoney and Luxon; Phelps PD *et al.*; Vyse T *et al.*
Lye R *see* Evans DGR *et al.*; Huson SM *et al.*
Lye RH *see* Ahmmed AU *et al.*; Birzgalis AR *et al.*; Curley JWA *et al.*; Dutton JEM *et al.*; Evans DGR *et al.*; Hinton AE *et al.*; Neary WJ *et al.*; Ramsden RT *et al.*; Saeed SR *et al.*
Lynch C *see* Graham J *et al.*; Gray RF *et al.*
Lynch CA *see* Rudd MJ *et al.*
Lynnerup N *see* Homøe P *et al.*
Lyons TJ *see* Hartley C *et al.*

Ma D *see* Cai Z *et al.*; Huang H *et al.*
Ma ZZ *see* Yue WL *et al.*
Maas S, Bance M, O'Driscoll M, Mawman D, Ramsden RT, Explantation of a nucleus multichannel cochlear implant and re-implantation into the contralateral ear. *Clin. Rec.* **110**: 881
Macaden R *see* Raju KGS *et al.*
Macallan DC *see* Rowe-Jones JM *et al.*
McAllister RMR, Rutty GN, Hancock K, Sanders R, Cavernous haemangioma of the nasal bones. *Clin. Rec.* **106**: 264
McArthur P *see* Babu Manohar M *et al.*
McArthur PD *see* Gangopadhyay K *et al.*; Rayappa CS *et al.*; Saleem M *et al.*
Macartney JC *see* Hickey SA *et al.*
MacAulay C *see* Harries MLL *et al.*
McBride G *see* Riley DN *et al.*
McBride GB *see* McCluggage WG *et al.*
McBride P, Photographs of a case of rapid destruction of the nose and face. *Clin. Rec.* **105**: 1120
McBrien F, Spraggs PDR, Harcourt JP, Croft CB, Abductor vocal fold palsy in the Shy–Drager syndrome presenting with snoring and sleep apnoea. *Clin. Rec.* **110**: 681
McCallum HM *see* Barr GD *et al.*
McCarthy M *see* Jones E *et al.*
McCarthy SW *see* Harrison HC *et al.*
Macchi A *see* Ferrario F *et al.*
McCloskey B *see* Riley N *et al.*
McCluggage WG, Cameron CHS, Brooker D, O'Hara MD, Paraganglioma: an unusual tumour of the parathyroid gland. *Path. Focus* **110**: 196
McCluggage WG, McBride GB, Primrose WJ, Cullan J, McNaboe EJ, Bharucha H, Fannin T, Giant cell tumour of the temporal bone presenting as vertigo. *Clin. Rec.* **109**: 538
McCluggage WG, McManus D, Maxwell P, Walsh MY, T-cell-rich histiocyte-rich B-cell lymphoma of parotid gland. *Path. Focus* **110**: 811
McClymont L *see* Khan NA *et al.*; Nilssen ELK *et al.*
McClymont LG, Browning GG, Beta adrenoceptors in human nasal mucosa. *Orig. Art.* **105**: 632
McClymont LG, Browning GG, Characterization of severely and profoundly hearing impaired adults attending an audiology clinic. *Orig. Art.* **105**: 534
McClymont LG, *see also* Murthy P *et al.*
McCombe A, Stell PM, Emergency laryngectomy. *Orig. Art.* **105**: 463
McCombe A, Williamson P, Hawke M, Clinical photographs as teaching aids: how reliable are they? *Orig. Art.* **109**: 741
McCombe A, *see also* Hellier and McCombe
McCombe AW, Binnington J, Davis A, Spencer H, Hearing loss and motorcyclists. *Orig. Art.* **109**: 599
McCombe AW, Jones AS, Radiotherapy and complications of laryngectomy. *Orig. Art.* **107**: 130
McCombe AW, Phillips DE, Rogers JH, Inter-arytenoid glottic bar following intubation. *Clin. Rec.* **104**: 727
McCombe AW, *see also* Dammeijer and McCombe; Gibson and McCombe; Richardson and McCombe
McConkey CC *see* Rockley TR *et al.*
McCormick M *see* Lancaster JL *et al.*
McCormick MS *see* Ahmed and McCormick; Viani and McCormick
McCulloch TM *see* Graham SM *et al.*
McCullough DE *see* Wake M *et al.*; Wake and McCullough
McDermott ID, Watters GWR, Metastatic papillary thyroid carcinoma presenting as a typical branchial cyst. *Clin. Rec.* **110**: 490
MacDonald A *see* Coatesworth AP *et al.*
MacDonald AW *see* Jassar P *et al.*
McDonald B *see* Leighton SEJ *et al.*
Macdonald F *see* Stopps and Macdonald
McDonald PJ *see* Scott PMJ *et al.*
McDonogh M *see* Wormald and McDonogh
MacDougall G, Denholm SW, Audit of the treatment of tonsillar and peritonsillar sepsis in an ear, nose and throat unit. *Aud. Art.* **109**: 531
MacDougall G, Sanderson RJ, Altered dental sensation following intranasal surgery. *Orig. Art.* **107**: 1011
McElveen Jr JT, Wilkins RH, Erwin AC, Wolford RD, Modifying the translabyrinthine approach to preserve hearing during acoustic tumour surgery. *Clin. Rec.* **105**: 34
McElveen JT *see* Moffat DA *et al.*
McEwan J *see* Thomas KM *et al.*
McEwan JA, Dhingra J, Rowe-Jones J, Bleach NR, Parapharyngeal abscess: a rare complication of elective tonsillectomy. *Clin. Rec.* **111**: 578
McEwen J *see* Dhingra JK *et al.*
McFall MR, Irvine GH, Eveson JW, Adenoid cystic carcinoma of the sublingual salivary gland in a 16-year-old female; report of a case and review of the literature. *Clin. Rec.* **111**: 485
McFarlane HW *see* Soussi AC *et al.*
McFerran DJ, Abdullah V, Gallimore AP, Pringle MB, Croft CB, Vocal process granulomata. *Orig. Art.* **108**: 216
McFerran DJ, Edmonds SE, The use of balloon catheters in the treatment of epistaxis. *Orig. Art.* **107**: 197
McFerran DJ, Ingrams DR, Gallimore AP, Grant HR, Polycystic disease of salivary glands. *Path. Focus* **109**: 165
McFerran DJ, *see also* Brewis and McFerran; Gray RF *et al.*; Moffat DA *et al.*
McGarry GQ, Nasal endoscope in posterior epistaxis: A preliminary evaluation. *Orig. Art.* **105**: 428
McGarry GW, Mackenzie K, Second primary tumours of the larynx following bronchial carcinoma. *Orig. Art.* **104**: 629
McGibbon DH *see* Wareing MJ *et al.*
McGill F *see* Rubin JS *et al.*
McGilligan JA *see* Dilkes MG *et al.*
McGlashan J, Rees G, Bowdler DA, Solitary keratoacanthoma of the nasal vestibule. *Clin. Rec.* **105**: 306
McGlashan JA, Walsh R, Daoud A, Vowles A, Gleeson MJ, A comparative study of calcium sodium alginate (Kaltostat®) and bismuth tribromophenate (Xeroform®) packing in the management of epistaxis. *Orig. Art.* **106**: 1067
McGlashan JA, *see also* Daoud A *et al.*; Hollis LJ *et al.*; Pracy JPM *et al.*
McGlone B *see* Deegan PC *et al.*
McGrath JP *see* Lacy PD *et al.*
MacGregor, F *see* Haider-Ali AM *et al.*
MacGregor FB, Roberts DN, Howard DJ, Phelps PD, Vocal fold palsy: a re-evaluation of investigations. *Rev. Art.* **108**: 193
MacGregor FB, *see also* Espinoza FI *et al.*; Mehanna and MacGregor; Sharp JF *et al.*
McGuiness RJ *see* Murray A *et al.*
Machet M-C *see* Martin L *et al.*
McIlwain JC *see* Flanagan and McIlwain; Nandapalan and McIlwain; Nandapalan V *et al.*; Wen QH *et al.*
MacIver D *see* Chowdhury CR *et al.*
Mackay AA *see* Spencer and Mackay
Mackay I *see* Rowe-Jones J *et al.*
Mackay IS *see* Cumberworth VL *et al.*; Milford CA *et al.*; Premachandra DJ *et al.*; Quinn SJ *et al.*; Sharp HR *et al.*
Mackay LS *see* O'Flynn PE *et al.*
McKee G *see* Loughran S *et al.*
McKelvie P *see* Dilkes MG *et al.*
McKenna DM *see* Farrell RWR *et al.*

Mackenzie I *see* Ahmmed AU *et al.*
MacKenzie K, Browning GG, Randomised cross over study to assess patient preference for an acoustically modified hearing aid system. *Orig. Art.* **105**: 405
MacKenzie K, *see also* Ah-See KW *et al.*; Camilleri and MacKenzie; Connolly and MacKenzie; McGarry and Mackenzie; Nicol JW *et al.*
McKerrow WS *see* Blair and McKerrow; Blair RL *et al.*; Khan NA *et al.*; Murthy and Mckerrow
McKiernan DC, Koay B, Vinayak B, Gould S, Freeland AP, A case of submandibular teratoma. *Clin. Rec.* **109**: 992
McKiernan DC, Watters GWR, Smooth muscle tumours of the larynx. *Path. Focus* **109**: 77
Mackle E *see* Riley N *et al.*
Macklin CP *see* Santana-Hernandez DJ *et al.*
McLaren K *see* Ah-See KW *et al.*; Molony NC *et al.*; Sharp JF *et al.*
McLellan DR *see* Banerjee AMS *et al.*
McLemore D *see* El-Naggar AK *et al.*
Maclennan AC *see* White PS *et al.*
Maclennan KA *see* Davis JP *et al.*
Macleod TI *see* Blanshard JD *et al.*
MacLeod TIF *see* Watson DJ *et al.*
McManus D *see* McCluggage WG *et al.*
McManus TC *see* Fisher and McManus
McMenamin M *see* Pollock AM *et al.*
McNaboe EJ *see* McCluggage WG *et al.*; Toner JG *et al.*
Macnamara M, Pope S, Sadler A, Grant H, Brough M, Microvascular free flaps in head and neck surgery. *Orig. Art.* **108**: 962
Macnamara M, *see also* Spraggs PDR *et al.*; Zeitoun H *et al.*
McNeela BJ *see* Ravikumar A *et al.*
McNeill J *see* Riley N *et al.*
McNeish IA *see* Green and McNeish
McNicholas WT *see* Deegan PC *et al.*
McPartlin DW *see* Patel SK *et al.*
McPhie P *see* Lannigan FJ *et al.*
McQueen CT, Baxter A, Smith TL, Raynor E, Yoon SM, Prazma J, Pillsbury HC, Non-insulin dependent diabetic microangiopathy in the inner ear. *Orig. Art.* **113**: 13
McRae A *see* Garth RJN *et al.*
McRae D, Dilkes M, Kenyon G, The Pope wick as a myringoplasty ear canal dressing. *Orig. Art.* **106**: 327
McRae RD *see* Jones AS *et al.*
McRae RDR *see* Chevretton EB *et al.*; Rajenderkumar D *et al.*
McRae-Moore JR *see* Lee WC *et al.*
Macrobert AJ *see* Grant WE *et al.*
McShane D *see* Conlon B *et al.*; Curran AJ *et al.*; Rowley H *et al.*
McShane DP *see* Donnelly MJ *et al.*; Fenton JE *et al.*; Gaffney RJ *et al.*; Koyuncu M *et al.*; Lacy PD *et al.*; Russell JD *et al.*; Smyth DA *et al.*
Madan SK *see* Lolachi CM *et al.*
Madden GJ *see* Sirimanna KS *et al.*
Magallon R *see* Regueiro CA *et al.*
Magennis JP *see* Capper R *et al.*
Magliulo G, Petti R, Vingolo GM, Cristofari P, Ronzoni R, Facial nerve monitoring in skull base surgery. *Orig. Art.* **108**: 557
Magliulo G, Ronzoni R, Cristofari P, Medial meatal fibrosis: current approach. *Orig. Art.* **110**: 417
Magliulo G, Vingolo GM, Petti R, Natale AS, Vestibular neurectomy by the infralabyrinthine approach. *Orig. Art.* **106**: 780
Magliulo G, Zardo F, Intra-operative facial nerve monitoring. Its predictive value after skull base surgery. *Orig. Art.* **111**: 715
Magnay AR, Debelle G, Proops DW, Munchausen syndrome by proxy unmasked by nasal signs. *Clin. Rec.* **108**: 336
Magri D *see* Barzan L *et al.*
Maguire AJ *see* Gaffney RJ *et al.*
Mahadeva U *see* Hollis LJ *et al.*
Mahanupab P *see* Cho KJ *et al.*
Maharaj D, Rajah V, Hemsley S, Management of peritonsillar abscess. *Orig. Art.* **105**: 743
Maharaj TJ *see* Singh B *et al.*; Singh and Maharaj
Maharaj TPJ *see* Singh B *et al.*
Mahasin ZZ, Saleem M, Gangopadhyay K, Transverse sinus thrombosis and venous infarction of the brain following unilateral radical neck dissection. *Clin. Rec.* **112**: 88
Mahasin ZZ, *see also* Gangopadhyay K *et al.*
Maher M *see* Cassidy M *et al.*
Maheshwar A *see* Cuddihy PJ *et al.*
Mahnke CG, Jänig U, Werner JA, Metastasizing malignant oncocytoma of the submandibular gland. *Path Foc.* **112**: 106
Mahoney CFO, Luxon LM, Misdiagnosis of hearing loss due to ear canal collapse: a report of two cases. *Clin. Rec.* **110**: 561
Mahoney CFO, *see also* Phelps PD *et al.*
Mahoney CO *see* Bamiou DE *et al.*
Mai R *see* Heaton JM *et al.*
Maier W, Hauser R, Munker G, Eustachian tube function in sudden hearing loss and in healthy subjects. *Orig. Art.* **106**: 322
Maier W, Henne K, Krebs A, Schipper J, Endoscopic ultrasound-guided brachytherapy of head and neck tumours. A new procedure for controlled application. *Orig. Art.* **113**: 41
Maier W, Laubert A, Weinel P, Acute bilateral blindness in childhood caused by rhabdomyosarcoma and malignant lymphoma. *Clin. Rec.* **108**: 873
Maier W, Marangos N, Laszig R, Paraganglioma as a systemic syndrome: pitfalls and strategies. *Orig. Art.* **113**: 978
Maillard A *see* Deguine L *et al.*
Main J *see* Hern JD *et al.*
Mains BT *see* Murty GE *et al.*
Maione A *see* Barzan L *et al.*
Mairs AP, Stewart TJ, Surgical treatment of glossopharyngeal neuralgia via the pharyngeal approach. *Orig. Art.* **104**: 12
Maisey MN *see* Davis JP *et al.*; Watkinson JC *et al.*
Mak HKF *see* Pak MW *et al.*
Mak-Kregar S, Mooi WJ, Balm AJM, Hilgers FJM, Squamous cell carcinoma of the tonsillar region and the base of the tongue: a morphological and immunohistochemical comparative pilot study. *Orig. Art.* **107**: 1129
Makhdoum MJA, Snik AFM, van den Broek P, Cochlear implantation: a review of the literature and the Nijmegan results. *Rev. Art.* **111**: 1008
Makimoto K *see* Sakakura A *et al.*; Yamamoto Y *et al.*
Makins R *see* Ohri AK *et al.*
Makura ZGG, Nigam A, The clunking neck. *Clin. Rec.* **109**: 1217
Makura ZGG, Robson AK, Wegener's granulomatosis presenting as a temporal headache. *Clin. Rec.* **110**: 802
Makura ZGG *see* Lancaster JL *et al.*
Malamou-Lada E *see* Manolis E *et al.*
Malan JF *see* Prescott and Malan
Malatine T *see* Soufi HE *et al.*
Malhan D *see* Hill J *et al.*
Malik N *see* Curran AJ *et al.*
Malik T *see* Simo R *et al.*
Malik TH *see* Mirza S *et al.*
Malki D, Quine SM, Pfleiderer AG, Nasal splints, revisited. *Orig. Art.* **113**: 725
Mallea I *see* Marco-Algarra J *et al.*
Mallon EA *see* Vernham GA *et al.*
Maltas V *see* Nikolaou A *et al.*
Mamelle G *see* Salvan D *et al.*
Mancini P *see* Filipo R *et al.*
Mandal BK *see* Simo R *et al.*
Mandour MA *see* Zeitoun H *et al.*
Mangat KS *see* Courteney-Harris RG *et al.*
Maniar D *see* Udwadia RA *et al.*
Manisali M *see* Bryant C *et al.*
Manjaly G *see* Buckland JR *et al.*; Lee WC *et al.*
Mankekar G, Nayak SR, Kirtane MV, Ingle MV, Fourth branchial arch fistula: a case report. *Clin. Rec.* **107**: 458
Mann SBS *see* Gupta AK *et al.*; Narayana HM *et al.*; Srinivasan S *et al.*
Manna R *see* Cadoni G *et al.*
Mannarà GM, La Rosa FC, Marino F, Plexiform schwannoma of the cheek. *Path. Focus* **113**: 1034
Mannarà GM, Sacilotto C, Frattasio A, Pedace E, Di Loreto C, Ferlito A, Bilateral secondary syphilis of the tonsil. *Path. Focus* **113**: 1125
Mannarà GM, *see also* Ferlito A *et al.*
Manni JJ *see* Ole-Lengine and Manni
Manning RH *see* Wareing MJ *et al.*
Mannion E *see* Greig AVH *et al.*
Manohar MB, Boldy DAR, Bryan RL, Pearman K, Penicillamine-induced changes in elastic tissue of the upper respiratory tract. *Clin. Rec.* **107**: 62

Manolis E, Tsakris A, Kandiloros D, Kenellopoulou M, Malamou-Lada E, Ferekidis E, Adamopoulos G, Legakis NJ, Alterations to the oropharyngeal and nasopharyngeal microbial flora of children after tonsillectomy and adenoidectomy. *Orig. Art.* **108**: 763
Manolopoulos L, Stavroulaki P, Yiotakis J, Segas J, Adamopoulos G, CO_2 and KTP-532 laser cordectomy for bilateral vocal fold paralysis. *Orig. Art.* **113**: 637
Manolopoulos L, *see also* Adamopoulos G *et al.*; Yiotakis J *et al.*
Manor R *see* Hefer T *et al.*
Mañós-Pujol M *see* Gonzalez-Compta X *et al.*
Mansell NJ, Jani P, Bailey CM, Plummer–Vinson syndrome — a rare presentation in a child. *Clin. Rec.* **113**: 475
Mansfield M *see* Natarajan B *et al.*
Mansour F *see* Zakzouk SM *et al.*
Mansour MH *see* El-Guindy and Mansour
Mansour P, George MK, Pahor AL, Ceruminous gland tumours: a reappraisal. *Clin. Rec.* **106**: 727
Mansour P, *see also* George MK *et al.*
Mansukhani K *see* de Souza C *et al.*
Mantoni M *see* Charabi S *et al.*
Manuel J *see* Merino E *et al.*
Maor E *see* Noghreyan A *et al.*
Maragoudakis P *see* Xenellis J *et al.*
Marais J, Cochleotoxicity due to Mianserin hydrochloride. *Clin. Rec.* **105**: 475
Marais J, Maran AGD, Nasoantral window assessment by acoustic rhinometry. *Orig. Art.* **108**: 567
Marais J, Mitchell R, Wightman AJA, The value of radiographic assessment for oropharyngeal foreign bodies. *Rad. Focus.* **109**: 452
Marais J, *see also* Anstey ST *et al.*; Porter MJ *et al.*
Maran AGD, Head and neck surgery: An encyclopaedia of ignorance. *Orig. Art.* **104**: 529
Maran AGD, *see also* Ah-See KW *et al.*; Marais and Maran; Sim DW *et al.*; White A *et al.*
Marandas P *see* Koka VN *et al.*; Salvan D *et al.*
Marangos N, Hearing loss in multiple sclerosis: localization of the auditory pathway lesion according to electrocochleographic findings. *Clin. Rec.* **110**: 252
Marangos N, Schumacher M, Facial palsy after glomus jugulare tumour embolization. *Rad. Focus* **113**: 268
Marangos N, *see also* Laszig R *et al.*; Maier W *et al.*
Van Marck E *see* Van Laer C *et al.*
Marck EV *see* de Varebeke SJ *et al.*
Marco-Algarra J, Gimenez F, Mallea I, Armengot M, de la Fuente L, Cholesteatoma in children: results in open versus closed techniques. *Orig. Art.* **105**: 820
Marco-Algarra J, *see also* Gimenez and Marco-Algarra
Marell M *see* Berger G *et al.*
Marianowski R, Wassef M, Herman P, Tran Ba Huy P, Nasal haemangiopericytoma: report of two cases with literature review. *Rev. Art.* **113**: 199
Marinelli L *see* Cadoni G *et al.*
Marino F *see* Mannarà GM *et al.*
Mark J *see* Bende and Mark
Marks N *see* Ingrams D *et al.*
Marks NJ *see* Raine NMN *et al.*
Marliani AF *see* Pirodda A *et al.*
Marmuse JP, Guedon C, Koka VN, Gastric tube transposition for cancer of the hypopharynx and cervical oesophagus. *Orig. Art.* **108**: 33
Maroof M, Siddique M, Khan RM, Difficult diagnostic laryngoscopy and bronchoscopy aided by the laryngeal mask airway. *Short Comm.* **106**: 722
Márquez F la O J *see* Dueñas L *et al.*
Marres EH *see* Vos GD *et al.*
Marres HAM, Cremers CWRJ, Huygen PLM, Joosten FBM, The deafness, pre-auricular sinus, external ear anomaly and commissural lip pits syndrome — otological, vestibular and radiological findings. *Orig. Art.* **108**: 13
Marres HAM, *see also* Ensink RJH *et al.*; van der Coer JMG *et al.*; van Leeuwen JPPM *et al.*
Marriage HJ *see* Wallace and Marriage
Marriage J, Barnes NM, Is central hyperacusis a symptom of 5-hydroxytryptamine (5-HT) dysfunction? *Rev. Art.* **109**: 915
Marshall CL *see* Burstin and Marshall
Marshall HF *see* Johnson IJM *et al.*; Watson and Marshall; Watson MG *et al.*
Marshall J *see* Prichard AJN *et al.*
Marshall JN, Soo G, Coakley FV, Ectopic salivary gland in the posterior triangle of the neck. *Clin. Rec.* **109**: 669
Martin D *see* Ramamurthy L *et al.*
Martin F *see* El Naggar M *et al.*
Martin FW *see* Panwar and Martin
Martin J *see* Connolly AAP *et al.*
Martin L, Moriniere S, Machet M-C, Robier A, Vaillant L, Bilateral conductive deafness related to erosive lichen planus. *Clin. Rec.* **112**: 365
Martin-Hirsch D *see* Irani BS *et al.*
Martin-Hirsch DP, Habashi S, Benbow EW, Farrington WT, Post-irradiation leiomyosarcoma of the maxilla. *Clin. Rec.* **105**: 1068
Martin-Hirsch DP, Habashi S, Page R, Hinton AE, Latent mastoiditis: no room for complacency. *Clin. Rec.* **105**: 767
Martin-Hirsch DP, Lannigan F, Irani B, Distribution of topical antibiotic preparations in mastoid cavities. *Short Comm.* **106**: 247
Martin-Hirsch DP, Lannigan FJ, Irani B, Batman P, Oncocytic papillary cystadenomatosis of the larynx. *Path. Focus* **106**: 656
Martin-Hirsch DP, Lannigan FJ, Pharyngo-oesophageal fistula following iatrogenic perforation of a pharyngeal pouch. *Clin. Rec.* **109**: 1215
Martin-Hirsch DP, Lannigan FJ, The management of benign thyroid goitre causing tracheo-oesophageal embarrassment. Cli. **109**: 892
Martin-Hirsch DP, Newbegin CJR, Autosuture GIA gun: a new application in the treatment of hypopharyngeal diverticula. *Short Comm.* **107**: 723
Martin-Hirsch DP, Newbegin CJR, Right vocal fold paralysis as a result of central venous catheterization. *Clin. Rec.* **109**: 1107
Martin-Hirsch DP, Smelt GJC, Conchal flap meatoplasty. *Short Comm.* **107**: 1029
Martin-Hirsch DP, Smelt GJC, Improvement in hand-held CO_2 laser safety. *Short Comm.* **108**: 233
Martin-Hirsch DP, Woodhead CJ, Vize CE, Long-term ventilation of the middle ear using a tympanotomy technique. *Orig. Art.* **109**: 1151
Martin-Hirsch DP, *see also* Coatesworth AP *et al.*; Irani BS *et al.*
Martinez Devesa P, Reid HS, Jefferis AF, Temporocele: CT findings and management. *Clin. Rec.* **113**: 661
Martinez-Chamorro E *see* Muñoz and Martinez-Chamorro
Martinez-San Millán J *see* Plaza G *et al.*
Martínez-Vidal A *see* Plaza G *et al.*; Raboso E *et al.*
Martínez-Vidal J *see* Sarandeses-García A *et al.*
Maru YK, Munjal S, Gupta Y, Brush cytology and its comparison with histopathological examination in cases of diseases of the nose. *Orig. Art.* **113**: 983
Marveggio C *see* Gherardi G *et al.*
Maskell DG *see* Gray RF *et al.*
Mason CJ *see* Vohra and Mason
Mason J, Murty GE, Foster H, Bradley PJ, Tracheostomy self care: the Nottingham System. *Short Comm.* **106**: 723
Mason J, O'Flynn P, Gibbin K, Cannabis in the external ear. *Clin. Rec.* **107**: 444
Mason JDT, Haynes RJ, Jones NS, Interpretation of the dilated pupil during endoscopic sinus surgery. *Orig. Art.* **112**: 622
Mason JDT, Hehar SS, Holden M, Jones NS, Measurement of small tissue volumes using Holden's apparatus. *Orig. Art.* **109**: 1181
Mason JDT, Jardine A, Gibbin KP, Foetal warfarin syndrome — a complex airway problem. *Clin. Rec.* **106**: 1098
Mason JDT, Jones NS, Hughes RJ, Holland IM, A systematic approach to the interpretation of computed tomography prior to endoscopic sinus surgery. *Rad. Focus* **112**: 986
Mason JDT, Mason SM, Gibbin KP, Raised ABR threshold after suction aspiration of glue from the middle ear: three case studies. *Orig. Art.* **109**: 726
Mason JDT, Rogerson DR, Butler JD, Client-centred hypnotherapy in the management of tinnitus - is it better than counselling? *Orig. Art.* **110**: 117
Mason JDT, *see also* Green KMJ *et al.*; Lim PVH *et al.*
Mason PS *see* Harries PG *et al.*
Mason SM *see* Koyuncu M *et al.*; Mason JDT *et al.*
Master B *see* Journeaux SF *et al.*
Masuda M *see* Nakashima T *et al.*

Masuda T *see* Nakanishi R *et al.*
Masuda Y *see* Hisa Y *et al.*; Lai M-T *et al.*
Masutani H *see* HT Sando *et al.*
Mathan M *see* Job A *et al.*
Matheson LM *see* Barr-Hamilton *et al.*
Mathew J *see* Raman R *et al.*
Mathias D *see* Smith I *et al.*
Mathias DB, Should ENT surgeons undertake pituitary surgery? *Edit. Rev.* **111**: 511
Mathias DB, *see also* Richardson H *et al.*
Mathieson L, Voice disorders following road traffic accidents. *Edit. Rev.* **111**: 903
Mathur NN, Sardana P, Singh VP, Bais AS, Adult tracheocele with large cervical presentation. *Clin. Rec.* **113**: 364
Matin MA, Alum K, O'Driscoll K, Murphy PJ, Acute inspiratory stridor: a presentation of myasthenia gravis. *Clin. Rec.* **113**: 1114
Matsuki C *see* Higashi and Matsuki
Matsunaga T *see* Kitahara S *et al.*
Matsunaga Y *see* Kasuga Y *et al.*
Matsushita F *see* Suzuki M *et al.*
Mattelin W *see* Ameye F *et al.*
Matthews DO *see* O'Reilly and Matthews
Matulić Z *see* Skitarelić N *et al.*
Maurizi M, Salvinelli F, Capelli A, Carbone A, Monomorphic adenomas of the major salivary glands: clinicopathological study of 44 cases. *Orig. Art.* **104**: 790
Mavroleon G *see* Holgate and Mavroleon
Maw AR, Development of tympanosclerosis in children with otitis media with effusion and ventilation tubes. *Orig. Art.* **105**: 614
Maw AR, Hawthorne MR, Auro-nasopharyngeal polyp and cholesteatoma. *Clin. Rec.* **104**: 809
Maw AR, Smith IM, Lance GN, Lateral cephalometric analysis of children with otitis media with effusion: a comparison with age and sex matched controls. *Orig. Art.* **105**: 71
Maw AR, *see also* Baer S *et al.*; Blanshard JD *et al.*; O'Keefe and Maw; Robson AK *et al.*
Mawman D *see* Maas S *et al.*
Mawman DJ, Edwards JD, Giles EC, Aplin DY, O'Driscoll M, Woolford TJ, An audit of the cochlear implant service in Manchester. *Aud. Art.* **110**: 1046
Mawman DJ, *see also* Axon PR *et al.*; Ramsden R *et al.*
Maxwell P *see* McCluggage P *et al.*
Mayall F, Hickman J, Bulman C, Blewitt R, Leiomyosarcoma of the tongue: a very rare tumour. *Path. Focus* **108**: 617
Mayall F, Wild D, A silver tattoo of the nasal mucosa after silver nitrate cautery. *Path. Focus* **110**: 609
Mayall FG, Hickman J, Knight C, Singharo S, An amalgam tattoo of the soft palate: a case report with energy dispersive x-ray analysis. *Clin. Rec.* **106**: 834
Maynard CA *see* Denholm SW *et al.*
Mazzoni A *see* Naguib MB *et al.*; Sanna M *et al.*
Md Iqbal S, Murthy JG, Sharma N, Giant parotid calculus — an unusual presentation. *Clin. Rec.* **106**: 446
Mears T, Amerasinghe C, Rhinosporidiosis. *Path. Focus* **106**: 468
Mebed H *see* Rifai M *et al.*
Meehan CJ *see* Sharp JF *et al.*
Meehan T, Henein RR, An unusual pharyngeal pouch. *Clin. Rec.* **106**: 1002
Meehan T, Kaddour H, Lannigan FJ, Alar cartilage haematoma. *Clin. Rec.* **108**: 500
Megighian D, Delgado H, Blandamura S, Hodgkin's disease secondary to recurrent adenoid cystic carcinoma of the parotid gland. *Clin. Rec.* **105**: 224
Mehan R *see* Lobo CJ *et al.*
Mehanna HM, MacGregor FB, The case of the missing carotid artery: a well aimed knife! *Clin. Rec.* **112**: 387
Mehdorn HM *see* Brademann G *et al.*
Mehta JS, Sharr MM, An unusual cause of acute labyrinthine failure **112**: 193
Meikle D *see* Goldsmith P *et al.*; Watson MG *et al.*
Meirion Thomas J *see* Ball and Meirion Thomas; Ramanathan and Meirion Thomas
Meis JM *see* Williams SB *et al.*
Melamed Y *see* Gordon CR *et al.*
Melgarejo-Moreno PJ, Ribera-Cortada I, Hellin-Meseguer D, Submucosal glands after maxillary sinus surgery: an experimental study in rabbits. *Orig. Art.* **110**: 644
Melgarejo-Moreno P, Hellin-Meseguer D, Different glycoconjugates in the submucosal glands of the supraglottis and subglottis. Lectin histochemistry study in the hamster. *Orig. Art.* **111**: 441
Mellado Encinas, P *see* Del Valle Zapico A *et al.*
Melville J *see* Irving RM *et al.*
Mendel P, Bristow A, New methods of dealing with the complications of panendoscopy. *Short Comm.* **106**: 903
Mendelow AD *see* Deans JAJ *et al.*; Hartley and Mendelow
Mendelsohn M, A guided approach to surgery for aspiration: two case reports. *Orig. Art.* **107**: 121
Mendelsohn MS *see* Fenton JE *et al.*
Mendoza N *see* Vowles R *et al.*
Menown IBA, Liew SH, Napier SS, Primrose WJ, Retropharyngeal liposarcoma. *Path. Focus* **106**: 469
Meor Kamal MZ *see* Sharma HS *et al.*
Merchant SN, Ravicz ME, Voss SE, Peake WT, Rosowski JJ, Middle ear mechanics in normal, diseased and reconstructed ears **112**: 715
Meredith GW *see* Mew and Meredith
Meredith N *see* Heo SJ *et al.*
Merhametsiz A *see* Külahli I *et al.*
Meric F *see* Osma Ü *et al.*
Merino E, Hellin D, Garcia F, Manuel J, Sudden deafness and cerebellar tumour. *Clin. Rec.* **108**: 584
Merite-Drancy A *see* Laccoureye O *et al.*
Mesko TW, Friedman J, Sendzischew H, Nixon DD, Rectal carcinoma metastatic to the thyroid gland. *Path. Focus* **110**: 192
Mesko TW, Garcia O, Yee LD, Villar M, Chan H, The syndrome of inappropriate secretion of antidiuretic hormone (SIADH) as a consequence of neck dissection. *Orig. Art.* **111**: 449
Metin KK *see* Başak S *et al.*
Metreweli C *see* Ahuja A *et al.*
Metz KA *see* Schmidt U *et al.*
Meulenbroeks AAWM, Vos GD, Van der Beek JMH, Kitslaar PJEHM, An unexpected cause of upper airway obstruction. *Clin. Rec.* **109**: 252
Mew JRC, Meredith GW, Middle ear effusion: An orthodontic perspective. *Orig. Art.* **106**: 7
Meyer HE *see* van Leeuwen JPPM *et al.*
Meyvisch P *see* Gordts F *et al.*
Michaels L *see* Laskiewicz B *et al.*; Milroy and Michaels; Phelps PD *et al.*; Wells and Michaels
Michie BA *see* Cain AJ *et al.*
Midgley E *see* Jardine AH *et al.*
Midwinter KI, Gill KS, Spencer JA, Fraser ID, Osteomyelitis of the temporomandibular joint in patients with malignant otitis externa. *Clin. Rec.* **113**: 451
Mikhail T *see* De and Mikhail
Miles JB *see* Enion DS *et al.*
Miles LP, Naidoo LCD, Reddy J, Congenital dermoid cyst of the tongue. *Clin. Rec.* **111**: 1179
Miles S *see* Sirimanna KS *et al.*
Milford CA, Mugliston TA, Lund VJ, Mackay IS, Long-term safety and efficacy study of intranasal ipratropium bromide. *Orig. Art.* **104**: 123
Milford CA, *see also* Commins DJ *et al.*; Hadley J *et al.*; James AL *et al.*; O'Flynn PE *et al.*; Sim RJ *et al.*; Watters and Milford
Miličić D *see* Danić D *et al.*
Millán J *see* Adiego MI *et al.*
Millar EKA, Vaughan Jones R, Lang S, Prostatic adenocarcinoma metastatic to the palatine tonsil: a case report. *Path. Focus* **108**: 178
Miller IW *see* Roland NJ *et al.*
Miller RF *see* Mochloulis G *et al.*
Miller RH *see* Gianoli and Miller
Mills RG, Douglas-Jones T, Gareth-Williams R, 'Ceruminoma' — a defunct diagnosis. *Orig. Art.* **109**: 180
Mills RGS *see* Douglas-Jones AG *et al.*; Tomkinson A *et al.*
Mills RP, Management of retraction pockets of the pars tensa. *Orig. Art.* **105**: 525
Mills RP, The use of cortical bone grafts in ossiculoplasty I: Surgical techniques and hearing results. *Orig. Art.* **107**: 686
Mills RP, The use of cortical bone grafts in ossiculoplasty II: Graft mass and hearing change at different frequencies. *Orig. Art.* **107**: 690
Mills RP, The use of cortical bone grafts in ossiculoplasty III: Audit of costs. *Orig. Art.* **107**: 695

Mills RP, Irani BS, Vaughan-Jones RJ, Padgham ND, Maxillary sinusitis in children with otitis media with effusion. Ori. **108**: 842
Mills RP, Pagham ND, Management of childhood cholesteatoma. *Orig. Art.* **105**: 343
Mills RP, *see also* Christmas HE *et al.*; Courteney-Harris and Mills; Tay and Mills; Vaughan-Jones and Mills
Milner SM, Bennett JDC, Emergency cricothyrotomy. *Rev. Art.* **105**: 883
Milroy C *see* Pfleiderer AG *et al.*
Milroy CM, Ossification of the epiglottis. *Path. Focus* **106**: 180
Milroy CM, Michaels L, Pathology of the otic capsule. *Orig. Art.* **104**: 83
Milroy CM, *see also* Carter and Milroy; Ferlito A *et al.*; Hald J *et al.*; Lund and Milroy
Milton CM, Shotton JC, Premachandran DJ, Woodward BM, Fabre JW, Sergeant RJ, A new technique using cultured epithelial sheets for the management of epistaxis associated with hereditary haemorrhagic telangiectasia. *Orig. Art.* **107**: 510
Milton CM, *see also* Premachandra DJ *et al.*; Shotton JC *et al.*
Minatel E *see* Barzan L *et al.*
Minatogawa T, Nakamura Node M, Fukuda I, Kumoi T, Dermoid cyst in the middle ear. *Clin. Rec.* **107**: 335
Ming Li X, Ignace Wei W, Feng Gou X, Wing Yuen P, Kun Lam L, Cervical lymph node metastatic patterns of squamous carcinomas in the upper aerodigestive tract. *Orig. Art.* **110**: 937
Mingquan B *see* Lixiang Z *et al.*
Mirck PGB *see* Kemper J *et al.*
Mirza A *see* Tolley NS *et al.*
Mirza N *see* Altman KW *et al.*
Mirza S, Hopkinson L, Malik TH, Willatt DJ, The use of inhalers in patients with tracheal stomas or tracheostomy tubes. *Clin. Rec.* : **113**: 762
Mishra SC, Shukla GK, Bhatia N, Pant MC, Angiofibromas of the post nasal space: A critical appraisal of various therapeutic modalities. *Orig. Art.* **105**: 547
Misiolek M, Ziora D, Oklek K, Namyslowski G, Evaluation of upper airway obstruction after partial laryngectomies by radiological method and flow-volume loop analysis. *Orig. Art.* **108**: 954
Misra NK *see* Tandon DA *et al.*
Mistry B *see* Grewal DS *et al.*
Mitchell D *see* Ong CC *et al.*; Wareing and Mitchell
Mitchell DB *see* Al-Saati A *et al.*; Buckley JG *et al.*; Hickey SA *et al.*; Wareing MJ *et al.*
Mitchell G, Pearson CR, Henk JM, Rhys-Evans P, Excision and low-dose radiotherapy for refractory laryngeal granuloma. *Clin. Rec.* **112**: 491
Mitchell R *see* Hogg RP *et al.*; Marais J *et al.*
Mitchell RB, Pereira KD, Lazar RH, Fat graft myringoplasty in children - a safe and successful day-stay procedure. *Orig. Art.* **111**: 106
Mitchell RB, *see also* Hore I *et al.*
Mitchell TE, Courteney-Harris RG, Innes AJ, Eye protection during mastoid surgery. *Orig. Art.* **109**: 707
Mitchell TE, Gibson WPR, Positioning of the receiver-stimulator for the Cl-24M cochlear implant in infants. *Orig. Art.* **113**: 212
Mitchell TE, Girling AC, Hairy polyp of the tonsil. *Path. Focus* **110**: 101
Mitchell TE, Pickles JM, Traumatic laryngocele. *Clin. Rec.* **112**: 482
Mitsudomi T *see* Nakanishi R *et al.*
Miwa A *see* Nishimura T *et al.*
Miwa H *see* Kimura Y *et al.*
Miwa T *see* Ishimaru T *et al.*; Kimura Y *et al.*; Okabe Y *et al.*; Wen QH *et al.*
Miyagi C *see* Yasumoto K *et al.*
Miyaguchi M, Sakai S, Mori N, Spontaneous pain in patients with maxillary sinus carcinoma in relation to T-classification and direction of tumour spread. *Orig. Art.* **106**: 804
Miyaguchi M, Sakai S, Takashima H, Hosokawa H, Lymph node and distant metastases in patients with sinonasal carcinoma. *Orig. Art.* **109**: 304
Miyaguchi M, Sakai S-I, Mori N, Kitaoku S, Multiple primary malignancies with malignant tumours of the nasal cavities and paranasal sinuses. *Orig. Art.* **104**: 696
Miyaguchi M, Sakai S-I, Mori N, Kitaoku S, Symptoms in patients with maxillary sinus carcinoma. *Orig. Art.* **104**: 557
Miyaguchi M, Takashima H, Kubo T, Laryngeal necrosis after combined chemotherapy and radiation therapy. *Clin. Rec.* **111**: 763
Miyashito H *see* Hoshino T *et al.*
Miyata M *see* Kitamura K *et al.*; Tamagawa Y *et al.*
Miyazawa T *see* Ueda H *et al.*
Miyoshi M *see* Hisashi K *et al.*
Mizukami Y *see* Kimura Y *et al.*; Nakagawa H *et al.*
Mizukoshi K *see* Ohashi N *et al.*
Mizuno Y *see* Ishimaru T *et al.*
Mizuta K *see* Hoshino T *et al.*
Mizutani T *see* Kaga K *et al.*
Mladina R, Endoscopic sinus surgery: a metallic foreign body at the sphenoethmoidal junction. *Clin. Rec.* **106**: 998
Mladina R, *see also* Skitarelić N *et al.*
Mobacher A *see* Abu Shara KA *et al.*
Mochimatsu I, Tsukuda M, Furukawa S, Sawaki S, Tumours metastasizing to the head and neck — a report of seven cases. *Clin. Rec.* **107**: 1171
Mochimatsu I, Tsukuda M, Sawaki S, Nakatani Y, Extramedullary plasmacytoma of the larynx. *Clin. Rec.* **107**: 1049
Mochloulis G, Hern JD, Hollis LJ, Tolley NS, Maxillary antral lavage using inferior meatal cannula anaesthesia. *Short Comm.* **110**: 763
Mochloulis G, Irving RM, Grant HR, Miller RF, Laryngeal Kaposi's sarcoma in patients with AIDS. *Orig. Art.* **110**: 1034
Mochloulis G, *see also* Ghufoor K *et al.*; Goumas P *et al.*; Hern JD *et al.*; Hollis LJ *et al.*; Jayaraj SM *et al.*; Montgomery P *et al.*
Mochon A *see* Esteban F *et al.*
Moesgard-Nielsen V *see* Højslet PE *et al.*
Moesner J *see* Hansen LT *et al.*
Moffat D, Baguley DM, von Blumenthal H, Irving RM, Hardy DG, Sudden deafness in vestibular schwannoma. *Orig. Art.* **108**: 116
Moffat DA, Cumberworth VL, Baguley DM, Endolymphatic hydrops precipitated by haemodialysis. *Clin. Rec.* **104**: 641
Moffat DA, Golledge J, Baguley D, Hardy D, Clinical correlates of acoustic neuroma morphology. *Orig. Art.* **107**: 290
Moffat DA, Irving RM, The molecular genetics of vestibular schwannoma. *Rev. Art.* **109**: 381
Moffat DA, Saunders JE, McElveen JT, McFerran DJ, Hardy DG, Unusual cerebello-pontine angle tumours. *Orig. Art.* **107**: 1087
Moffat DA, Toner JG, Baguley DM, Hardy D, Posterior fossa vestibular neurectomy. *Orig. Art.* **105**: 1002
Moffat DA, *see also* Arullendran P *et al.*; Baguley DM *et al.*; Blamires TL *et al.*; Farrell ML *et al.*; Jayaram M *et al.*; Lau DPC *et al.*; Monem SA *et al.*; Morris DP *et al.*; Reece PH *et al.*; Rudd MJ *et al.*; von Blumenthal H *et al.*; Wareing MJ *et al.*
Mogi G *see* Suzuki M *et al.*
Mohamad A *see* Sharma HS *et al.*
Mohan H *see* Chandra Jha B *et al.*; Goyal A *et al.*
Mohr RM *see* Klumpp TR *et al.*
Moir A *see* Allsager CM *et al.*
Moir AA *see* Banerjee AR *et al.*
Mojumdar B *see* Soussi AC *et al.*
Møller H, Tos M, Point and period prevalence of otitis media with effusion evaluated by daily tympanometry. *Orig. Art.* **104**: 937
Møller H, *see also* Buchwald C *et al.*
Møller P, Dingsør G, Otitis media with effusion: can erythromycin reduce the need for ventilating tubes? *Orig. Art.* **104**: 200
Moller-Andersen K *see* Sorensen WT *et al.*
Molony NC, Salto-Tellez M, Grant WE, KTP laser assisted excision of glomus tympanicum. *Clin. Rec.* **112**: 956
Molony NC, Stewart A, Ah-See K, McLaren K, Hodgkin's lymphoma of the nasopharynx. *Path Foc.* **112**: 103
Molony NC, *see also* Ah-See KW *et al.*; Ah-See and Molony
Molyneux AJ *see* Watters and Molyneux
Mondal A, Patra DK, Efficacy of fine needle aspiration cytology in the diagnosis of tuberculosis of the thyroid gland: a study of 18 cases. *Orig. Art.* **109**: 36
Monem SA, Moffat DA, Frampton MC, Carcinoma of the ear: a case report of a possible association with chlorinated disinfectants. *Clin. Rec.* **113**: 1004
Monfardini S *see* Barzan L *et al.*
Monge EG *see* O'Connor Reina C *et al.*
Monini S *see* Filipo R *et al.*
Montadon P *see* Quinodoz D *et al.*

Montgomery P, Willson PD, Mochloulis G, Tolley NS, Rosin RD, Laparoscopically assisted total laryngopharyngoesophagectomy with gastric transposition. *Clin. Rec.* **110**: 1072
Montgomery P, *see also* Ajulo SO *et al.*
Montgomery PQ, Khan JI, Feakins R, Nield DV, Paraffinoma revisited: a post-operative condition following rhinoplasty nasal packing. *Clin. Rec.* **110**: 785
Montgomery PQ, *see also* Ghufoor K *et al.*; Hern JD *et al.*; Hollis LJ *et al.*; Pracy JPM *et al.*; Prior AJ *et al.*; See ACH *et al.*
Montgomery R *see* Gordon MT *et al.*
Montserrat JM *see* Guedea F *et al.*
Moñuz A, Tomás M, Kaiser C, Gavilan J, Conservative management of epistaxis. *Orig. Art.* **104**: 868
Mooi WJ *see* Mak-Kregar S *et al.*
Moon WS *see* Hong KH *et al.*
Mooney E *see* Donnelly MJ *et al.*
Moore J *see* Hone SW *et al.*
Moore PJ, The high jugular bulb in ear surgery: three case reports and a review of the literature. *Clin. Rec.* **108**: 772
Moore-Gillon B *see* Drysdale AJ *et al.*
Moore-Gillon V *see* Al-Shahi R *et al.*; Connolly AAP *et al.*; Drysdale and Moore-Gillon; Rowe-Jones JM *et al.*; Wyatt ME *et al.*
Moorjani V *see* Goel S *et al.*
de Mora Mieszkowski J *see* Szilvassy J *et al.*
Morad N *see* Thomas R *et al.*
Morais D *see* Benito I *et al.*
Moraitis D *see* El Jassar P *et al.*
Moralee SJ, Murray JAM, Would day-case adult tonsillectomy be safe? *Orig. Art.* **109**: 1166
Moralee SJ, Reilly PG, Metabolic stridor: bilateral vocal cord abductor paralysis secondary to hypokalaemia? *Clin. Rec.* **106**: 56
Moralee SJ, *see also* Thompson AC *et al.*
Morales Angula C *see* Del Valle Zapico A *et al.*
Moran M *see* Nofal and Moran
Morandi X *see* Godey B *et al.*
Morar P *see* Jones TM *et al.*
More IAR *see* Barr GD *et al.*
Moreno JA *see* Esteban F *et al.*
Morgan DAL, Radiotherapy in head and neck cancer. *Edit. Rev.* **111**: 1006
Morgan DAL, *see also* Clark LJ *et al.*
Morgan DW, Abdullah V, Quiney R, Myint S, Human papilloma virus and carcinoma of the laryngopharynx. *Orig. Art.* **105**: 288
Morgan DW, Aldren C, Hoare TJ, Hearing loss due to craniometaphyseal dysplasia. *Clin. Rec.* **104**: 807
Morgan DW, Evans JNG, Developmental nasal anomalies. *Orig. Art.* **104**: 394
Morgan DW, Hadley J, Willis G, Cheesmon AD, Use of a portable manomometer as a screening procedure in voice rehabilitation. *Orig. Art.* **106**: 353
Morgan DW, *see also* Brooks JP *et al.*; Hoare TJ *et al.*; Hughes and Morgan; Snow DG *et al.*
Morgan K *see* Herdman RCD *et al.*
Morgan M, Bennett M, Wilson JA, Cavernous lymphangioma in the adult parotid. *Clin. Rec.* **111**: 590
Morgan M, Flood L, Hawthorne M, Raje S, Chemical labyrinthectomy and cochlear implantation for Ménière's disease — an effective treatment or a last resort? *Clin. Rec.* **113**: 666
Morgan MK, Aldren CP, Oroantral fistula: a complication of transantral ligation of the internal maxillary artery for epistaxis. *Clin. Rec.* **111**: 468
Morgan N, Brookes GB, Central nervous system complications of acute tonsillitis. *Clin. Rec.* **111**: 274
Morgan NJ, Emberton P, Barton RPE, The importance of thyroid scanning in neck lumps — a case report of ectopic tissue in the right submandibular region. *Clin. Rec.* **109**: 674
Morgan NJ, Emberton P, CT scanning and laryngocoeles. *Rad. Focus* **108**: 266
Morgernstern C *see* Ikeda and Morgenstern
Mori N *see* Miyaguchi M *et al.*
Mori T *see* Yumoto E *et al.*
Moriarty B *see* Drake-Lee AB *et al.*
Moriarty BG, Stapes surgery: implications for training. *Orig. Art.* **104**: 203
Morimatsu M *see* Harada H *et al.*
Morimitsu T *see* Tono T *et al.*
Morimoto M *see* Tanaka Y *et al.*
Moriniere S *see* Martin L *et al.*
Moriya K *see* Sakaguchi M *et al.*
Moriyama H, Nakajima T, Honda Y, Studies on mucoceles of the ethmoid and sphenoid sinuses: analysis of 47 cases. *Orig. Art.* **106**: 23
Moriyama H, *see also* Shiwa M *et al.*
Moriyama S-i *see* Kasuga Y *et al.*
Morphopoulos G *see* Scott PMJ *et al.*
Morris DP, Ballagh RH, Hong A, Moffat DA, Hardy DG, Thrombosed posterior inferior cerebellar artery aneurysm: a rare cerebellopontine angle tumour. *Clin. Rec.* **109**: 429
Morris DP, Luff DA, Hargreaves SP, Rothera MP, "Bones of contention". The supply of temporal bones for dissection: the legalities, problems and solutions. *Rev. Art.* **112**: 1138
Morris K *see* Dutton JEM *et al.*
Morrison AW, Anticipation in Ménière's disease. *Orig. Art.* **109**: 499
Morrison AW, Twenty-one years of otolaryngology litigation **104**: 162
Morrison AW, *see also* Baldwin DL *et al.*
Morrison D, Rose EL, Smith AP, Lesser THJ, Dyskeratosis congenita and nasopharyngeal atresia. *Clin. Rec.* **106**: 996
Morrison GA *see* O'Reilly BJ *et al.*
Morrison GAJ, Dilkes MG, Cholesterol cyst and cholesterol granuloma of the petrous bone. *Rad. Focus* **106**: 465
Morrison GAJ, Kotecha B, Evans JNG, Ribavirin treatment for juvenile respiratory papillomatosis. *Orig. Art.* **107**: 423
Morrison GAJ, O'Reilly BJ, Chevretton EB, Kenyon GS, Long-term results of revision endolymphatic sac surgery. *Orig. Art.* **104**: 613
Morrison GAJ, *see also* Al-Saati A *et al.*; Chevretton and Morrison; Dilkes MG *et al.*; Sharp HR *et al.*; Tierney PA *et al.*
Morrison M *see* Harries and Morrison
Morrissey G, Robinson AC, Stirling R, Cellular benign fibrous histiocytoma of the external auditory meatus. *Path. Focus* **110**: 98
Morrissey G, *see also* Cumberwoth VL *et al.*
Morrissey MSC, Venn PJH, Chan HY, Whittet H, Detection of extrinsic bronchial compression during foreign body removal by pulse oximetry. *Clin. Rec.* **104**: 50
Mortimer G *see* O'Hanlon DM *et al.*
Mortimore S, Thorp M, Cervical necrotizing fasciitis and radiotherapy: a report of two cases. *Clin. Rec.* **112**: 298
Mortimore S, Thorp MA, Nilssen ELK, Isaacs S, Hypoparathyroidism after the treatment of laryngopharyngeal carcinoma. *Orig. Art.* **112**: 1058
Mortimore S, Wormald PJ, The Groote Schuur hospital classification of the orbital complications of sinusitis. *Orig. Art.* **111**: 719
Mortimore S, Wormald PJ, Oliver S, Antibiotic choice in acute and complicated sinusitis. *Orig. Art.* **112**: 264
Morton RP, Evolution of quality of life assessment in head and neck cancer. *Rev. Art.* **109**: 1029
Motamed M, Farrell R, Philpott J, Rea P, Claudication on mastication following bilateral external carotid artery ligation for posterior epistaxis. *Clin. Rec.* **112**: 73
Motamed M, *see also* Hadfield PJ *et al.*
Motoyama S *see* Takasaki T *et al.*
Motoyama T *see* Fuse T *et al.*
Motwani G *see* Chaudhary N *et al.*
Moulin G, Dessi P, Andre P, Cannoni M, Pellett W, Zanaret M, Emram B, Chagnaud C, Giusano B, Bartoli J-M, Role of magnetic resonance in predicting late facial motor function after removal of vestibular schwannomas by the translabyrinthine approach. *Orig. Art.* **109**: 394
Moulin G, *see also* Dessi P *et al.*
Mount R *see* Wake M *et al.*
Mountain R *see* Ram B *et al.*
Mountain RE *see* Harmse JL *et al.*; Ram B *et al.*
Moustafa H, El-Guindy A, El-Sherief S, Targam A, The role of endoscopic laterofixation of the vocal cord in the treatment of bilateral abductor paralysis. *Orig. Art.* **106**: 31
Moustafa HM, Khalifa MA, Tympano-cartilago-stapediopexy: a method to improve hearing in open technique tympanoplasty. *Orig. Art.* **104**: 942
Moustopoulos MH *see* Kastanioudakis I *et al.*
Mroueh S *see* Ramadan HH *et al.*

Mu L, Sun D, He P, Radiological diagnosis of aspirated foreign bodies in children. *Orig. Art.* **104**: 778
Mu L, *see also* Li G-D *et al.*
Mugliston TA *see* Milford CA *et al.*
Muhamad M *see* Sharma HS *et al.*
Muhtar H *see* Yildiz K *et al.*
Mukherjee B, Bais AS, Bajaj Y, Role of polysomnography in tracheostomy decannulation in the paediatric patient. *Orig. Art.* **113**: 442
Mukherjee B, *see also* Bajaj Y *et al.*
Mukherji SK *see* Chong VFH *et al.*
Mukohdaka H *see* Hoshino T *et al.*
Mula M *see* Prasher D *et al.*
Müller W *see* Vavrina J *et al.*
Mummigatty AP *see* Thomas R *et al.*
Muneer A, Jones NS, Unilateral abducens nerve palsy: a presenting sign of sphenoid sinus mucocoeles. *Clin. Rec.* **111**: 644
Munichor M *see* Hefer T *et al.*
Muñiz L *see* Gòmez Estanocona N *et al.*
Munjal S *see* Maru YK *et al.*
Munk-Welsen L, Hansen HS, Bilateral carcinoma of the external auditory meatus. *Clin. Rec.* **105**: 112
Munker G *see* Maier W *et al.*
Muñoz A, Martinez-Chamorro E, Necrotizing external otitis caused by *Aspergillus fumigatus*: computed tomography and high resolution magnetic resonance imaging in an AIDS patient. *Rad. Focus* **112**: 98
Munro KJ, Cafarelli Dees D, An improvement in hearing sensitivity following hearing-aid fitting in a child with an apparent sensorineural hearing impairment. *Clin. Rec.* **110**: 362
Murakami M, Ohtani I, Aikawa T, Anzai T, Temporal bone findings in two cases of head injury. *Clin. Rec.* **104**: 986
Murakami M, Ohtani I, Hojo H, Wakasa H, Immunohistochemical evaluation with Ki-67: An application to salivary gland tumours. *Orig. Art.* **106**: 35
Murano E *see* Tsunoda K *et al.*
Muraoka H, Tsunoda A, Kojima M, Tokano H, Komatsuzaki A, Three-dimensional imaging of ENT diseases with helical computed tomography. *Rad. Focus* **110**: 604
Muraoka H, *see also* Tsunoda A *et al.*; Yamada M *et al.*
Murat Karaşen R, Sütbeyaz Y, Gundogdu C, Eren S, Şirin S, Haemangioperiocytoma of the middle ear with benign histological features. *Clin. Rec.* **113**: 911
Murata K *see* Hosoi H *et al.*
Murch SH *see* Murrant NJ *et al.*
Murphy PJ *see* Matin MA *et al.*
Murrant NJ, Cook JA, Murch SH, Acute ENT admission in Kawasaki disease. *Clin. Rec.* **104**: 581
Murrant NJ, Gatland DJ, Respiratory problems in acromegaly. *Clin. Rec.* **104**: 52
Murrant NJ, *see also* Ross and Murrant
Murray A, Gardiner DS, McGuiness RJ, Primary mycobacterial infection of the uvula. *Clin. Rec.* **112**: 1183
Murray A, *see also* Fergie N *et al.*
Murray DP *see* Jassar P *et al.*
Murray JAM *see* Moralee and Murray
Murris-Espin M *see* Percodani J *et al.*
Murrison AW, Smith DJ, Francis TJR, Counter RT, Maxillary sinus barotrauma with fifth cranial nerve involvement. *Clin. Rec.* **105**: 217
Murthy DP, Gupta AC, Sen Gupta SK, Dutta TK, Palotu ML, Nasal cartilaginous tumour. *Clin. Rec.* **105**: 670
Murthy DP, *see also* Dubey SP *et al.*; Gupta AC *et al.*
Murthy JG *see* Iqbal SM *et al.*; Md Iqbal S *et al.*
Murthy KD *see* Nayak DR *et al.*
Murthy P, Bandasson C, Dhillon RS, Temporomandibular joint dislocation and deafness from a cricket ball injury. *Clin. Rec.* **108**: 415
Murthy P, Christodoulou C, Yatigammana N, Datoo M, The influence of medical audit on the management of epistaxis in three district general hospitals. *Aud. Art.* **108**: 38
Murthy P, Laing MR, Admission and discharge policy for paediatric adenoidectomy and tonsillectomy — a rural perspective. *Orig. Art.* **112**: 1047
Murthy P, Laing MR, Dissection tonsillectomy: pattern of postoperative pain, medication and resumption of normal activity. *Orig. Art.* **112**: 41
Murthy P, Mckerrow WS, Nasal septal surgery: is routine follow-up necessary? *Aud. Art.* **109**: 320
Murthy P, Shenoy P, Khan NA, First cleft branchial fistula in a child — a modified surgical technique. *Clin. Rec.* **108**: 1078
Murthy P, Shenoy PK, McClymont LG, Angiomatous malformation of the floor of the mouth associated with fluctuating macroglossia in an adult: an unusual case report. *Clin. Rec.* **109**: 665
Murthy P, *see also* Feneley and Murthy; Hussain and Murthy; Nilssen ELK *et al.*
Murthy PSN *see* Puranik KR *et al.*; Varghese G *et al.*
Murty GE, Lamballe P, Welch AR, Early inappropriate secretion of antidiuretic hormone after trans-spheroidal pituitary adenomectomy.*Clin. Rec.* **104**: 894
Murty GE, Mains BT, Bennett MK, Salivary gland involvement in Wegener's granulomatosis. *Clin. Rec.* **104**: 259
Murty GE, Shinkwin C, Gibbin KP, Bilateral vocal fold paralysis in infants: tracheostomy or not? *Orig. Art.* **108**: 329
Murty GE, Watson MG, Diathermy haemostasis at tonsillectomy: Current practice - a survey of UK otolaryngologists. *Orig. Art.* **104**: 549
Murty GE, Welch AR, Soames JV, Basal cell adenocarcinoma of the parotid gland. *Clin. Rec.* **104**: 150
Murty GE, *see also* Banerjee AR *et al.*; Bath AP *et al.*; Diver JP *et al.*; Mason J *et al.*; Read-Jones M *et al.*; Saleh HA *et al.*; Shinkwin CA *et al.*; Walsh RM *et al.*; Watson MG *et al.*
Murugan V *see* Thomas R *et al.*
Murugasu E *see* Lobo CJ *et al.*
Mustafa E, Tahsin A, Cefotaxmine prophylaxis in major non-contaminated head and neck surgery: one-day *vs* seven-day therapy. *Orig. Art.* **107**: 30
Mutlu C *see* Bhatia S *et al.*
Muzaffar S *see* Aijaz F *et al.*
Muzaffer M, Hussain SI, Chughtai A, Plasma cell granuloma: maxillary sinuses. *Path. Focus* **108**: 357
Myatt HM, Cabrera M, Bilateral antrochoanal polyps in a child: a case report. *Clin. Rec.* **110**: 272
Myatt HM, Holland NJ, Cheesman AD, A skull base extradural hypoglossal neurilemmoma resected via an extended posterolateral approach. *Orig. Art.* **112**: 1052
Myatt HM, Remedios D, A transpalatal approach to the parapharyngeal space. *Clin. Rec.* **111**: 159
Myatt HM, *see also* Ajulo SO *et al.*
Myers EN *see* Fagan JJ *et al.*
Myint KK *see* Indudharan R *et al.*
Myint S *see* Morgan DW *et al.*; Vowles RH *et al.*
Mylanus EAM, Cremers CWRJ, A one-stage surgical procedure for placement of percutaneous implants for the bone-anchored hearing aid. *Orig. Art.* **108**: 1031

Na DG *see* Chung SK *et al.*
Nachtigal D *see* Yoskovitch A *et al.*
Naganoor IA *see* Shenoy AM *et al.*
Nagao K *see* Nomoto M *et al.*
Nagarkar NM *see* Chandra Jha B *et al.*; Goyal A *et al.*; Gupta AK *et al.*
Nagasawa A *see* Hirakawa K *et al.*
Nagayama I, Okabe Y, Katoh H, Furukawa M, Importance of preoperative recognition of the nonrecurrent laryngeal nerve. *Clin. Rec.* **108**: 417
Nagayama I, *see also* Ishimaru T *et al.*; Okabe Y *et al.*; Wen QH *et al.*
Nageris B, Elidan J, Sherman Y, Fibrosarcoma of the vocal fold: a late complication of radiotherapy. *Clin. Rec.* **108**: 993
Nageris B, Elidan J, Sichel J-Y, Aerodigestive tract obstruction as a late complication of radiotherapy. *Clin. Rec.* **109**: 68
Naguib M *see* Saleh E *et al.*
Naguib MB, Saleh E, Cokkeser Y, Aristegui M, Landolfi M, Taibah AK, Mazzoni A, Sanna M, The enlarged translabyrinthine approach for removal of large vestibular schwannomas. *Orig. Art.* **108**: 545
Naguib ME, Sanna M, Subtemporal exposure of the intrapetrous internal carotid artery. An anatomical study with surgical application. *Orig. Art.* **113**: 717
Nahl SS *see* Kent SE *et al.*
Naidoo LCD *see* Miles LP *et al.*
Nair RG *see* Hari CK *et al.*

Nair SB, Flood LM, Nath F, An unusual complication of Cloward's procedure presenting to the otolaryngologist. *Clin. Rec.* **112**: 1087
Nair SB, *see also* Sood S *et al.*
Naisby G *see* Kumar BU *et al.*
Nakagawa H, Mizukami Y, Kimura H, Watanabe Y, Kuwayama N, Metastatic masseter muscle tumour: a report of a case. *Clin. Rec.* **110**: 172
Nakagawa H, *see also* Ohashi N *et al.*
Nakai A *see* Kasuga Y *et al.*
Nakajima T *see* Moriyama H *et al.*
Nakamura K *see* Yumoto E *et al.*
Nakamura M *see* Sakakura A *et al.*
Nakamura N *see* Kosaki H *et al.*
Nakamura Node M *see* Minatogawa T *et al.*
Nakanishi R, Shimazu A, Mitsudomi T, Masuda T, Osaki T, Onimura S, Shigematsu A, Sata T, Urano H, Yasumoto K, Successful management of tracheo-innominate artery fistula using interposition of a thymus pedicle flap. *Clin. Rec.* **109**: 161
Nakanoboh M *see* Kitahara S *et al.*
Nakashima T, Nakashima T, Masuda M, Komiyama S, P53 and bcl-2 expression and argyrophilic nucleolar organizer regions in patients with malignant maxillary sinus tumours. *Orig. Art.* **111**: 38
Nakashima T, Tanaka M, Okamura S, Survey of immunosuppressive acidic protein and other immunological parameters in head and neck cancer patients. *Orig. Art.* **105**: 939
Nakashima T, *see also* Inamitsu M *et al.*; Sone M *et al.*; Yasumoto K *et al.*
Nakatani Y *see* Mochimatsu I *et al.*
Nakayama M *see* Kawashima O *et al.*
Nakhla V, A homemade modification of a spacer device for delivery of bronchodilator or steroid therapy in patients with tracheostomies. *Short Comm.* **111**: 363
Nakhla V, *see also* Abadir WF *et al.*
Nalinesha KM *see* Dutt SN *et al.*; Hasan S *et al.*
Namyslowski G *see* Misiolek M *et al.*
Nandapalan V, McIlwain JC, Removal of nasal foreign bodies with a Fogarty biliary balloon catheter. *Orig. Art.* **108**: 758
Nandapalan V, McIlwain JC, England J, Amylase activity in tracheobronchial secretions of laryngectomized patients. *Orig. Art.* **109**: 637
Nandapalan V, McIlwain JC, Hamilton J, A study of alpha-amylase activity in tracheobronchial secretions of seriously ill patients with tracheostomies. *Orig. Art.* **109**: 640
Nandapalan V, O'Sullivan DG, Siodlak M, Charters P, Acute airway obstruction due to ruptured aneurysmal arterio-venous fistula: common carotid artery to internal jugular vein. *Clin. Rec.* **109**: 562
Nandapalan V, Smith CA, Jones AS, Lesser THJ, Objective measurement of the benefit of walking sticks in peripheral vestibular balance disorders, using the sway weigh balance platform. *Orig. Art.* **109**: 836
Nandapalan V, Tos M, Isolated congenital stapes suprastructure fixation. *Orig. Art.* **113**: 798
Nandapalan V *see also* Carney and Nandapalan; Papakostas K *et al.*
Nanivadekar SA *see* Bhargava KB *et al.*
Nanjundappa A *see* Shenoy AM *et al.*
Nanjundappa M *see* Shenoy AM *et al.*
Nanjundappa MS *see* Hasan S *et al.*
Napier SS *see* Menown IBA *et al.*
Narayan S *see* Bais AS *et al.*
Narayana HM, Panda NK, Mann SBS, Katariya S, Visishta RK, Ultrasound versus physical examination in staging carcinoma of the mobile tongue. *Orig. Art.* **110**: 43
Naresh KN *see* Hasan S *et al.*
Narula AA *see* Clark LJ *et al.*; Reilly PG *et al.*; White and Narula
Nasir AM *see* Rajab E *et al.*
Nass D *see* Kaplan HY *et al.*
Nassar WY *see* de Carpentier JP *et al.*; Pace-Balzan A *et al.*; Ramamurthy L *et al.*
Nassif OI *see* Daghistani KJ *et al.*
Natale AS *see* Magliulo G *et al.*
Natarajan B, Baxter A, Preparation of a temporal bone exhibit. *Rev. Art.* **108**: 9
Natarajan B, Johnstone A, Sheikh S, Palmer O, Hari Madhavan KN, Unilateral anterior jugular phlebectasia. *Clin. Rec.* **108**: 352
Natarajan B, Richardson MD, Irvine BWH, The Provox voice prosthesis and candida vegetations: a preliminary report of clinical, mycological and scanning electron microscopic assessment. *Prelim. Comm.* **108**: 666
Natarajan B, Townsley P, Irvine BW, Mansfield M, Self-inflicted laryngo-pharyngectomy: a case report. *Clin. Rec.* **108**: 252
Natarajan B, *see also* Al-Khabori MJJ *et al.*; Palmer O *et al.*; Thomas MR *et al.*
Nath F *see* Nair SB *et al.*
Natvig K, Boysen M, Tausjø J, Fistulas following laryngectomy in patients treated with irradiation. *Orig. Art.* **107**: 1136
Nauta JJP *see* Patel P *et al.*
Navacharoen N *see* Kangsanarak J *et al.*
Navarette ML, Quesada P, Garcia M, Lorente J, Acute epiglottitis in the adult. *Orig. Art.* **105**: 839
Navarrete ML, Quesada P, Pellicer M, Ruiz C, Extramedullary nasal plasmacytoma. *Clin. Rec.* **105**: 41
Navarro Cunchillos M, Bonachera C, Navarro Cunchillos M, Cassinello E, Ramos Lizana J, Oña Esteban J, Middle ear teratoma in a newborn. *Clin. Rec.* **110**: 875
Navarro Cunchillos M, Villanueva Marcos JL, Torre-Cisneros J, Ostos Aumente P, López-Rubio F, López Villarejo P, Isolated laryngeal leishmaniasis in an immunocompetent patient: successful treatment with surgery. *Clin. Rec.* **108**: 249
Navas C *see* Plaza G *et al.*
Naxakis SS *see* Goumas P *et al.*
Nayak DR, Balakrishnan R, Murthy KD, An endoscopic approach to the deviated nasal septum: a preliminary study. *Orig. Art.* **112**: 934
Nayak DR, *see also* Hazarika P *et al.*; Puranik KR *et al.*
Nayak SR, Kirtane MV, Ingle MV, Fracture line in post head injury optic nerve damage. *Orig. Art.* **105**: 203
Nayak SR, Kirtane MV, Ingle MV, Transethmoid decompression of the optic nerve in head injuries: an update. *Orig. Art.* **105**: 205
Nayak SR, *see also* Bhattacharyya AK *et al.*; Mankekar G *et al.*
Nayak UK *see* Shenoy AM *et al.*
Nayar RC, Garg I, Alapatt JJ, Malakoplakia of the temporal bone in a nine-month-old infant. *Clin. Rec.* **105**: 568
Nayar RC, *see also* Dutt SN *et al.*; Raju KGS *et al.*
Nayyar S *see* Drake-Lee A *et al.*
Neal AJ, Habib F, Hope-Stone HF, Carcinoma of the maxillary antrum treated by pre-operative radiotherapy or radical radiotherapy alone. *Orig. Art.* **106**: 1063
Neary WJ, Newton VE, Laoide-Kemp SN, Ramsden RT, Griffith G, Evans DG, Harris R, Strachan T, A clinical, genetic and audiological study of patients and families with unilateral vestibular schwannomas. I. Clinical features of neurofibromatosis in patients with unilateral vestibular schwannomas. *Orig. Art.* **110**: 634
Neary WJ, Newton VE, Laoide-Kemp SN, Ramsden RT, Hillier VF, Kan SW, A clinical, genetic and audiological study of patients and families with unilateral vestibular schwannomas. II Audiological findings in 93 patients with unilateral vestibular schwannomas. *Orig. Art.* **110**: 1120
Neary WJ, Newton VE, Vidler M, Ramsden RT, Lye RH, Dutton JEM, Richardson PL, Harris R, Evans DG, Strachan T, A clinical, genetic and audiological study of patients and families with bilateral acoustic neurofibromatosis. *Orig. Art.* **107**: 6
Neetens I *see* Van Laer C *et al.*
Nehru VI, Al-Khaboori MJJ, Kishore K, Ligation of the internal jugular vein in venous hum tinnitus. *Clin. Rec.* **107**: 1037
Nehru VI, *see also* Srinivasan S *et al.*
Neilly IJ, Dawson AA, Russell D, Laing MR, Non-Hodgkins lymphoma of the head and neck: experience in the Grampian area. *Orig. Art.* **104**: 972
Neri A *see* Capaccio P *et al.*; Pignataro L *et al.*
Nettelbladt U *see* Harsten G *et al.*
Netzer A *see* Golz A *et al.*
Newbegin CJR *see* Martin-Hirsch and Newbegin
Newton V, Hearing loss and Waardenburg's syndrome: Implications for genetic counselling. *Orig. Art.* **104**: 97
Newton V, *see also* Liu X *et al.*
Newton VE, Sensorineural hearing loss and the Marinesco-Sjögren syndrome. *Clin. Rec.* **105**: 210

Newton VE, Hillier VF, Stephens SDG, Prescription of hearing aids for the elderly. The views of general practitioners. *Orig. Art.* **106**: 963
Newton VE, *see also* Neary WJ *et al.*
Ng HK *see* Van Hasselt and Ng
Ng KH, Siar CH, A clinicopathological and immunohistochemical study of the calcifying epithelial odontogenic tumour (Pindborg tumour) in Malaysians. *Orig. Art.* **110**: 757
Ng KH, *see also* Siar CH *et al.*; Siar and Ng
Ngan KC *see* Tsang YW *et al.*
Ngayama I, Nishimura T, Furukawa M, Malignant schwannoma arising in a paranasal sinus. *Clin. Rec.* **107**: 146
Ngui CH *see* Siar CH *et al.*
Nicholls JM, Chua D, Chiu PM, Kwong DLW, The detection of clinically occult nasopharyngeal carcinoma in patients following radiotherapy - an analysis of 69 patients. *Path. Focus* **110**: 496
Nichols C, Geist RY, Nichols K, Clear cell neoplasm. *Clin. Rec.* **106**: 553
Nichols K *see* Nichols C *et al.*
Nicol A *see* Srinivasan V *et al.*
Nicol JW, Yardley MPJ, Parker AJ, Pharyngolaryngeal migration: a delayed complication of an impacted bullet in the neck. *Clin. Rec.* **106**: 1091
Nicol W, Stables GI, MacKenzie K, Histiocytosis: an unusual cause of dysphagia, hoarseness and stridor. *Clin. Rec.* **107**: 1061
Nicolaides AR, Silver tracheostomy tube obturator in the tracheobronchial tree. *Clin. Rec.* **104**: 437
Nicolaides AR, *see also* Lee SJ *et al.*; Robertson A *et al.*
Nicollas R *see* Triglia J-M *et al.*
Niebuhr M *see* Stangerup S-E *et al.*
Niedobitek G *see* Dhaliwal J *et al.*
Nield DV *see* Montgomery PQ *et al.*
Nielsen OA *see* Walsted A *et al.*
Nielsen TG *see* Andreassen UK *et al.*
Nielsen TR, Andreassen UK, Brown CL, Balle VH, Thomsen J, Microsurgical technique in thyroid surgery: a 10-year experience. *Orig. Art.* **112**: 556
Nielsen TR, Clement F, Andreassen UK, Mediastinitis — a rare complication of a peritonsillar abscess. *Clin. Rec.* **110**: 175
Niemelä M, Uhari M, Lautala P, Huggare J, Association of recurrent acute otitis media with nasopharynx dimensions in children. *Orig. Art.* **108**: 299
Nieminen P, Silvola J, Aust R, Stenfors L-E, Nasal septal surgery as an out-patient procedure. *Orig. Art.* **111**: 1034
Nigam A, Campbell JB, Das Gupta AR, Radiation-induced tumours of the pharynx – can they be avoided? *Orig. Art.* **104**: 129
Nigam A, Das-Gupta AR, Pyoderma gangrenosum and progressive sensori-neural deafness. *Clin. Rec.* **108**: 671
Nigam A, Johnson AP, Suction polypectomy forceps. *Short Comm.* **107**: 35
Nigam A, Ruddy J, Robin PE, BIPP induced methaemoglobinaemia. *Orig. Art.* **105**: 78
Nigam A, Samuel PR, Hyperacusis and Williams syndrome. *Clin. Rec.* **108**: 494
Nigam A, *see also* Makura and Nigam; Samuel PR *et al.*
Niimi S *see* Lee and Niimi
Niinimäki A *see* Kujala V *et al.*
Nikaido M *see* Suzuki M *et al.*
Nikolaou A, Bourikas Z, Maltas V, Aidonis A, Ossiculoplasty with the use of autografts and synthetic prosthetic materials: a comparison of results in 165 cases. *Orig. Art.* **106**: 692
Nikolaou A, Daniilidis J., Fountzilas G, Kouloulas A, Sombolos K, Velegrakis G, Supraglottic laryngectomy: experience with 66 patients over 20 years. *Orig. Art.* **107**: 813
Nikolaou A, Fountzilas G, Kosmidis P, Banis C, Sombolos K, Daniilidis J, Laryngeal preservation in cases of advanced laryngeal cancer treated with platinum based induction chemotherapy before local treatment. *Orig. Art.* **105**: 930
Nikolaou A, *see also* Daniilidis J *et al.*
Nikolaou AC, Fountzilas G, Daniilidis I, Treatment of unresectable recurrent head and neck carcinoma with 13-cis-retinoic acid and interferon-alpha: a phase II study. *Orig. Art.* **110**: 857
Nikolopoulos TP *see* Kandiloros DC *et al.*
Nilssen E, Wormald PJ, The role of MIBG scintigraphy in the management of a case of metastatic glomus jugulare tumour. *Clin. Rec.* **110**: 373
Nilssen E, Wormald PJ, Oliver S, Glycerol and ichthammol: medicinal solution or mythical potion? *Orig. Art.* **110**: 319
Nilssen ELK, Murthy P, McClymont L, Denholm S, Radiological staging of the chest and abdomen in head and neck squamous cell carcinoma — are computerized tomography and ultrasound necessary? *Orig. Art.* **113**: 152
Nilssen ELK, Wormald PJ, Facial nerve palsy in mastoid surgery. *Orig. Art.* **111**: 113
Nilssen ELK, *see also* Holland S *et al.*; Mortimore S *et al.*; Thorp MA *et al.*
Nimura Y *see* Kasuga Y *et al.*
Ninnin D *see* Gregor and Ninnin
Nir D, Nir T, Danino J, Joachims HZ, Malignant external otitis in an infant. *Clin. Rec.* **104**: 488
Nir D, *see also* Hefer T *et al.*
Nir T *see* Nir D *et al.*
Nirmala V *see* Kaur A *et al.*
Nishida I *see* Suzuki M *et al.*
Nishimura G, Tsukuda M, Zhou L-X, Furukawa S, Baba Y, Cyclin D1 expression as a prognostic factor in advanced hypopharyngeal carcinoma. *Orig. Art.* **112**: 552
Nishimura T, Furukawa M, Kawahara E, Pleomorphic adenoma of parotid gland with cystic degeneration. *Path. Focus* **108**: 446
Nishimura T, Furukawa M, Kawahara E, Miwa A, Differential diagnosis of pleomorphic adenoma by immunohistochemical means. *Orig. Art.* **105**: 1057
Nishimura T, *see also* Ngayama I *et al.*; Okabe Y *et al.*; Takimoto T *et al.*; Wen QH *et al.*
Nishiyama Y *see* Hisa Y *et al.*
Nishizaki K *see* Kariya S *et al.*
Nissen F *see* Buchwald C *et al.*
Nistal M *see* Bernáldez R *et al.*
Nixon DD *see* Mesko TW *et al.*
Nixon TE *see* Pothula VB *et al.*
Nobori T *see* Itoh K *et al.*
Nobuto Y *see* Li D-J *et al.*
Nofal F, Moran M, Long distance travel by children for tonsillectomy. *Short Comm.* **104**: 417
Nofal F, Thomas M, Rhinomanometry evaluation of the effects of pre and post-operative SMR on exercise. *Orig. Art.* **104**: 126
Nofal F, *see also* Thomas MR; Thomas MR *et al.*
Noghreyan A, Gatot A, Maor E, Fliss DM, Palatal pleomorphic adenoma in a child. *Clin. Rec.* **109**: 343
Noguchi T *see* Yamashita Y *et al.*
Noguchi Y, Komatsuzaki A, Yamada I, Okuno H, Haraguchi H, Vestibular schwannoma showing a dural tail on contrast-enhanced magnetic resonance images. *Rad. Focus* **111**: 877
Nomicos P *see* Xenellis J *et al.*
Nomoto M, Nagao K, Numata T, Konno A, Kaneko T, Synovial osteochondromatosis of the temporo-mandibular joint. *Clin. Rec.* **107**: 742
Nomura M *see* Ishimaru T *et al.*
Nonomura A *see* Yoshizaki T *et al.*
Noor AR *see* Indudharan R *et al.*
Norbash A *see* Williams Z *et al.*
Nordahl SHG, Hoel T, Olofsson J, Scheel O, Tularemia: a differential diagnosis in oto-rhino-laryngology. *Orig. Art.* **107**: 127
Nordet D *see* Dueñas L *et al.*
Nordman E *see* Joensuu H *et al.*
Norman L, Bateman AC, Watters GWR, Singh V, Spedding AV, Rosal-Dorfman disease presenting as a parotid mass. *Path. Focus* **111**: 1091
Norré ME, Sensory interaction testing in platform posturography. *Orig. Art.* **107**: 496
Norval C *see* Koay and Norval
Nosaka K *see* Tsunoda K *et al.*
Noshimura T, Takimoto T, Ishikawa S, Ohmura K, Venous haemangioma of the neck and mediastinum. *Rad. Focus* **105**: 386
Noyek A *see* Feinmesser R *et al.*
Noyek AM *see* Feinmesser R *et al.*
Numata T *see* Nomoto M *et al.*
Nunez DA *see* El-Hakim and Nunez
Nunez DA, Astley S, Lewis FA, Wells M, Human papilloma viruses: study of their prevalence in the normal larynx. *Orig. Art.* **108**: 319

Nunez DA, Browning GG, Risks of developing an otogenic intracranial abscess. *Orig. Art.* **104**: 468
Nunez DA, *see also* Hawthorne MR *et al.*; Soo and Nunez
Núñez-Fernández D, Vokurka J, Chrobok V, Bone and temporal fascia graft for the closure of septal perforation. *Orig. Art.* **112**: 1167
Nuutinen J, Kansanen M, Syrjänen K, Bilateral acinic cell tumours of the parotid gland. *Path. Focus* **105**: 796
Nuutinen J, *see also* Toskala E *et al.*; Valtonen H *et al.*; Vartiainen E *et al.*; Virtaniemi J *et al.*
Nwachokor RN *see* Nwaorgu OGB *et al.*
Nwaorgu OGB, Akang EEU, Ahmad BM, Nwachokor RN, Olu-Eddo AN, Pharyngeal lipoma with cartilaginous metaplasia (chondrolipoma): a case report and literature review. *Clin. Rec.* **111**: 656
Nye KJ *see* Kuo MJ *et al.*
Nykänen K *see* Vartiainen E *et al.*
Nyrop M, Kimura's disease: case report and brief review of the literature. *Clin. Rec.* **108**: 1005
Nyrop M, Bjerre PK, Christensen J, Jørgensen KE, Extensive and symptomatic cranial pneumatization: caused by frequent performance of Valsalva's manoeuvre. *Rad. Focus* **113**: 480
Nyrop M, Bonding P, Extensive cholesteatoma: long-term results of three surgical techniques. *Orig. Art.* **111**: 521

Oates J *see* Bhat and Oates; Hughes and Oates; Lim PVM *et al.*; Trendell-Smith NJ *et al.*
Occhiuzzi L *see* Cavicchi O *et al.*
Ochi JW *see* Jani P *et al.*
Ochoa LF, Duque CS, Velez A, Rhinoentomophthoromycosis: report of two cases. *Clin. Rec.* **110**: 1154
O'Connell JE, Calder C, Raafat F, Proops D, Ewing's sarcoma of the retropharynx. *Path. Focus* **108**: 363
O'Connel J *see* Wilson PS *et al.*
O'Connell JE, Lateral sinus thrombosis: a problem still with us. *Orig. Art.* **104**: 949
O'Connell JE, George MK, Speculand B, Pahor AL, Mycobacterial infection of the parotid gland: an unusual cause of parotid swelling. *Clin. Rec.* **107**: 561
O'Connell JE, Robin PE, Eyelid gold weights in the management of facial palsy. *Orig. Art.* **105**: 471
O'Connell JE, Turner NO, Pahor AL, Air gun pellets in the sinuses. *Clin. Rec.* **109**: 1097
O'Connell JE, *see also* George MK *et al.*; Weiner GM *et al.*
O'Connell JM *see* Hinton AE *et al.*
O'Connell M *see* Al-Shahi R *et al.*
O'Connor Reina C, Iriarte MTG, Reyes FJB, Monge EG, Barona RL, Angel DG, When is a biopsy justified in a case of relapsing polychondritis? *Clin. Rec.* **113**: 663
O'Donoghue GM, Koyunchu M, First European symposium on paediatric cochlear implantation **106**: 1109
O'Donoghue GM, *see also* Jennings and O'Donoghue; Saleh HA *et al.*
O'Driscoll K *see* Matin MA *et al.*
O'Driscoll M *see* Maas S *et al.*; Mawman DJ *et al.*
Odutoye T *see* Harmse JL *et al.*
O'Dwyer T *see* Conlon and O'Dwyer
O'Dwyer TP *see* Conlon and O'Dwyer; Curran AJ *et al.*; Fenton JE *et al.*; Gaffney RJ *et al.*; Lacy PD *et al.*; Rowley H *et al.*
Offeciers E *see* Somers T *et al.*
Offiah CJ, Endres D, Isolated laryngotracheal separation following blunt trauma to the neck. *Clin. Rec.* **111**: 1079
O'Flynn P *see* Bath AP *et al.*; Mason J *et al.*; Reece PH *et al.*; Saleh and O'Flynn; Soussi AC *et al.*
O'Flynn PE, Milford CA, Mackay LS, Multiple submucosal outfractures of inferior turbinates. *Short Comm.* **104**: 239
O'Flynn PE, *see also* Akhtar S *et al.*; Lloyd RV *et al.*
Ogale SB, Dutt SN, Thakur S, Pawar M, The styloid process in ossicular chain reconstruction. II: Long-term analysis. *Orig. Art.* **108**: 111
Ogawa H, Hashiguchi K, Kazuyama Y, Prolonged and recurrent tonsillitis associated with sexually transmitted *Chlamydia trachomatis*. *Orig. Art.* **107**: 27
Ogawa H, Hashiguchi K, Kazuyama Y, Recovery of *Chlamydia pneumoniae* in six patients with otitis media with effusion. *Orig. Art.* **106**: 490
Ogawa H, *see also* Hashiguchi K *et al.*
Öğretmenoğlu O *see* Önerci M *et al.*
Ogura M *see* Takayama E *et al.*
Oğuz A *see* Aydin Ö *et al.*
O'Halpin DR *see* Quraishi and O'Halpin
O'Hanlon DM, Walsh N, Corry J, Mortimer G, Flynn JR, Aberrant thyroglossal cyst. *Clin. Rec.* **108**: 1105
O'Hara MD *see* McCluggage WG *et al.*
Ohashi N, Yasumura S, Nakagawa H, Mizukoshi K, Kuze S, Vascular cross-compression of the VIIth and VIIIth cranial nerves. *Clin. Rec.* **106**: 436
Ohgaki T *see* Haraguchi H *et al.*
Ohguro S, Himi T, Harabuchi Y, Suzuki T, Asakura K, Kataura A, Adult T-cell leukaemia–lymphoma in Waldeyer's ring: a report of three cases. *Clin. Rec.* **107**: 960
O'Higgins P *see* Lannigan FJ *et al.*
Ohkubo K *see* Otsuka H *et al.*
Ohmae Y *see* Kitahara S *et al.*
Ohmichi T *see* Lai M-T *et al.*
Ohmori T *see* Ikeda M *et al.*
Ohmura K *see* Noshimura T *et al.*
Ohnishi M *see* Otsuka H *et al.*
Ohoka H *see* Okabe Y *et al.*; Takimoto T *et al.*
Ohri A *see* Cumberworth VL *et al.*
Ohri AK, Makins R, Smith CET, Leopold PW, Primary branchial cleft carcinoma - a case report. *Clin. Rec.* **111**: 80
Ohri AK, Ohri SK, Singh MP, Evidence for thyroid development from the fourth branchial pouch. *Clin. Rec.* **108**: 71
Ohri SK *see* Ohri AK *et al.*
Ohsaki K *see* Cui P-C *et al.*; Li D-J *et al.*
Ohta Y *see* Ichimura K *et al.*
Ohtani I *see* Murakami M *et al.*
Ohyama M *see* Deguchi K *et al.*; Itoh K *et al.*
Okabe Y, Ohoka H, Miwa T, Nagayama I, Furukawa M, Renal cell carcinoma metastasis to the tongue. *Path. Focus* **106**: 282
Okabe Y, Shibutani K, Nishimura T, Chondrosarcoma of the parapharyngeal space. *Clin. Rec.* **105**: 484
Okabe Y, *see also* Nagayama I *et al.*
Okafor BC *see* Kameswaran M *et al.*; Sheikha A *et al.*; Thomas R *et al.*
Okamura S *see* Nakashima T *et al.*
O'Keefe L *see* Dawes PJD *et al.*
O'Keefe LJ, Maw AR, Sudden total deafness in sickle cell disease. *Clin. Rec.* **105**: 653
O'Keefe LJ, Maw AR, The dangers of minor blunt laryngeal trauma. *Clin. Rec.* **106**: 372
O'Keeffe L, *see also* Birzgalis AR *et al.*
O'Keeffe LJ, Camilleri AE, Gillespie JE, Cairns A, Ramsden RT, Primary tumours of the vestibule and inner ear. *Orig. Art.* **111**: 709
O'Keeffe LJ, Ramsden RT, Birzgalis AR, Primary synovial sarcoma of the middle ear. *Path. Focus* **107**: 1071
O'Keeffe LJ, Ramsden RT, Birzgalis AR, Cerebellopontine angle lipoma. *Clin. Rec.* **107**: 553
Oklek K *see* Misiolek M *et al.*
Okoth-Olende CA *see* Bjerregaard B *et al.*
Oku T *see* Tsutsumi T *et al.*
Okuno H *see* Noguchi Y *et al.*
Ole-Lengine L, Manni JJ, A strangulated antrochoanal polyp: a case report. *Clin. Rec.* **107**: 342
O'Leary IK *see* Parker AJ *et al.*
O'Leary SJ, Gibson WP, Surviving cochlear function in the presence of auditory nerve agenesis. *Clin. Rec.* **113**: 1008
Oliff J *see* Raj P *et al.*
Olina M *see* Pisani P *et al.*
Oliver S *see* Mortimore S *et al.*; Nilssen E *et al.*; Thorp MA *et al.*
Olliff J *see* Hogg RP *et al.*
Olofsson J *see* el-Saggan A *et al.*; Nordahl SHG *et al.*
Olsen EG, Stenfors L-E, The behaviour of tympanic membrane perforations in tissue culture: a scanning electron microscopic study. *Orig. Art.* **107**: 1106
Olsen EG, *see also* Stenfors LE *et al.*
Olsson B *see* Lagerholm S *et al.*
Olu-Eddo AN *see* Nwaorgu OGB *et al.*
Oluwole M *see* Gardiner Q *et al.*; Ram B *et al.*
Oluwole MO, Hanif H, Proptosis following nasal tamponade. *Clin. Rec.* **110**: 265
O'Malley S *see* Commins DJ *et al.*; James AL *et al.*
Omerod A *see* Clark LJ *et al.*
Oña Esteban J *see* Navarro Cunchillos M *et al.*

Önal K *see* Öncel S *et al.*
Öncel S, Doğanay M, Özer A, Arslanoğlu S, Ermete M, Erdoğan N, Leiomyosarcoma of the parotid gland. *Path. Focus* **110**: 401
Öncel S, Hasegeli L, Zafer Uğuz M, Savaci S, Önal K, Oyman S, The effect of epidural anaesthesia and size of spinal needle on post-operative hearing loss. *Orig. Art.* **106**: 783
Önder T, Tiwari RM, van der Waal I, Snow GB, Malignant adenolymphoma of the parotid gland: report of carcinomatous transformation. *Clin. Rec.* **104**: 656
Önder T, *see also* Dündar A *et al.*; Günhan O *et al.*
O'Neill PM *see* Lee WC *et al.*
Önerci M, Öğretmenoğlu O, Yilmaz T, Glass in the frontal sinus: report of three cases. *Clin. Rec.* **111**: 156
Önerci M, *see also* Şener B *et al.*; Sennaroğlu L *et al.*; Sözeri B *et al.*
Ong CC, Elton PG, Mitchell D, Pharyngeal pouch endoscopic stapling — are post-operative barium swallow radiographs of any value? *Orig. Art.* **113**: 233
Ong PS *see* Quinn SJ *et al.*
Onimura S *see* Nakanishi R *et al.*
Ono M *see* Kaga K *et al.*
Onoda K *see* Ikeda M *et al.*
Van Oosterom A *see* Van Laer C *et al.*
Ophir D, Familial multicentric paragangliomas in a child. *Clin. Rec.* **105**: 376
Ophir D, Ruchvarger E, Cordoba M, Angioleiomyoma of the nasal tip. *Clin. Rec.* **107**: 448
Ophir D, *see also* Berger G *et al.*; Goshen and Ophir
Ordóñez NG *see* El-Naggar AK *et al.*
O'Regan MB *see* James PL *et al.*
O'Reilly BJ, Burrows EH, VIIIth cranial nerve involvement in sarcoidosis. *Clin. Rec.* **109**: 1089
O'Reilly BJ, Chevretton EB, Wylie L, Thakkar C, Butler P, Sathanathan N, Morrison GA, Kenyon GS, The value of CT scanning in chronic suppurative otitis media. *Orig. Art.* **105**: 990
O'Reilly BJ, Kenyon GS, A double-blind, placebo-controlled trial of beclomethasone dipropionate 600 microgram/day in the treatment of non-atopic rhinitis. *Orig. Art.* **105**: 12
O'Reilly BJ, Matthews DO, Teeth in the neck. *Rad. Focus* **104**: 913
O'Reilly BJ, Walter C, Total avulsion of an osseointegrated screw. *Clin. Rec.* **105**: 573
O'Reilly BJ, *see also* Daum and O'Reilly; Morrison GAJ *et al.*; Osei-Lah V *et al.*
Orlin J *see* Finkelstein Y *et al.*
Orr WP *see* Dilkes MG *et al.*
Orton CI *see* Ramamurthy L *et al.*
Orzan E *see* Stephens D *et al.*
Osaki T *see* Nakanishi R *et al.*
Osammor JY, Bulman CH, Blewitt RW, Intralaryngeal tracheal thyroid. *Clin. Rec.* **104**: 733
Osammor JY, Howat AJ, Nasal haemangiopericytoma. *Path. Focus* **105**: 593
Osborne J, Jenkins J, Sparkes C, Bilingual hearing acquisition in Welsh and English following cochlear implantation. *Clin. Rec.* **110**: 776
Osborne J, *see also* Heaton JM *et al.*
Osborne JE, Osman EZ, Cuddihy P, Ranta M, Tracheal ring herniation following percutaneous dilatational tracheostomy and its resection under endoscopic control. *Clin. Rec.* **113**: 1116
Osei-Lah V, O'Reilly BK, Capildeo R, Bilateral abductor vocal fold paralysis due to myasthenia gravis. *Clin. Rec.* **113**: 678
Osiname AI *see* Ajulo SO *et al.*; Osinubi OA *et al.*
Osinubi OA, Osiname AI, Pal A, Lonsdale RJ, Butcher C, Foreign body in the throat migrating through the common carotid artery. *Clin. Rec.* **110**: 793
Osma Ü, Cüreoğlu S, Akbulut N, Meric F, Topcu İ, The results of septal button insertion in the management of nasal septal perforation. *Orig. Art.* **113**: 823
Osman EZ *see* Osborne JE *et al.*
Osterberg P *see* Adams DA *et al.*
Ostfeld EJ, Kupferberg A, Biocompatible implantable antimicrobial release for necrotising external otitis. *Orig. Art.* **105**: 252
Ostfeld EJ, Wiesel JM, Rabinson S, Auslander L, Parapharyngeal (retrostyloid)-third branchial cleft cyst. *Clin. Rec.* **105**: 790
Ostos Aumente P *see* Navarro Cunchillos M *et al.*
Ostyn F *see* Debruyne F *et al.*
O'Sullivan A *see* Davies R *et al.*
O'Sullivan DG *see* Alderson and O'Sullivan; Nandapalan V *et al.*
O'Sullivan G *see* Papakostas K *et al.*
O'Sullivan GJ *see* Worley GA *et al.*
O'Sullivan TJ *see* Fenton and O'Sullivan
Oswal V *see* El-Naggar M *et al.*
Oswal VH *see* Hampal and Oswal; Robson NLK *et al.*
Othman EO *see* Kamal and Othman
Othman NH *see* Sharma HS *et al.*
Otsuka H, Ohkubo K, Seki H, Ohnishi M, Fujikura T, Mast cell quantitation in nasal polyps, sinus mucosa and nasal turbinate mucosa. *Orig. Art.* **107**: 418
Ottaviani A *see* Capaccio P *et al.*; Pignataro L *et al.*
Ottaviani F *see* Almadori G *et al.*; Cadoni G *et al.*; Del Forno A *et al.*
Outzen KE, Ilium P, CO_2-laser therapy for carcinoma of the larynx. *Orig. Art.* **109**: 111
Overgaard E *see* Johansen M *et al.*
Owa AO, Farrell RWR, Simple model for teaching myringotomy and aural ventilation tube insertion. *Short Comm.* **112**: 642
Owa AO, Gallimore AP, Ajulo SO, Cheesman AD, Metastatic adenocarcinoma of the ethmoids in a patient with previous gastric adenocarcinoma: a case report. *Clin. Rec.* **109**: 759
Owa AO, Zaman A, Farrell RWR, Bull TR, An unusual complication of augmentation rhinoplasty: late displacement of dorsal nasal splint. *Clin. Rec.* **113**: 358
Owada M *see* Kaga K *et al.*
Owen G, Berry J, Bicknell P, Hamartoma of the tongue. *Path. Focus* **107**: 363
Owen GO *see* Jones TM *et al.*
Owen RA *see* Ganesan S *et al.*
Oyarzabal MF, Patel KS, Tolley NS, Bilateral acute mastoiditis complicated by lateral sinus thrombosis. *Clin. Rec.* **106**: 535
Oyman S *see* Öncel S *et al.*
Özer A *see* Öncel S *et al.*
Ozkan F *see* Tuzuner N *et al.*
Ozkan S *see* Sennaroğlu L *et al.*
Özkarakas H *see* Aydin Ö *et al.*
Özoran Y *see* Yildiz K *et al.*
Öztürk A *see* Selimoğlu E *et al.*; Sutbeyaz Y *et al.*
Öztürk M *see* Güney E *et al.*; Külahli I *et al.*
Ozturkcan S *see* Kunt T *et al.*
Özünlü A, Dündar A, Satar B, Günhan Ö, Laryngeal paraganglioma — a review and report of a single case. *Rev. Art.* **110**: 519
Özünlü A *see* Dündar A *et al.*
Özyar E, Kiratli H, Akbulut S, Uzal D, Atahan IL, Choroid metastasis of undifferentiated nasopharyngeal carcinoma. *Clin. Rec.* **112**: 667

Paalassalo P *see* Lauerma and Paalassalo
Pace-Balzan A, Keith AO, Curley JWA, Ramsden RT, Lewis H, Otogenic *Fusobacterium necrophorum* meningitis. *Clin. Rec.* **105**: 119
Pace-Balzan A, Habashi SMZ, Nassar WY, Lateral pharyngeal diverticulum. *Rad. Focus* **105**: 793
Pace-Balzan A, Hawke M, Exostosis of the external auditory canal: an interesting histopathological finding. *Clin. Rec.* **105**: 844
Pace-Balzan A, Rutka JA, Non-ampullary plugging of the posterior semicircular canal for benign paroxysmal positional vertigo. *Orig. Art.* **105**: 901
Pacini P *see* Gulisano M *et al.*
Paczona R, A cadaver larynx holder for teaching laryngomicrosurgery. *Clin. Rec.* **111**: 56
Padel AF *see* Graham CT *et al.*
Padgham ND, Bingham BJG, Purdue BN, Episodic macroglossia in Down's syndrome. *Clin. Rec.* **104**: 494
Padgham ND, Epistaxis: anatomical and clinical correlates. *Orig. Art.* **104**: 308
Padgham ND, *see also* Mills and Padgham; Mills RP *et al.*; Parham and Padgham; Vaughan-Jones RH *et al.*
Page R *see* Dutton JEM *et al.*; Martin-Hirsch DP *et al.*
Pagliari AV *see* Capaccio P *et al.*
Pahade A, Green KMJ, de Carpentier JP, Non-cardiogenic pulmonary oedema due to foreign body aspiration. *Clin. Rec.* **113**: 1119
Pahl S, Puschel W, Federspil P, Cystadenoma of the parotid gland with unusual prominent lymphoid stroma. *Path. Focus* **111**: 883

Pahor AL, Ear, nose and throat in Ancient Egypt. Part I. *Hist. Art.* **106**: 677
Pahor AL, Ear, nose and throat in Ancient Egypt. Part II. *Hist. Art.* **106**: 773
Pahor AL, Ear, nose and throat in Ancient Egypt, Part III. *Hist. Art.* **106**: 863
Pahor AL, Cole J, The Birmingham Mummy: the first torticollis in history. *Hist. Art.* **109**: 273
Pahor AL, Hussain SSM, Persistent stapedial artery. *Clin. Rec.* **106**: 254
Pahor AL, Sament S, Retropharyngeal myxoma: a case report. *Clin. Rec.* **108**: 690
Pahor AL, Stansbie JM, The Midlands Institute of Otology and its founder: William Stirk Adams (1896-1978). *Hist. Art.* **111**: 1122
Pahor AL, *see also* Adams WM *et al.*; Agius AM *et al.*; Chavda and Pahor; Daud and Pahor; Dowell and Pahor; George MK *et al.*; Jones RL *et al.*; Mansour P *et al.*; O'Connell JE *et al.*; Patel K *et al.*; Rassl and Pahor; Shehab and Pahor; Shehab Z *et al.*; Tewary and Pahor; Umaria N *et al.*; Violaris and Pahor; Weiner GM *et al.*; Weiner and Pahor; Whallett and Pahor
Paiva A *see* Xavier R *et al.*
Pak MW, Chan ESY, van Hasselt CA, Late complications of nasal augmentation using silicone implants. *Clin. Rec.* **112**: 1074
Pak MW, Chan KL, van Hasselt CA, Retropharyngeal abscess. A rare presentation of nasopharyngeal carcinoma. *Clin. Rec.* **113**: 70
Pak MW, Mak HKF, Ku PKM, van Hasselt CA, Dural metastasis at medulla oblongata: a rare cause of vocal fold paralysis. *Clin. Rec.* **110**: 884
Pak MW, Woo JKS, van Hasselt CA, Congenital laryngeal cysts: current approach to management. *Orig. Art.* **110**: 854
Pak MW *see also* Ku PKM *et al.*
Pal A *see* Osinubi *et al.*; Osinubi OA *et al.*
Palaiologos Y *see* Simaskos N *et al.*
Palcic B *see* Harries MLL *et al.*
Palmer CR *see* Fisher EW *et al.*
Palmer O *see* Natarajan B *et al.*
Palmer P, Natarajan B, Johnstone A, Sheikh S, Button battery in the nose — an unusual foreign body. *Clin. Rec.* **108**: 871
Palmer TJ *see* Khan *et al.*; Khan NA *et al.*
Paludetti G *see* Almadori G *et al.*; Di Girolamo S *et al.*; Galli J *et al.*
Palva T, Saksela E, Ramsay H, Myxoma of the external auditory meatus. *Clin. Rec.* **105**: 364
Pamaraju N, Khalifa SA, Darwish A, Abducens nerve, otitis media. *Clin. Rec.* **110**: 872
Pamaraju N, Khalifa SA, Darwish A, Paulose KO, Ahmed N, Yousif H, Kimura's disease. *Clin. Rec.* **110**: 1084
Pan XH *see* Huang H *et al.*
Panarese A, Clarke RW, Yardley MP, Early post-operative morbidity following tonsillectomy in children: implications for day surgery. *Orig. Art.* **113**: 1089
Panarese A, Roland NJ, Green B, Primary amyloidosis of the external auditory canal: case report. *Clin. Rec.*: **108**: 49
Panarese A, *see also* Roland NJ *et al.*
Panayiotides JG, Arapantoni-Dadioti P, Banis CG, Laryngeal squamous cell carcinoma with sebaceous differentiation. *Path. Focus* **109**: 784
Panda NK *see* Narayana HM *et al.*
Pande RM *see* Singh AM *et al.*
Panesar J *see* Umapathy N *et al.*
Pang YT, Paediatric tonsillectomy: bipolar electrodissection and dissection/snare compared. *Orig. Art.* **109**: 733
Pang YT, Raine CH, Acute suppurative parotitis and facial paralysis. *Clin. Rec.* **110**: 91
Pang YT, Willatt DJ, Do antral washouts have a place in the current management of chronic sinusitis. *Orig. Art.* **110**: 926
Pant MC *see* Mishra SC *et al.*
Pantelides E *see* Green KMJ *et al.*
Panwar SS, Martin FW, Trans-nasal endoscopic holmium: YAG laser correction of choanal atresia. *Orig. Art.* **110**: 429
Papadakis CE *see* Velegrakis GA *et al.*
Papadas TA *see* Goumas P *et al.*
Papadimitriou CP *see* Kandiloros DC *et al.*
Papadimitriou JM *see* Ashman RB *et al.*
Papailiou JG *see* Athanassopoulou AC *et al.*
Papakostas K, Thakar A, Vandapalan V, O'Sullivan G, An unusual case of stridor due to osteophytes of the cervical spine (Forestier's disease). *Clin. Rec.* **113**: 65
Paparella MM *see* Ruah CB *et al.*; de Souza C *et al.*
Papesch ME *see* Greig AVH *et al.*
Papsin BC, Bailey CM, Albert DM, Bellman SC, Surgical aspects of paediatric cochlear implantation. *Orig. Art.* **111**: 240
Papsin BC, Evans JNG, Isolated laryngeal lymphangioma: a rare cause of airway obstruction in infants. *Clin. Rec.* **110**: 969
Papsin BC, Pengilly AJ, Leighton SEJ, The developing role of a paediatric voice clinic: a review of our experience. *Orig. Art.* **110**: 1022
Parham DM, Padgham ND, Post-surgical necrotizing palisading granuloma of the nose. *Path. Focus* **107**: 656
Parikh A *see* Badia L *et al.*; Irving RM *et al.*
Parikh AA, Brookes GB, Subtotal petrosectomy with external canal overclosure in the management of chronic suppurative otitis media. *Orig. Art.* **108**: 197
Parikh AA, Brookes GB, Vestibular nerve section following previous mastoidectomy. *Orig. Art.* **110**: 836
Parikh D *see* Sanghvi V *et al.*
Parker AJ, O'Leary IK, Wight RG, Clegg RT, The Groningen valve voice prosthesis in Sheffield: a 4 year review. *Orig. Art.* **106**: 154
Parker AJ, Stevens JC, Clegg RT, An apparatus to measure pressure, flow and speech parameters in patients producing speech using the Groningen valve prosthesis. *Orig. Art.* **106**: 896
Parker AJ, Stevens JC, Wickham MH, Clegg RJ, Characteristics of Groningen tracheo-oesophageal speaking valves prior to insertion and after removal for failure. *Orig. Art.* **106**: 521
Parker AJ, *see also* Ell SR *et al.*; Farrell RWR *et al.*; Heaton JM *et al.*; Heaton and Parker; Jepson RH *et al.*; Lacy PD *et al.*; Nicol JW *et al.*; Vaughan and Parker; Watson DJ *et al.*
Parlak M *see* Selimoğlu E *et al.*
Parry RH, A case of tinnitus and vertigo treated by division of the auditory nerve. *Clin. Rec.* **105**: 1099
Parton M, Beasley NJP, Harvey G, Houghton D, Jones AS, Four cases of aggressive MRSA wound infection following head and neck surgery. *Clin. Rec.* **111**: 874
Parving A *see* Buchwald C *et al.*; Hald J *et al.*
Pasanisi E *see* Gamoletti R *et al.*; Sanna M *et al.*
Pasi KJ *see* Alusi GH *et al.*
Patange V *see* Goel S *et al.*
Patankar M *see* Hathiram BT *et al.*
Patel K, Chavda SV, Niolaris N, Pahor AL, Incidental paranasal sinus inflammatory changes in a British population. *Orig. Art.* **110**: 649
Patel KS, Foreign body in the tongue: an unusual site for a common problem. *Clin. Rec.* **105**: 849
Patel KS, *see also* Hern JD *et al.*; Hollis LJ *et al.*; Jayaraj SM *et al.*; Oyarzabal MF *et al.*; Samuel D *et al.*; Sarker and Patel; Sarker SK *et al.*
Patel N *see* Carney AS *et al.*
Patel P, Tiwari R, Karim ABMF, Nauta JJP, Snow GB, Squamous cell carcinoma of the nasal vestibule. *Orig. Art.* **106**: 332
Patel SG *see* See ACH *et al.*
Patel SK, Ghufoor K, Jayaraj SM, McPartlin DW, Philpott J, Pictorial assessment of the delivery of oropharyngeal rinse versus oropharyngeal spray. *Orig. Art.* **113**: 1092
Patel SK, McPartlin DW, Philpott JM, Abramovich S, A case of malignant otitis externa following mastoidectomy. *Clin. Rec.* **113**: 1095
Patel SK, Philpott JM, McPartlin DW, An unusual case of *Pneumocystis carinii* presenting as an aural mass. *Clin. Rec.* **113**: 555
Paterson IC *see* Stoney PJ *et al.*
Pathak KA *see* Sanghvi V *et al.*
Paton F *see* Gordon MT *et al.*
Patra DK *see* Mondal and Patra
Patrick JA *see* Hickey SA *et al.*
Paul D, Chauhan SR, Salivary megalith with a sialo-cutaneous and a sialo-oral fistula: a case report. *Clin. Rec.* **109**: 767
Paulose KO *see* Janahi WM *et al.*; Pamaraju N *et al.*; Sharma RK *et al.*
Paulsson B, Gredmark T, Burian P, Bende M, Nasal mucosal congestion during the menstrual cycle. *Orig. Art.* **111**: 337
Pauw BKH *see* Rombout and Pauw

Pawar M *see* Ogale SB *et al.*
Peake WT *see* Merchant SN *et al.*
Pearman K *see* Manohar MB *et al.*; Ruddy J *et al.*
Pearson CR, Riden DK, Garth RJN, Thomas MR, Two cases of lateral sinus thrombosis presenting with extracranial head and neck abscesses. *Clin. Rec.* **108**: 779
Pearson CR, Thomas MR, Cox HJ, Garth RJN, A cost-benefit analysis of the post-operative use of antibiotic ear drops following grommet insertion. *Orig. Art.* **110**: 527
Pearson CR, Wallace HC, The tonsil cup: a simple teaching aid for tonsillectomy. *Short Comm.* **111**: 1064
Pearson CR, *see also* Garth RJN *et al.*; Mitchell G *et al.*
Pearson L *see* Gordon MT *et al.*
Pech A *see* Triglias JM *et al.*
Pedace E *see* Mannara GM *et al.*
Pedersen CB *see* Shabana YK *et al.*
Pedersen K *see* Stangerup S-E *et al.*
Peh WCG *see* Shek TWH *et al.*
Pejrone MD *see* Rossi G *et al.*
Pekindil G *see* Uzun C *et al.*
Peled M *see* Hefer T *et al.*
Peled N *see* Cohen-Kerem R *et al.*
Pellett W *see* Moulin G *et al.*
Pellicer M, Quesada P, The use of a CT scan to predict the feasibility of decompression of the first segment of the facial nerve via the transattical approach. *Orig. Art.* **109**: 935
Pellicer M, *see also* Navarrete ML *et al.*
Pellinen P *see* Vartiainen E *et al.*
Peltola TJ, Saarento R, Water used to visualize and remove hidden foreign bodies from the external ear canal. *Short Comm.* **106**: 157
Pengilly AJ *see* Papsin BC *et al.*
Penha RS *see* Escada P *et al.*; Ruah CB *et al.*
Penman HG *see* Ziyada WF *et al.*
Penrose Stephen A *see* Farrugia EJ *et al.*
Peral E *see* Gonzalez-Compta X *et al.*
Percodani J, Braun F, Arrue P, Yardeni E, Murris-Espin M, Serrano E, Pessey JJ, Nasopharyngeal tuberculosis. *Clin. Rec.* **113**: 928
Pereira KD, Kerr AG, Disability after labyrinthectomy. *Orig. Art.* **110**: 216
Pereira KD, *see also* Mitchell RB *et al.*
Perez A *see* Lopez and Perez
Pérez J *see* Dueñas L *et al.*
Perineau D *see* Bachaud JM *et al.*
Perry A, The role of the speech and language therapist in voice restoration after laryngectomy. *Edit. Rev.* **111**: 4
Perry A, *see also* Russell JD *et al.*; Spraggs PDR *et al.*
Perry AR *see* Scott PMJ *et al.*
Perry CF *see* Reynolds JM *et al.*
Pessey JJ *see* Bachaud JM *et al.*; Percodani J *et al.*
Petein M *see* Delbrouck C *et al.*
Peters J *see* Snow DG *et al.*
Peterse JL *see* Elias MM *et al.*
Petersen BL, Buchwald C, Gerstoft J, Bretlau P, Lindeberg H, An aggressive and invasive growth of juvenile papillomas involving the total respiratory tract. *Path. Focus* **112**: 1101
Petri N, Holten I, Parathyroid cyst: Report of case in the mediastinum. *Clin. Rec.* **104**: 56
Petrocheilos J *see* Goumas P *et al.*
Petroianu G *see* Bergler W *et al.*
Petrović Z, Krejović B, Djukić V, Stanković P, Primary surgical treatment for carcinoma of the larynx. *Orig. Art.* **105**: 353
Petrović Z, Stojčić G, Ješić S, Laryngeal carcinoma in younger patients. *Orig. Art.* **110**: 934
Petti R *see* Magliulo G *et al.*
Pfleiderer AG, Thomson P, Milroy C, ENT presentation of Ollier's disease. *Path. Focus* **105**: 148
Pfleiderer AG, *see also* Chatrath P *et al.*; De and Pfleiderer; Grace and Pfleiderer; Malki D *et al.*
Pham HN *see* Wayman DM *et al.*
Phelps P *see* Lloyd G *et al.*
Phelps PD, Cochlear implants for congenital deformities. *Orig. Art.* **106**: 967
Phelps PD, Ear dysplasia after Mondini. *Hist. Art.* **108**: 461
Phelps PD, Fast spin echo MRI in otology. *Orig. Art.* **108**: 383
Phelps PD, Large vestibular aqueduct: large endolymphatic sac? *Edit. Rev.* **110**: 1103
Phelps PD, Clifton AG, Prospective cochlear implant in a case of bilateral transverse fracture of the petrous bone. *Rad. Focus* **104**: 997
Phelps PD, Mahoney CFO, Luxon LM, Large endolymphatic sac: a congenital deformity of the inner ear shown by magnetic resonance imaging. *Clin. Rec.* **111**: 754
Phelps PD, Proops D, Sellars S, Evans J, Michaels L, Congenital cerebrospinal fluid fistula through the inner ear and meningitis. *Orig. Art.* **107**: 492
Phelps PD, *see also* Briggs RJS *et al.*; Good CD *et al.*; Gray RF *et al.*; Harcourt JP *et al.*; Macgregor FB *et al.*; Stevenson DS *et al.*; Tolley and Phelps; Wake M *et al.*; Wake and Phelps
Philippe L *see* Altman KW *et al.*
Phillipps JJ *see* Farrugia EJ *et al.*
Phillips DE *see* Jones AS *et al.*; McCombe AW *et al.*; Sherman IW *et al.*
Phillips JJ *see* Adlington P *et al.*
Phillips SM *see* Safneck JR *et al.*
Philpott J *see* Motamed M *et al.*; Patel SK *et al.*
Philpott JM *see* Patel SK *et al.*
Pia F *see* Pisani P *et al.*
Pickles J *see* Benjamin and Pickles
Pickles JM *see* Mitchell and Pickles
Pierard D *see* Gordts F *et al.*
Pignataro L, Capaccio P, Pruneri G, Carboni N, Buffa R, Neri A, Ottaviani A, The predictive value of p53, MDM-2, cyclin D1 and Ki67 in the progression from low-grade dysplasia towards carcinoma of the larynx. *Orig. Art.* **112**: 455
Pignataro L, *see also* Capaccio P *et al.*
Pillay H *see* Hogg RP *et al.*
Pillay PK *see* Sethi DS *et al.*
Pillsbury HC *see* McQueen CT *et al.*
Le Pimpec-Barthes F *see* Laccourreye O *et al.*
Pin M *see* Barzan L *et al.*
Piper K *see* Kothari P *et al.*
Pirilä T *see* Kujala V *et al.*
Pirodda A, Sorrenti G, Marliani AF, Cappello I, Arterial anomalies of the middle ear associated with stapes ankylosis. *Clin. Rec.* **108**: 237
Pirsig W *see* Graamans K *et al.*; Verse and Pirsig
Pisani P, Angeli G, Krengli M, Pia F, Renal carcinoma metastasis to the parotid gland. *Clin. Rec.* **104**: 352
Pisani P, Krengli M, Ramponi A, Olina M, Pia F, Angiosarcoma of the hypopharynx. *Path. Focus* **108**: 905
Pisani P, Ramponi A, Pia F, The deep parotid lymph nodes: an anatomical and oncological study. *Orig. Art.* **110**: 148
Plate S *see* Tos M *et al.*
Platt-Hepworth S *see* Talbot A *et al.*
Plaza G, Martinez-San Millán J, Navas C, Martinez-Vidal A, Parapharyngeal emphysema: an unusual complication of temporal bone trauma. *Rad. Focus* **112**: 301
Plaza G, *see also* Raboso E *et al.*
Plent S, Shah S, Westmore GA, Thorotrast granuloma - a renascence. *Clin. Rec.* **104**: 355
Plets C *see* Buyse GG *et al.*
Plouin-Gaudon I *see* Ayache D *et al.*
Podboj J *see* Zidar N *et al.*
Podoshin L, Ben-David Y, Fradis M, Pratt H, Sharf B, Schwartz M, Brainstem auditory evoked potentials with increased stimulus rate in minor head trauma. *Orig. Art.* **104**: 191
Podoshin L, Fradis M, Ben David J, Gertner R, Feiglin H, Perilymphatic fistula — a value of diagnostic tests. *Orig. Art.* **108**: 560
Podoshin L, Fradis M, David YB, Treatment of tinnitus by intratympanic instillation of lignocaine (lidocaine) 2 per cent through ventilation tubes. *Orig. Art.* **106**: 603
Podoshin L, *see also* David YB *et al.*; Fradis M *et al.*; Gertner R *et al.*
Polat M *see* Golan-Porat N *et al.*
Poletti I *see* Fabretti F *et al.*
Poli P, Floretti G, Tessitori G, Malignant fibrous histiocytoma of the floor of the mouth: a case report. *Path. Focus* **109**: 680
Politi D *see* Barzan L *et al.*
Pollak A *see* Lesser and Pollak
Polli G *see* Gulisano M *et al.*
Pollock AM, Toner M, McMenamin M, Walker J, Timon CI, Absence of Epstein–Barr virus encoded RNA and latent membrane protein (LMP1) in salivary gland neoplasms. *Orig. Art.* **113**: 906

Poole S *see* Hollis LJ *et al.*
Pope S *see* Macnamara M *et al.*
Popović M *see* Zidar N *et al.*
Portaspana T *see* Triglias JM *et al.*
Porter G *see* Lancaster JL *et al.*
Porter GC *see* Jayaraj SM *et al.*
Porter MJ, Brookes GB, Zeman AZJ, Keir G, Use of protein electrophoresis in the diagnosis of cerebrospinal fluid rhinorrhoea. *Orig. Art.* **106**: 504
Porter MJ, Cheung HS, Ambrose R, Leung SF, van Hasselt CA, Abnormalities of the paranasal sinuses in patients with nasopharyngeal carcinoma: a computed tomographic study. *Orig. Art.* **110**: 23
Porter MJ, Leung SF, Ambrose R, Cheung HS, van Hasselt CA, The paranasal sinuses before and after radiotherapy for nasopharyngeal carcinoma: a computed tomographic study. *Orig. Art.* **110**: 19
Porter MJ, Marais J, Tolley N, Comparison of cocaine alone or with adrenaline on nasal mucosal blood flow. *Orig. Art.* **105**: 918
Porter MJ, Suen WM, John DG, van Hasselt CA, Fibromatosis of the parapharyngeal space. *Clin. Rec.* **108**: 1102
Porter MJ, Temporal arteritis presenting as a submandibular swelling. *Clin. Rec.* **104**: 819
Porter MJ, *see also* John DG *et al.*
Portmann G, The saccus endolymphaticus and an operation for draining the same for the relief of vertigo. *Clin. Rec.* **105**: 1109
Pothula V, Alderson D, Nothing new under the sun: the management of epistaxis. *Hist. Art.* **112**: 331
Pothula VB, Reddy KTV, Nixon TE, Carotico-cavernous fistula following septorhinoplasty. *Clin. Rec.* **113**: 844
Pothula VB, Savage Jones H, Verrucous squamous carcinoma of the nasal septum. *Clin. Rec.* **112**: 172
Poulacou-Rebelacou E *see* Lascaratos J *et al.*
Powell D *see* Rogers *et al.*
Powell J *see* Rockley TR *et al.*
Powell-Tuck J *see* Al-Khayat M *et al.*
Pracy JP *see* Walsh RM *et al.*
Pracy JPM, McGlashan JA, Walsh RM, Gleeson MJ, Angioedema secondary to angiotensin converting enzyme inhibitors. *Clin. Rec.* **108**: 696
Pracy JPM, Montgomery PQ, Reading N, Acute pneumonitis caused by low density barium sulphate aspiration. *Clin. Rec.* **107**: 347
Pracy JPM, Williams HOL, Montgomery PQ, Nasal teeth. *Clin. Rec.* **106**: 366
Prasad D *see* Dutt SN *et al.*; Hasan S *et al.*; Kaur A *et al.*
Prasad R *see* Little P *et al.*
Prasad S *see* Bandyopadhyay S *et al.*
Prasad U *see* Jalaludin MA *et al.*
Prasher D, Mula M, Luxon L, Cortical evoked potential criteria in the objective assessment of auditory threshold: a comparison of noise induced hearing loss with Ménière's disease. *Orig. Art.* **107**: 780
Prasher D, *see also* Davies R *et al.*
Pratt H *see* Podoshin L *et al.*
Prazma J *see* McQueen CT *et al.*
Preidler K *see* Walch C *et al.*
Prellner K *see* Harsten G *et al.*; Stjernquist-Desatnik A *et al.*
Premachandra DJ, Management of posterior epistaxis with the use of the fibreoptic nasolaryngoscope. *Orig. Art.* **105**: 17
Premachandra DJ, Use of EMLA cream as an analgesic in the management of painful otitis externa. *Short Comm.* **104**: 887
Premachandra DJ, Bull TR, Mackay IS, How safe is submucosal diathermy? *Orig. Art.* **104**: 408
Premachandra DJ, Woodward B, Milton CM, Sergeant RJ, Fabre JW, Treatment of chronic mastoiditis by grafting of mastoid cavities with autologous epithelial layers generated *in vivo* culture of buccal epithelium. *Orig. Art.* **105**: 413
Premachandra DJ, *see also* Milton CM *et al.*; Srinivasan and Premachandra; Srinivasan V *et al.*; van Houten and Premachandra
Prescott CAJ, Malan JF, Mastoid surgery at the Red Cross War Memorial Children's Hospital 1986-1988. *Orig. Art.* **105**: 409
Prescott CAJ, *see also* Wormald and Prescott
Prgomet D *see* Danić D *et al.*
Price J *see* Drake-Lee A *et al.*; Drake-Lee and Price
Price LA, Shaw HJ, Hill BT, Larynx preservation after initial non-cisplatin containing combination chemotherapy plus radiotherapy, as opposed to surgical intervention with or without radiotherapy in previously untreated advanced head and neck cancer: final analysis after 12 years follow-up. *Orig. Art.* **107**: 211
Prichard AJ *see* Hilger AW *et al.*
Prichard AJN, Colloby P, Barton RPE, Heaton JM, Tumefactive fibroinflammatory lesions of the head and neck. *Orig. Art.* **104**: 797
Prichard AJN, Marshall J, Ahmed A, Thomas RSA, Hanning CD, Uvulopalatopharyngoplasty: the Leicester experience. *Orig. Art.* **108**: 649
Prichard AJN, *see also* Lee WC *et al.*
Prikas KG, Bingham BJG, Torsion of the palatine tonsil. *Clin. Rec.* **110**: 891
Prim MP *see* De Diego JI *et al.*
Primrose WJ *see* Cullen JR *et al.*; McCluggage WG *et al.*; Menown IBA *et al.*
Prince JM *see* Robinson and Prince
Pringle MB, Grommets, swimming and otorrhoea — a review. *Orig. Art.* **107**: 190
Pringle MB, Beasley P, Brightwell AP, The use of Merocel nasal packs in the treatment of epistaxis. *Orig. Art.* **110**: 543
Pringle MB, Charig MJ, The use of digital subtraction angiography in penetrating neck injury-a very instructive case. *Rad. Focus* **108**: 522
Pringle MB, Jefferis AJ, Barrett GS, Sensorineural hearing loss caused by metastatic prostatic carcinoma: a case report. *Clin. Rec.* **107**: 933
Pringle MB, Thompson A, Reddy K, A comparison of speech audiometry and pure tone audiometry in patients with secretory otitis media. *Orig. Art.* **107**: 787
Pringle MB, *see also* Abdullah V *et al.*; Ingrams DR *et al.*; McFerran DJ *et al.*
Prinsley P, Ballooned trachea as a consequence of intubation. *Rad. Focus* **106**: 561
Prinsley P, Measurement of nasal displacement by photography. *Orig. Art.* **106**: 211
Prinsley PR, Jarmulowicz MR, Robinson AC, Massive metastasis from squamous carcinoma of the tonsil. *Path. Focus* **105**: 50
Prinsley PR, *see also* Chitre VV *et al.*; Davis JP *et al.*
Prior AJ, Montgomery PQ, Srinivasan V, Eye protection in ear, nose and throat surgery. *Short Comm.* **107**: 618
Prior AJ, Swanston AR, Myasthenia gravis presenting during general anaesthesia for an oesophagoscopy — a cautionary tale. *Clin. Rec.* **108**: 599
Prior AJ, *see also* Ganesan S *et al.*
Prior MJ, Johnson IJM, Jones K, Sharp JF, Aberrant common carotid artery encountered during free jejunal graft repair of oesophageal stricture. *Clin. Rec.* **111**: 772
Pritchard AJN *see* Watson MG *et al.*
Prokopakis EP *see* Velegrakis GA *et al.*
Proops D *see* O'Conell JE *et al.*; Phelps PD *et al.*
Proops DW, Cheshire I, A report on the 4th International Conference on cholesteatoma and mastoid surgery, Niigata, Japan, September 1992 **106**: 1107
Proops DW, *see also* Ayshford CA *et al.*; Kuo MJ *et al.*; Magnay AR *et al.*; Stevenson DS *et al.*; Wilson PS *et al.*
Proscott CAJ *see* Thorp MA *et al.*
Prowse C *see* Gibson WPR *et al.*
Pruneri G *see* Capaccio P *et al.*; Pignataro L *et al.*
Pruszczynski M *see* van Leeuwen JPPM *et al.*
Psifidis A *see* Tsakris A *et al.*
Puhakka H *see* Joensuu H *et al.*
Puhakka HJ *see* Karhuketo TS *et al.*
Pujary K *see* Balakrishnan R *et al.*; Hazarika P *et al.*
Pulotu ML *see* Gupta AC *et al.*; Murthy DP *et al.*
Puranik KR, Murthy PSN, Gopalakrishna R, Nayak DR, Unusually large mastoid antrum (mega antrum). *Clin. Rec.* **106**: 164
Puranik KR, *see also* Varghese G *et al.*
Puranik VC *see* Lobo CJ *et al.*
Purdue BN *see* Padgham ND *et al.*
Puschel W *see* Pahl S *et al.*
Pushpala SM *see* Ajulo SO *et al.*
Puterman M, Fliss DM, Ziskind E, Laufer L, A severe form of Sjogren's syndrome. *Rad. Focus* **108**: 806
Pyke R *see* Hollis LJ *et al.*

Qekker PJ, Alternative method of application of topical preparations in otitis externa. *Short Comm.* **105**: 842
Qiu L *see* Rubin JS *et al.*
Qiu WW, Yin SS, Stucker FJ, Hardjasudarma M, Audiological findings in glomus tumours. *Orig. Art.* **111**: 218
Qu J *see* Harries MLL *et al.*
Quesada P *see* Navarette ML *et al.*; Navarrete ML *et al.*; Pellicer and Quesada
Quine SM, Gray RE, Rudd M, von Blumenthal H, Microscope and hot wire cautery management of 100 consecutive patients with acute epistaxis — a superior method to traditional packing. *Orig. Art.* **108**: 845
Quine SM, Roblin DG, Cuddihy PJ, Tomkinson A, Treatment of acute auricular haematoma. *Short Comm.* **110**: 862
Quine SM, *see also* Malki D *et al.*; Tomkinson A *et al.*
Quiney R *see* Hore I *et al.*; Morgan DW *et al.*
Quiney RE, Brimble E, Hodge M, Maxillary sinusitis from dental osseointegrated implants. *Clin. Rec.* **104**: 333
Quiney RE, *see also* Alusi GH *et al.*; Delap TG *et al.*; Laing MR *et al.*
Quinn CM *see* Calvert and Quinn
Quinn SF *see* Rendleman and Quinn
Quinn SJ, Bleach NR, Ong PS, Mackay IS, Thrombosed jugular vein presenting as a hard neck mass. *Clin. Rec.* **110**: 179
Quinn SJ, Boucher BJ, Booth JB, Reversible sensorineural hearing loss in Lyme disease. *Clin. Rec.* **111**: 562
Quinodoz D, Dulguerov P, Kurt A-M, Ruefenacht D, Abele R, Allal AS, Montadon P, Multiple myeloma presenting with external ear canal mass. *Clin. Rec.* **112**: 469
Quintero J *see* Dueñas L *et al.*
Quraishi MS, O'Halpin DR, Unusually placed oesophageal foreign body. *Rad. Focus* **105**: 591
Quraishi MS, *see also* Donnelly MJ *et al.*
Qureshi SS *see* Tay HL *et al.*
Qvarnberg Y *see* Blomgren K *et al.*; Valtonen H *et al.*

Raafat F *see* O'Conell JE *et al.*
Rabinson S *see* Ostfeld EJ *et al.*
Raboso E, Llavero MT, Rosell A, Martinez-Vidal A, Craniofacial necrotizing fasciitis secondary to sinusitis. *Clin. Rec.* **112**: 371
Raboso E, Rosell A, Plaza G, Martinez-Vidal A, Haemangioma of the maxillary sinus. *Clin. Rec.* **111**: 638
Rachinel O *see* Koka VN *et al.*
Radcliffe G *see* Hore I *et al.*
Radford K *see* Rogers *et al.*; Weiner GM *et al.*
Radley-Smith RC *see* Fairley JW *et al.*
Raine CH *see* Hussain SSM *et al.*; Pang and Raine
Raine M *see* Scott A *et al.*
Raine NMN, Whittet HB, Marks NJ, Ryan RM, KTP-532 laser tonsillectomy — a potential day-case procedure? *Orig. Art.* **109**: 515
Räisänen S *see* Lilja M *et al.*; Stenfors and Räisänen
Räisänen S *see* Stenfors and Räisänen
Raith J *see* Habermann W *et al.*
Raj P, Vella EJ, Bickerton RC, Successful treatment of rhinocerebral mucormycosis by a combination of aggressive surgical debridement and the use of systemic liposomal amphotericin B and local therapy with nebulized amphotericin: a case report. *Clin. Rec.* **112**: 367
Raj P, Wilde JT, Oliff J, Drake-Lee AB, Nasal haemophilic pseudotumour. *Clin. Rec.* **113**: 924
Rajab E, Akmal SN, Nasir AM, Glycogen-rich clear cell carcinoma in the tongue. *Path. Focus* **108**: 716
Rajadurai P *see* Jalaludin MA *et al.*
Rajah B, Tinnitus related to eyelid blinking. *Clin. Rec.* **106**: 44
Rajah V, A wooden orbital foreign body. *Clin. Rec.* **107**: 735
Rajah V, Essa A, Histoplasmosis of the oral cavity, oropharynx and larynx. *Clin. Rec.* **107**: 58
Rajah V, *see also* Maharaj D *et al.*
Rajan N *see* Rajan R *et al.*
Rajan R, Rajan R, Rajan N, Santhosh Pai U, Gastric pull-up by eversion stripping of oesophagus. *Orig. Art.* **107**: 1021
Raje A *see* de Souza C *et al.*
Raje S *see* Morgan M *et al.*
Raje SG *see* Kale US *et al.*
Rajenderkumar D, Chan KKK, Hayward KA, McRae RDR, Bilateral synchronous tonsillar carcinoma. *Clin. Rec.* **113**: 255
Rajesh PB *see* Demajumdar and Rajesh
Raju KGS, Unnykrishnan P, Nayar RC, Dutt S, Macaden R, Reliability of conventional ear swabs in tubotympanic CSOM. *Orig. Art.* **104**: 460
Rakker-Thomas S *see* Thomas DM *et al.*
Rakover V, Shneyour A, Rosen G, Lensky Y, Comparison of the proteins of middle ear effusion with human mast cell proteins. *Orig. Art.* **109**: 1146
Rakover Y, Dharan M, Rosen G, Hemifacial spasm associated with external carotid artery compression of the facial nerve. *Clin. Rec.* **110**: 1081
Rakover Y, Rosen G, A comparison of partial inferior turbinectomy and cryosurgery for hypertrophic inferior turbinates. *Orig. Art.* **110**: 732
Ram B, Oluwole M, Blair RL, Mountain R, Dunkley P, White PS, Surgical simulation: an animal tissue model for training in therapeutic and diagnostic bronchoscopy. *Orig. Art.* **113**: 149
Ram B, Saleh HA, Baird AR, Mountain RE, Verrucous carcinoma of the maxillary antrum. *Path. Focus* **112**: 399
Ram B, *see also* Cain AJ *et al.*
Ram Narayan K *see* Varghese G *et al.*
Rama J *see* Rubio A *et al.*
Ramadan HH, Bu-Saba N, Baraka A, Mroueh S, Management of an unusual presentation of foreign body aspiration. *Clin. Rec.* **106**: 751
Ramalingam KK *see* Sabitha R *et al.*
Ramalingam R *see* Sabitha R *et al.*
Ramalingham KK, Smith MCF, Simple treatment for snoring also a means of prediction of uvulopalatopharyngoplasty success? *Clin. Rec.* **104**: 428
Ramalingham KK, *see also* Ramanikanth TV *et al.*; Smith MCF *et al.*
Ramamoorthy R *see* Ramanikanth TV *et al.*
Ramamurthy L, Nassar WY, Hasleton PS, Metastatic melanoma of the tonsil and the nasopharynx. *Clin. Rec.* **109**: 236
Ramamurthy L, Nassar WY, Hasleton PS, Gattamaneni HR, Orton CI, Synovial sarcoma of the pharynx. *Clin. Rec.* **109**: 1207
Ramamurthy L, Wyatt RA, Whitby D, Martin D, Davenport P, The evaluation of velopharyngeal function using flexible nasendoscopy. *Orig. Art.* **111**: 739
Ramamurthy L, *see also* Camilleri AE *et al.*; de Carpentier JP *et al.*
Raman R, Mathew J, Idikula J, Obliterative otosclerosis. *Orig. Art.* **105**: 899
Raman R, *see also* Bhargava D *et al.*; Cherian TA *et al.*; Job A *et al.*; Job and Raman; Kurien M *et al.*
Ramanathan RC, Meirion Thomas J, Infantile (desmoid-type) fibromatosis of the parotid gland **111**: 669
Ramanikanth TV, Smith MCF, Ramamoorthy R, Ramalingham KK, Postauricular cerebellar encephalocele secondary to chronic suppurative otitis media and mastoid surgery. *Clin. Rec.* **104**: 982
Ramesar KCRB *see* Cree IA *et al.*
Ramesh A *see* Sabitha R *et al.*
Ramirez FV *see* Rodriguez JLV *et al.*
Ramjettan S *see* Singh B *et al.*
Ramos J *see* Villarejo PL *et al.*
Ramos Lizana J *see* Navarro Cunchillos M *et al.*
Ramponi A *see* Pisani P *et al.*
Ramsaroop R *see* Singh B *et al.*; Singh and Ramsaroop
Ramsay AD *see* Bottrill ID *et al.*; Fenton CJV *et al.*; Fisher C *et al.*; Harries PG *et al.*; Lee and Ramsay; Thirlwall AS *et al.*
Ramsay H *see* Palva T *et al.*
Ramsay HA, Kairemo KJA, Jekunen AP, Somatostatin receptor imaging of olfactory neuroblastoma. *Clin. Rec.* **110**: 1161
Ramsay HAW, Luxford WM, Treatment of acoustic tumours in elderly patients; is surgery warranted? *Orig. Art.* **107**: 295
Ramsden R, Bance M, Giles E, Mawman D, Cochlear implantation in otosclerosis: a unique positioning and programming problem. *Clin. Rec.* **111**: 262
Ramsden R, *see also* Dodds A *et al.*; Evans DGR *et al.*
Ramsden RT, A brilliant surgical result, the first recorded: Annandale's case, 3rd May 1895. *Hist. Art.* **109**: 369
Ramsden RT, Graham Fraser lecture **111**: 907
Ramsden RT, Herdman RCD, Boyd P, Giles E, Hamilton J, A review of patients attending a preliminary cochlear implant assessment clinic. *Orig. Art.* **107**: 103

Ramsden RT, Herdman RCD, Lye RH, Ionomeric bone cement in neuro-otological surgery. *Orig. Art.* **106**: 949
Ramsden RT, Timms MS, Promontory stimulation following labyrinthectomy. *Orig. Art.* **105**: 729
Ramsden RT, *see also* Axon PR *et al.*; Birzgalis AR *et al.*; Camilleri AE *et al.*; Curley JWA *et al.*; Dutton JEM *et al.*; Evans DGR *et al.*; Herdman RCD *et al.*; Hinton AE *et al.*; Maas S *et al.*; Neary WJ *et al.*; O'Keeffe LJ *et al.*; Pace-Balzan A *et al.*; Rapado F *et al.*; Saeed and Ramsden; Saeed SR *et al.*; Temple RH *et al.*; Woolford TJ *et al.*
Ranalli P *see* Heaton JM *et al.*
Randall CJ *see* Harries and Randall; Schumacher and Randall
Rangan S *see* Jayarajan and Rangan
Ranganathan A *see* Thakar A *et al.*
Ranta M *see* Osborne JE *et al.*
Rao D *see* Hazarika P *et al.*
Rao Nanjundappa CR *see* Bhargava AK *et al.*
Rapado F, Fergie N, Ramsden RT, Hearing preservation despite labyrinthectomy for resection of giant cholesteatoma with middle fossa extension. *Clin. Rec.* **112**: 472
Rashad U, Hawthorne M, Kumar U, Welsh A, Unusual cases of congenital cholesteatoma of the ear. *Clin. Rec.* **113**: 52
Rassi DM, Pahor AL, Juvenile xanthogranuloma auris: an atypical presentation. *Clin. Rec.* **109**: 975
Ratcliffe NA *see* Kirkland PM *et al.*; Rowe-Jones JM *et al.*
Ratcliffe P *see* Akhtar S *et al.*
Rath GK *see* Bahadur S *et al.*; Tandon DA *et al.*; Thakar A *et al.*
Rautiainen M *see* Toskala E *et al.*
Ravasz LA, Hordijk GJ, Slootweg PJ, Smit F, Tweel Ivd, Uni- and multivariate analysis of eight indications for post-operative radiotherapy and their significance for loco-regional cure in advanced head and neck cancer. *Orig. Art.* **107**: 437
Raveh E, Inbar E, Shvero J, Feinmesser R, Huge saccular cyst of the larynx: a case report. *Clin. Rec.* **109**: 653
Raveh E *see also* Finkelstein Y *et al.*
Ravi KV, Brooks JR, Peritonsillar abscess - an unusual presentation of Kawasaki disease. *Clin. Rec.* **111**: 73
Ravi KV, Henderson A, Sudden deafness as the sole presenting symptom of diabetes mellitus — a case report. *Clin. Rec.* **110**: 59
Ravi KV, Wells SC, A cost-effective screening protocol for vestibular schwannoma in the late 90s. *Orig. Art.* **110**: 1129
Ravi M *see* Johnson IJM *et al.*; Jones AS *et al.*
Ravicz ME *see* Merchant SN *et al.*
Ravikumar A, Griffiths TD, Flood LM, McNeela BJ, An unusual complication following inferior turbinectomy. *Clin. Rec.* **109**: 559
Raweily EAA *see* Thomas MR *et al.*
Ray J, Gray RF, Court I, Surgical removal of 11 cochlear implants: lessons from the 11-year-old Cambridge programme. *Orig. Art.* **112**: 338
Ray J, Gray RF, Vanat ZH, Begg JA, A Scheibe cochlea deformity with macrocephaly: a case for single channel implantation. *Clin. Rec.* **112**: 1065
Ray J, Shotton JC, Lobo VJ, A rare case of salmonella neck abscess. *Clin. Rec.* **111**: 489
Ray J, Worley GA, Schofield JB, Shotton JC, Al-Ayoubi A, Rapidly invading sebaceous carcinoma of the external auditory canal. *Path. Focus* **113**: 578
Ray J, *see also* Ahmad I *et al.*; Al-Ayoubi A *et al.*; Al-Ayoubi and Ray; Gray RF *et al.*
Rayappa C *see* Watson MG *et al.*
Rayappa CS, McArthur PD, Gangopadhyay K, Antonius JI, Solitary fibrous tumour of the infratemporal fossa. *Clin. Rec.* **110**: 594
Rayappa CS, *see also* Abuzeid M *et al.*
Raynor E *see* McQueen CT *et al.*
Rea P *see* Motamed M *et al.*
Read A *see* Liu X *et al.*
Read AP, Molecular biology and the ENT surgeon in the millennium. *Mol.Biol.* **112**: 4
Read-Jones M, Murty GE, Ward V, Traumatic myositis ossificans of the superior belly of the omohyoid. *Clin. Rec.* **113**: 856
Reading N *see* Pracy JPM *et al.*
Redaelli G *see* Gherardi G *et al.*
Reddy BKM *see* Shenoy AM *et al.*
Reddy J *see* Miles LP *et al.*
Reddy K *see* Pringle MB *et al.*
Reddy KTV, Gilhooly M, Wallace M, Ali MH, Frontal sinus carcinoma presenting as acute sinusitis *Clin. Rec.* **105**: 121
Reddy KTV, Vinayak BC, Jefferis AF, Wallace M, Primary radiotherapy for treating all laryngeal cancer: a district hospital experience. *Orig. Art.* **107**: 434
Reddy KTV, *see also* Pothula VB *et al.*; Vinayak and Reddy
Reddy SC *see* Sharma HS *et al.*
Redleaf MI, Bauer CA, Topical antiseptic mouthwash in oncological surgery of the oral cavity and oropharynx. *Orig. Art.* **108**: 973
Redleaf MI, Bauman NM, Robinson RA, Gantz BJ, Medullary carcinoma of the thyroid metastatic to the temporal bone. *Clin. Rec.* **109**: 1200
Redonavich A *see* Dueñas L *et al.*
Reece PH, Higgins N, Hardy DG, Moffat DA, An aneurysm of the petrous internal carotid artery. *Clin. Rec.* **113**: 55
Reece PH, Wyatt M, O'Flynn P, Dercum's disease (adiposis dolorosa). *Clin. Rec.* **113**: 174
Rees G *see* McGlashan JA *et al.*
Rees GL *see* Leighton SEJ *et al.*
Regueiro CA, de la Torre A, Valcarcel FJ, Magallon R, Aragon G, Salvage brachytherapy and salvage surgery for recurrent oropharyngeal carcinoma following radiotherapy. *Orig. Art.* **109**: 45
Reich E *see* Kacker A *et al.*
Reid A *see* Richardson MP *et al.*
Reid AP, Robin PE, Powell J, McConkey CC, Rockley T, Staging carcinoma: its value in cancer of the larynx. *Orig. Art.* **105**: 456
Reid AP, *see also* Kuo MJ *et al.*; Wilson PS *et al.*
Reid HS *see* Martinez Devesa P *et al.*
Reijula K *see* Kujala V *et al.*
Reilly G, Skinner DW, Antibiotic steroid ear drop preparations: a cost-effective approach to their use. *Orig. Art.* **104**: 862
Reilly G, *see also* Chalstrey SE *et al.*
Reilly PG, Narula AA, Bradley PJ, Control of upper jugular haemorrhage. *Short Comm.* **104**: 976
Reilly PG, *see also* Moralee and Reilly; Tay HL *et al.*
Reinhardt MJ *see* Ross UH *et al.*
Rejab E, Said H, Saim L, Thim L, Sphenoid sinus mucocele: a possible complication of radiotherapy to the head and neck. *Clin. Rec.* **105**: 959
Rejali, D, Simo, R, Small, M, Mucocele mimicking a Warthin's tumour recurrence. *Clin. Rec.* **112**: 1092
Remedios D *see* Myatt and Remedios
Renard P *see* Laccoureye O *et al.*
Rendleman N, Quinn SF, The answer is blowing in the wind: a pedunculated tumour with saw tooth flow-volume loop. *Clin. Rec.* **112**: 973
Rennert H *see* Cohen-Kerem R *et al.*
Renou G *see* Debry C *et al.*
Rentzis GA *see* Goumas P *et al.*
Requena L *see* De la C Mera A *et al.*
Resouly A *see* Lewis and REsouly
Restivo S *see*, Franco V *et al.*
Reyes FJB *see* O'Connor Reina C *et al.*
Reynolds JM, Tomkinson A, Grigg RG, Perry CF, A Le Fort 1 osteotomy approach to lateral sphenoid sinus encephalocoeles. *Clin. Rec.* **112**: 779
Rezvani M *see* Alcock GJ *et al.*
Rhatoe HS, Suryanarayana KV, Gill HS, Recurrent massive epistaxis due to traumatic intracavernous internal carotid artery aneurysm. *Clin. Rec.* **109**: 650
Rhys Williams S *see* John DG *et al.*
Rhŷs-Evans PH, Knot to be condemned. *Short Comm.* **107**: 33
Rhŷs-Evans PH, The paranasal sinuses and other enigmas: an aquatic evolutionary theory. *Orig. Art.* **106**: 214
Rhŷs-Evans PH, Tracheo-oesophageal puncture without tears; the forceps technique. *Orig. Art.* **105**: 748
Rhŷs-Evans PH, *see also* Garth RJN *et al.*; Greig AVH *et al.*; Hartley BEJ *et al.*; Hosni A *et al.*; Hosni and Rhŷs-Evans; Mitchell G *et al.*; See ACH *et al.*
Riad M *see* Sharp JF *et al.*
Ribeiro da Silva P *see* Xavier R *et al.*
Ribera-Cortada I *see* Melgarejo-Moreno PJ *et al.*
Rice B *see* El-Naggar M *et al.*
Richards A, Brain C, Dillon MJ, Bailey CM, Craniometaphyseal and craniodiaphyseal dysplasia, head and neck manifestations and management. *Orig. Art.* **110**: 328

Richards A, *see also* Fisher EW *et al.*; Irving RM *et al.*
Richards C *see* Harris and Richards
Richardson GL *see* Strachan DR *et al.*
Richardson H, Hill J, Bennett M, Mathias DB, Massive thyroid oncocytoma. *Clin. Rec.* **105**: 143
Richardson H, *see also* Clarke RW *et al.*
Richardson HC, Beliaeff M, Clarke G, Hawthorne M, A three-array cochlear implant: a new approach for the ossified cochlea. *Orig. Art.* **113**: 811
Richardson HC, McCombe AW, Carotid sinus syndrome in parapharyngeal tumours. *Clin. Rec.* **107**: 955
Richardson MD *see* Natarajan B *et al.*
Richardson MP, Reid A, Williamson TJ, Tarlow MJ, Rudd PT, Acute otitis media and otitis media with effusion in children with bacterial meningitis. *Orig. Art.* **111**: 913
Richardson PL *see* Birzgalis AR *et al.*; Neary WJ *et al.*
Richet B *see* Klossek J-M *et al.*
Richet H *see* Klossek J-M *et al.*
Riddington-Young J *see* Courtnay Bennett and Riddington-Young
Riden DK *see* Pearson CR *et al.*
Riden K *see* Garth RJN *et al.*
Ridley NTF *see* Curtin JJ *et al.*
Rifai A *see* Taibah K *et al.*
Rifai M, Kenawi B, Visual dysfunction: Abnormal sign of benign sphenoethmoidal lesions. *Orig. Art.* **104**: 217
Rifai M, Mebed H, Bassiouni M, Direct extension of laryngeal carcinoma to the skin of the neck. *Clin. Rec.* **104**: 824
Rifai M, *see also* El Chazley M *et al.*
Riley DN, Herberger S, McBride G, Law K, Myringotomy and ventilation tube insertion at ten year follow up. *Orig. Art.* **111**: 257
Riley N, McNeill J, McCloskey B, Thomson MP, Mackie E, Acute oesophageal obstruction eighteen months after an abdominal shotgun wound. *Clin. Rec.* **111**: 177
Riley N, *see also* Tewary AK *et al.*
Rinaldo A *see* Ferlito A *et al.*; Ferlito and Rinaldo
Riordan T *see* Cox HJ *et al.*
Riquet M *see* Laccourreye O *et al.*
Risåvi R *see* Handžić-Ćuk J *et al.*
Rivron R *see* Brown PM *et al.*
Rivron RP *see* Sanderson RJ *et al.*
Rizzo S *see* Ruscito P *et al.*
Robeleco M *see* Dueñas L *et al.*
Roberson DR *see* Mason JDT *et al.*
Roberto M, Favia A, Lozupone E, A topographical analysis of the post-natal bone growth in the cochlea of the dog. *Orig. Art.* **111**: 23
Roberts AC *see* Samuel PR *et al.*
Roberts AHN *see* Graham CT *et al.*
Roberts D *see* Benson-Mitchell R *et al.*; Commins DJ *et al.*
Roberts DN, Corbett MJ, Breen D, Jonathan DA, Smith CET, Rhabdomyoma of the larynx: a rare cause of stridor. *Path. Focus* **108**: 713
Roberts DN, Hampal S, Lloyd GAS, The diagnosis of inflammatory sinonasal disease. *Orig. Art.* **109**: 27
Roberts DN *see also* Macgregor FB *et al.*
Robertshaw D *see* Hawthorne MR *et al.*
Robertson A, Nicolaides AR, Taylor RH, Spontaneous carotico-cavernous fistula presenting as pulsatile tinnitus. *Clin. Rec.* **113**: 744
Robertson AG *see* Simpson D *et al.*
Robertson AJ *see* Baird AR *et al.*
Robertson AS *see* Watson MG *et al.*
Robertson IJA *see* Hughes RGM *et al.*
Robertson MS *see* White PS *et al.*
Robier A *see* Martin L *et al.*
Robin PE *see* Nigam A *et al.*; O'Connell and Robin; Rockley TR *et al.*
Robinson AC, Kaberos A, Cox PM, Stearns MP, Oncocytoma of the larynx. *Clin. Rec.* **104**: 346
Robinson AC, Management of radiation-induced otitis externa. *Orig. Art.* **104**: 458
Robinson AC, *see also* Badia L *et al.*; Cumberworth and Robinson; Morrissey G *et al.*; Prinsley PR *et al.*
Robinson AK *see* Blanshard *et al.*
Robinson D *see* Williamson IG *et al.*
Robinson DW *see* Coles RRA *et al.*
Robinson J *see* Sharp JF *et al.*
Robinson JM *see* Sharp and Robinson; Snow DG *et al.*; Terzis and Robinson; Wake M *et al.*
Robinson P *see* Juman S *et al.*; von Schoenberg M *et al.*; Zeitoun and Robinson
Robinson PJ, Davis JP, Fraser JG, The hyoid syndrome: a pain in the neck. *Orig. Art.* **108**: 855
Robinson PJ, Grant HR, Brown SG, NdYAG Laser treatment of a glomus tympanicum tumour. *Clin. Rec.* **107**: 236
Robinson PJ, Prince JM, Dansac mini cap. A new method of waterproof ear protection. *Orig. Art.* **104**: 763
Robinson PJ, *see also* Davis JP *et al.*
Robinson PM, Prospective study of the complications of endoscopic laryngeal surgery. *Orig. Art.* **105**: 356
Robinson RA *see* Devaiah AK *et al.*; Redleaf MI *et al.*; Victoria LV *et al.*
Roblin DG *see* Hari CK *et al.*; Quine SM *et al.*; Tomkinson A *et al.*
Robson AK, Barker CS, Whittet HB, Epistaxis as an unusual presentation of an antrochoanal polyp. *Clin. Rec.* **104**: 643
Robson AK, Blanshard JD, Jones K, Albery EH, Smith IM, Maw AR, A conservative approach to the management of otitis media with effusion in cleft palate children. *Orig. Art.* **106**: 788
Robson AK, Eveson JW, Smith IM, Maw AR, Papillary adenocarcinoma of the middle ear. *Path. Focus* **104**: 915
Robson AK, *see also* Makura and Robson
Robson NLK, Oswal VH, Flood LM, Radiation therapy of laryngeal cancer: A twenty year experience. *Orig. Art.* **104**: 699
Roche J *see* Ajal M *et al.*
Rock WP *see* Kent SE *et al.*
Rockall TA, Watkinson JC, Clark SEM, Douek EE, Scintigraphic evaluation of glomus tumours. *Clin. Rec.* **104**: 33
Rockley T *see* Reid AP *et al.*
Rockley TJ *see* Watts SJ *et al.*
Rockley TR, Robin PE, Powell J, McConkey CC, Primary treatment of cancer of the larynx. *Orig. Art.* **105**: 459
Rodd C *see* Douglas-Jones AG *et al.*
Rodgers MJC *see* Sharp JF *et al.*
Rodrigo JP, Fernandez JA, Alvarez JC, Gómez J, Suárez C, Castleman's disease restricted to the infratemporal fossa. *Clin. Rec.* **110**: 896
Rodrigues G *see* Sanghvi V *et al.*
Rodriguez C *see* Campos A *et al.*
Rodriguez H *see* Dueñas L *et al.*
Rodriguez-Peralto JL *see* Carrillo R *et al.*
Rog D *see* Jones and Rog
Rogers JH *see* McCombe AW *et al.*
Rogers MJC *see* Sharp JF *et al.*
Rogers SN, Batch A, Powell D, Radford K, "The holiday plug": a temporary solution to the problem of the leaking voice prosthesis. *Short Comm.* **107**: 1149
Roh H-J, Goh E-K, Chon K-M, Wang S-G, Topical inhalant steroid (budesonide, Pulmicort nasal) therapy in intubation granuloma. *Orig. Art.* **113**: 427
Roland J *see* Koka VN *et al.*
Roland NJ, Caslin AW, Smith PA, Turnbull LS, Panarese A, Jones AS, Fine needle aspiration cytology of salivary gland lesions reported immediately in a head and neck clinic. *Orig. Art.* **107**: 1025
Roland NJ, Khine MM, Clarke R, van Velzen D, A rare congenital intranasal polyp: mesenchymal chondrosarcoma of the nasal region. *Clin. Rec.* **106**: 1081
Roland NJ, Smith CA, Miller IW, Jones AS, Lesser TH, A simple technique to measure body sway in normal subjects and patients with dizziness. *Orig. Art.* **109**: 189
Roland NJ, *see also* Flanagan PM *et al.*; Jackson SR *et al.*; Jones AS *et al.*; Panarese A *et al.*
Rolando M *see* Rossi G *et al.*
Rombout J, Pauw BKH, Radical revision mastoidectomy for chronic otitis media without cholosteatoma: the relevance of exenteration of all rest cells. *Orig. Art.* **113**: 710
Romeling F *see* Rungby JA *et al.*
Romito A *see* Cadoni G *et al.*
Ronzoni R *see* Magliulo G *et al.*
La Rosa FC *see* Mannara GM *et al.*
Rose DSC *see* Spraggs PDR *et al.*
Rose EL *see* Morrison D *et al.*
Rosell A *see* Raboso E *et al.*

Roselli R *see* Ferrario F *et al.*
Rosen G *see* Rakover and Rosen; Rakover Y *et al.*
Rosenfeld RM, Nonsurgical management of surgical otitis media with effusion. *Orig. Art.* **109**: 811
Rosignoli M *see* Galli J *et al.*
Rosin RD *see* Montgomery P *et al.*
Rosowski JJ *see* Merchant SN *et al.*
Ross J, Murrant NJ, Dysphagia as a major symptom of tetanus. *Clin. Rec.* **106**: 923
Ross UH, Reinhardt MJ, Berlis A, Localization of active otosclerotic foci by tympano-cochlear scintigraphy (TCS) using correlative imaging. *Orig. Art.* **109**: 1051
Rossi G, Actis R, Solero P, Rolando M, Pejrone MD, Cochlear interdependence and micromechanics in man and their relations with the activity of the medial olivocochlear efferent system (MOES). *Orig. Art.* **107**: 883
Rossi M *see* Garozzo and Rossi
Rossiter A, Occupational otitis externa in chicken catchers. *Clin. Rec.* **111**: 366
Roth Y *see* Kronenberg J *et al.*; Talmi YP *et al.*
Rothera MP *see* Axon PR *et al.*; Morris DP *et al.*
Rothman L *see* Kacker A *et al.*
Rowe JG, Hosni AA, A common carotid artery aneurysm causing severe dysphagia. *Clin. Rec.* **108**: 67
Rowe JR *see* Bath J *et al.*
Rowe-Jones J, Paranasal aspergillosis — a spectrum of disease. *Edit.* **107**: 773
Rowe-Jones J, Mackay I, Colquhoun I, Charing Cross CT protocol for endoscopic sinus surgery. *Orig. Art.* **109**: 1057
Rowe-Jones J, *see also* Connolly AAP *et al.*; Hartley and Rowe-Jones; McEwan JA *et al.*; Sharp HR *et al.*
Rowe-Jones JM, Adam EJ, Moore-Gillon V, Subtle diagnostic markers of orbital floor blow-out fracture on coronal CT scan. *Rad. Focus* **107**: 161
Rowe-Jones JM, Leighton SEJ, The value of head dressings for middle ear surgery. *Orig. Art.* **107**: 17
Rowe-Jones JM, Macallan DC, Sorooshian M, Polyarteritis nodosa presenting as bilateral sudden onset cochleo-vestibular failure in a young woman. *Clin. Rec.* **104**: 562
Rowe-Jones JM, Solomons NB, Ratcliffe NA, Leiomyosarcoma of the larynx. *Path. Focus* **108**: 359
Rowe-Jones JM, Vowles R, Leighton SEJ, Freedman AR, Diffuse tuberculous parotitis. *Clin. Rec.* **106**: 1094
Rowlands DC *see* Dhaliwal J *et al.*; Lall GS *et al.*
Rowley H, The molecular genetics of head and neck cancer. *Mol. Biol.* **112**: 607
Rowley H, Walsh M, McShane D, Fraser I, O'Dwyer TP, Chondroradionecrosis of the larynx: still a diagnostic dilemma. *Orig. Art.* **109**: 218
Rowsell AR *see* Greig AVH *et al.*
Royo EM *see* De la C Mera A *et al.*
Royo J *see* Adiego MI *et al.*
Rozenblit A *see* Rubin JS *et al.*
Ruacan S *see* Sözeri B *et al.*
Ruah CB, Barros E, Ruah SB, Penha RS, Schachern P, Paparella MM, Paediatric otoscopy-clinical and histological correlation. *Orig. Art.* **106**: 307
Ruah CB, Cohen D, Sadé J, Eustachian tube teratoma and its terminological correctness. *Path. Focus* **113**: 271
Ruah CB, *see also* Escada P *et al.*
Ruah SB *see* Ruah CB *et al.*
Rubin JS, Advancement cheiloplasty for reconstruction of floor of mouth defects. *Orig. Art.* **108**: 486
Rubin JS, Qiu L, Etkind P, Amplification of the INT-2 gene in head and neck squamous cell carcinoma. *Onc. Focus* **109**: 72
Rubin JS, Silver CE, Surgical approach to submucosal lesions of the supraglottic larynx: the supero-lateral thyrotomy. *Orig. Art.* **106**: 416
Rubin JS, Wadler S, Beitler JJ, Haynes H, Rozenblit A, McGill F, Goldberg G, Runowicz C, Audiological findings in a Phase 1 protocol investigating the effect of WR 2721, high-dose cisplatin and radiation therapy in patients with locally advanced cervical carcinoma. *Short Comm.* **109**: 744
Rubin JS, *see also* Akhtar S *et al.*; Kreel B *et al.*; Tavin ME *et al.*
Rubio A, Fernández MR, Figols J, Rama J, Experimental study on neurorrhaphy of the recurrent laryngeal nerve in dogs. *Orig. Art.* **110**: 748
Rubio Suárez A *see* Del Valle Zapico A *et al.*
Rucheng C *see* Zhi W *et al.*
Ruchvarger E *see* Ophir D *et al.*
Ruckphaopunt K *see* Kangsanarak J *et al.*
Rudd M *see* Quine SM *et al.*
Rudd MJ, Harries MLI, Lynch CA, Moffat DA, Hearing loss fluctuating with blood sugar levels in Ménière's disease. *Clin. Rec.* **107**: 620
Rudd PT *see* Richardson MP *et al.*
Ruddy J, Stokes M, Pearman K, Pharyngoplasty surgery and obstructive sleep apnoea. *Orig. Art.* **105**: 195
Ruddy J, *see also* Anwar R *et al.*; Jay S *et al.*; Nigam A *et al.*
Rudert H *see* Brademann G *et al.*
Rudnicki C *see* Finkelstein Y *et al.*
Ruefenacht D *see* Quinodoz D *et al.*
Ruffy M *see* Har-El G *et al.*
Ruiz C *see* Navarrete ML *et al.*
Ruiz HG *see* Rodriguez JLV *et al.*
Ruiz P *see* Dueñas L *et al.*
Ruiz-Avila I *see* Esteban F *et al.*
Rungby JA, Romeling F, Borum P, Tonsillectomy: assessment of quality by consultation rate after discharge *Orig. Art.* **113**: 135
Runowicz C *see* Rubin JS *et al.*
Rupa V, Dilemmas in auditory assessment of developmentally retarded children using behavioural observation audiometry and brain stem evoked response audiometry. *Orig. Art.* **109**: 605
Rupa V, Krishnaswami H, Job A, Autograft ossicle selection in cholesteatomatous ear disease: histopathological considerations. *Orig. Art.* **111**: 807
Rupa V *see also* Cherian TA *et al.*
Ruscito P, Bicciolo G, Rizzo S, Frenguelli A, Per-oral excision of a pharyngeal branchial cyst after MRI study. *Clin. Rec.* **107**: 1054
Rushton HC, Tong MCF, Yue V, Wormald PJ, van Hasselt CA, Prevalence of otitis media with effusion in multicultural schools in Hong Kong. *Orig. Art.* **111**: 804
Ruske DR, Glassford N, Costello S, Stewart IA, Laryngeal rhabdomyosarcoma in adults. *Clin. Rec.* **112**: 670
Ruso A *see* Aslan A *et al.*
Russell D *see* Neilly IJ *et al.*
Russell GA *see* Shotton JC *et al.*; Shotton JS *et al.*
Russell J *see* Cumberworth VL *et al.*
Russell JD, Bleach NR, Glaser M, Cheesman AD, Brachytherapy for recurrent nasopharyngeal and naso-ethmoidal tumours. *Orig. Art.* **107**: 115
Russell JD, Donnelly M, McShane DP, Alun-Jones T, Walsh M, What causes acute otitis externa? *Orig. Art.* **107**: 898
Russell JD, Glover GW, Friedmann I, Necrotizing sialometaphasia. *Path. Focus* **106**: 569
Russell JD, Perry A, Cheesman AD, Cordectomy: a solution to Teflon granuloma of the vocal fold. *Short Comm.* **109**: 53
Russo A *see* Bhatia S *et al.*; Saleh E *et al.*; Sanna M *et al.*; *see* Chashaba A *et al.*
Russo GL *see* Comin CC *et al.*
Rutka JA *see* Heaton JM *et al.*; Pace-Balzan and Rutka
Rutty GN *see* McAllister RMR *et al.*
Ryan CD *see* Lacy PD *et al.*
Ryan L *see* Donnelly MJ *et al.*
Ryan R *see* Brown PM *et al.*; Collins and Ryan; von Schoenberg M *et al.*.
Ryan RM, Ligmaject system for local anaesthesia in otology. *Orig. Art.* **104**: 606
Ryan RM *see also* Koay CB *et al.*; Raine NMN *et al.*
Ryder WDJ *see* de Carpentier JP *et al.*
Ryley NG *see* Skia B *et al.*

Saarento R *see* Peltola and Saarento
Saatci MR *see* Akiner MN *et al.*
Sabin SL, Lee D, Har-El C, Low velocity gunshot injuries to the temporal bone. *Orig. Art.* **112**: 929
Sabitha R, Ramalingam R, Ramalingam KK, Sivakumaran TA, Ramesh A, Genetics of otosclerosis. *Orig. Art.* **111**: 109
Saccogna PW *see* Strauss M *et al.*
Sacilotto C *see* Mannara GM *et al.*
Sadé J, The nasopharynx, eustachian tube and otitis media. *Rev. Art.* **108**: 95
Sadé J, Fuchs C, Cholesteatoma: ossicular destruction in adults and children. *Orig. Art.* **108**: 541

Sadé J, *see also* Berger G *et al.*; Luntz M *et al.*; Luntz and Sadé; Ruah CB *et al.*
Sadigh M *see* Israel and Sadigh
Sadiq H *see* Vernham GA *et al.*
Sadiq HA *see* Thomas MR *et al.*
Sadiq SA *see* Hehar SS *et al.*
Sadler A *see* Macnamara M *et al.*
Sadlier M, Stephens SDG, An approach to the audit of tinnitus management. *Orig. Art.* **109**: 826
Saeed NR *see* Saeed SR *et al.*
Saeed SR, JLO Travelling Fellowship 1996 Report **112**: 110
Saeed SR, Brookes GB, The use of *Clostridium botulinum* toxin in palatal myoclonus: a preliminary report. *Orig. Art.* **107**: 208
Saeed SR, Hinton AE, Ramsden RT, Lye RH, Spontaneous dissection of the intrapetrous internal carotid artery. *Clin. Rec.* **104**: 491
Saeed SR, Ramsden RT, Rehabilitation of the paralysed face: results of facial nerve surgery. *Orig. Art.* **110**: 922
Saeed SR, Ramsden RT, Hartley C, Woolford TJ, Boyd P, Cochlear reimplantation. *Clin. Rec.* **109**: 980
Saeed SR, Saeed NR, Brookes GB, Temporomandibular joint capsule prolapse: a technique of repair using autograft cartilage. *Orig. Art.* **108**: 30
Saeed SR *see also* Hartley C *et al.*
Saeed SWr *see* de Carpentier JP *et al.*
Safneck JR, Alguacil-Garcia A, Dort JC, Phillips SM, Solitary fibrous tumour: report of two new locations in the upper respiratory tract:. *Path. Focus* **107**: 252
Saha A *see* Keerl R *et al.*
Sahota JS *see* Hazarika P *et al.*
Said H *see* Gendeh BS *et al.*; Rejab E *et al.*
Saim L *see* Rejab E *et al.*
Saito Y *see* Takimoto T *et al.*
Sajeeda S *see* Gupta AK *et al.*
Saka T *see* Yamamoto Y *et al.*
Sakaguchi M, Moriya K, Taguchi K, Katsuno S, Bilateral carcinomas of the maxillary sinus. *Clin. Rec.* **107**: 42
Sakaguchi M, Sato S, Asawa S, Taguchi K, Computed tomographic findings in peritonsillar abscess and cellulitis. *Rad. Focus.* **109**: 449
Sakaguchi M, Taguchi K, Ishiyama T, Acute pharyngitis, an unusual complication of intravenous hyperalimentation. *Clin. Rec.* **108**: 159
Sakai S-I *see* Miyaguchi M *et al.*
Sakai S *see* Miyaguchi M *et al.*
Sakai T *see* Hoshino T *et al.*
Sakakibara A *see* Fuse T *et al.*
Sakakura A, Yamamoto Y, Takasaki T, Makimoto K, Nakamura M, Takahashi H, Recurrent laryngeal papillomatosis developing into laryngeal carcinoma with human papilloma virus (HPV) type 18: a case report. *Clin. Rec.* **110**: 75
Sakalinskas V, Jankauskas R, Clinical otosclerosis and auditory exostoses in ancient Europeans (investigation of Lithuanian paleoosteological samples). *Hist. Art.* **107**: 489
Sakashita H *see* Takimoto T *et al.*
Saksela E *see* Palva T *et al.*
Sakura M *see* Kato S *et al.*
Sakurai M *see* Kato S *et al.*
Salam AU *see* Aijaz F *et al.*
Salam MA, Cable HR, The use of antibiotic/steroid ear drops to reduce post-operative otorrhoea and blockage of ventilation tubes. A prospective study. *Orig. Art.* **107**: 188
Salam MA, El-Kahky M, El-Mehiry H, The use of pyriform sinus mucosa for reconstruction after vertical partial laryngectomy. *Orig. Art.* **106**: 900
Salam MA, Wengraf C, Concho-antropexy or total inferior turbinectomy for hypertrophy of the inferior turbinates? A prospective randomized study. *Orig. Art.* **107**: 1125
Salam MA, Wengraf C, Glue under pressure: a bad prognostic sign for recurrence of otitis media with effusion. *Orig. Art.* **106**: 974
Salam MA, Whitehead E, Large maxillary antral mucocele presenting with facial asymmetry. *Clin. Rec.* **107**: 451
Salam MA, *see also* Whitehead and Salam
Salama D *see* Lupovitch A *et al.*
Salama NY *see* Jones NS *et al.*
Salazar-Fernandez CI *see* Galera-Ruiz H *et al.*
Saleem M, McArthur PD, Hainau B, Velagapudi SB, Fibrous histiocytoma of the larynx. *Path. Focus* **112**: 1205
Saleem M, *see also* Babu Manohar M *et al.*; Mahasin ZZ *et al.*; Taibah K *et al.*
Saleem Y *see* Dutt SN *et al.*
Saleh A *see* Abd-Al-Hady MR *et al.*
Saleh E, Naguib M, Russo A, Taibeh AK, Sanna M, Vascular malformation of the internal auditory canal. *Clin. Rec.* **107**: 1039
Saleh E, *see also* Naguib MB *et al.*
Saleh EA *see* Sanna M *et al.*
Saleh EM, Complications of treatment of recurrent laryngeal papillomatosis with the carbon dioxide laser in children. *Orig. Art.* **106**: 715
Saleh EM, Abdullwahab AA, Kammal MM, Age and sex incidence of hypopharyngeal tumours in upper Egypt: Assuit University experience. *Orig. Art.* **109**: 737
Saleh HA, Bridger MWM, Invasive aspergillosis of paranasal sinuses. *Clin. Rec.* **111**: 1168
Saleh HA, Murty GE, O'Donoghue GM, Isolated agenesis of the mastoid antrum. *Clin. Rec.* **108**: 497
Saleh HA, O'Flynn P, Prostatic metastases in the nose and paranasal sinuses. *Clin. Rec.* **107**: 629
Saleh HA, *see also* Harmse JL *et al.*; Ram B *et al.*
Saleh SZ *see* Abu Shara KA *et al.*
Salem MA, Ectopic thyroid mass adherent to the oesophagus. *Clin. Rec.* **106**: 746
Salib RJ, Valentine P, Akhtar S, Surgical emphysema following dental treatment. *Clin. Rec.* **113**: 756
Saliola S *see* Barbara M *et al.*
Sallam FS *see* Abd-Al-Hady MR *et al.*
Salomon G *see* Walsted A *et al.*
Salto-Tellez M *see* Molony NC *et al.*
Salvan D, Julieron M, Marandas P, Janot F, Leridant AM, Domenge C, Mamelle G, Schwaab G, Luboinski B, Combined transfacial and neurosurgical approach to malignant tumours of the ethmoid sinus. *Orig. Art.* **112**: 446
Salvinelli F *see* Maurizi M *et al.*
Samarrai SM *see* Kamal and Samarrai
Sament S *see* Pahor and Sament
Samet A, Talmon V, Frankel R, Simon K: A new diagnostic approach to congenital stridor using a laryngeal mask airway and rigid endoscope. *Short Comm.* **108**: 1076
Samuel D, Thomas DM, Tierney P, Patel KS, Atlanto-axial subluxation (Grisel's syndrome) following otolaryngological diseases and procedures. *Clin. Rec.* **109**: 1005
Samuel PR, Roberts AC, Nigam A, The use of Indermil n-butyl cyanoacrylate in otorhinolaryngology and head and neck surgery: a preliminary report on the first 33 patients. *Orig. Art.* **111**: 536
Samuel PR, *see also* Ho TP *et al.*; Nigam and Samuel; Watson MG *et al.*
Samuelson P *see* Stjernquist-Desatnik A *et al.*
San-Juan J *see* Watts SJ *et al.*
Sanchez JM *see* Eréno C *et al.*
Sanchez TG *see* Bento RF *et al.*
Sandeman DR *see* Carney AS *et al.*
Sanders R *see* McAllister RMR *et al.*
Sanderson D *see* Heaton JM *et al.*
Sanderson RJ, Rivron RP, Wallace WA, Adenosquamous carcinoma of the hypopharynx. *Clin. Rec.* **105**: 678
Sanderson RJ, *see also* MacDougall and Sanderson
Sandhu G *see* Draper MR *et al.*; Gonzalez-Garcia J *et al.*
Sandhu GS *see* Zeitoun H *et al.*
Sando HT, Sando I, Masutani H, Temporal bone histopathological findings in campomelic dysplasia. *Clin. Rec.* **106**: 361
Sando I *see* HT Sando *et al.*
Sanghvi V, Lala M, Borges A, Rodrigues G, Pathak KA, Parikh D, Lateral thyrotomy for neurilemmoma of the larynx. *Orig. Art.* **113**: 346
Sanguino-Fabre JC *see* Galera-Ruiz H *et al.*
Sani A, Carbon dioxide laser stomaplasty for tracheostomal stenosis. *Short Comm.* **112**: 467
Sani A, *see also* Lokman S *et al.*
Sanna M, Karmarkar S, Landolfi M, Hearing preservation in acoustic neuroma surgery: fact or fantasy? *Rev. Art.* **109**: 374

Sanna M, Mazzoni A, Saleh EA, Lateral approaches to the median skull base through the petrous bone: the system of the modified transcochlear approach. *Orig. Art.* **108**: 1036
Sanna M, Shea CM, Gamoletti R, Russo A, Surgery of the 'only hearing ear' with chronic ear disease. *Orig. Art.* **106**: 793
Sanna M, Zini C, Gamoletti R, Pasanisi E, Primary intratemporal tumours of the facial nerve: diagnosis and treatment. *Orig. Art.* **104**: 765
Sanna M, *see also* Aslan A *et al.*; Bhatia S *et al.*; Gamoletti R *et al.*; Naguib MB *et al.*; Naguib and Sanna; Saleh E *et al.*; *see* Chashaba A *et al.*
Santana-Hernandez DJ, Ell SR, Da Costa P, Macklin CP, Hussain SSM, Giant hamartoma of the oropharynx. *Clin. Rec.* **110**: 480
Santhosh Pai U *see* Rajan R *et al.*
De Santis A *see* Cadoni G *et al.*
Santoro R *see* Franchi A *et al.*
Santos V *see* Singh B *et al.*
Saqulain G *see* Iqbal K *et al.*
Saran AK *see* Gupta AK *et al.*
Sarandeses-García A, Sulsenti G, López-Amado M, Martínez-Vidal J, Septal perforations closure utilizing the backwards extraction-reposition technique of the quadrangular cartilage. *Orig. Art.* **113**: 721
Sardana P *see* Mathur NN *et al.*
Sarierler M *see* Başak S *et al.*
Sarker SK, Ghufoor K, Patel KS, Tolley NS, Coleman DV, Nuclear DNA content using computerized image cytometry of squamous cell carcinomas of the head and neck. *Orig. Art.* **111**: 43
Sarker SK, Patel KS, Mean nuclear area and chromosomal DNA content of squamous cell carcinomas of the oral cavity using computerized image analysis. *Orig. Art.* **111**: 141
Sarker SK, Tierney P, Patel KS, Fisher C, Coleman DV, DNA indices of primary and recurrent squamous cell carcinomas of the tongue and tonsil using image cytometry. *Orig. Art.* **110**: 237
Sasaki Y *see* Gyo K *et al.*; Gyo and Sasaki
Sata T *see* Nakanishi R *et al.*
Satar B *see* Özünlü A *et al.*
Sathanathan N *see* O'Reilly BJ *et al.*
Sato N *see* Hara A *et al.*
Sato S *see* Sakaguchi M *et al.*
Saunders CAB *see* Tierney PA *et al.*
Saunders JE *see* Moffat DA *et al.*
Saunders MW, Jones NS, Periorbital abscess due to ethmoiditis in neonate. *Clin. Rec.* **107**: 1043
Saunders MW, Jones NS, Balsitis M, Bilateral auricular pseudocyst: a case report and discussion. *Clin. Rec.* **107**: 39
Saussez S, Heimann P, Vandevelde L, Bisschop P, Jortay A, Schandene L, Cogan E, Undifferentiated carcinoma of the nasopharynx and leukemoid reaction: report of a case with literature review. *Clin. Rec.* **111**: 66
Savaci S *see* Öncel S *et al.*
Savage Jones H *see* Pothula and Savage Jones
Savage MO *see* Tungland OP *et al.*
Savy L *see* Xenellis J *et al.*
Sawaki S *see* Mochimatsu I *et al.*
Scadding GK, Lund VJ, Darby YC, The effect of long-term antibiotic therapy upon ciliary beat frequency in chronic rhinosinusitis. *Orig. Art.* **109**: 24
Scadding GK, *see also* Golding-Wood DG *et al.*; Lloyd GAS *et al.*; Lund and Scadding; Lund VJ *et al.*
Scally CM, Black JHA, Cystic hygroma: massive recurrence in adult life. *Clin. Rec.* **104**: 908
Scarano E *see* Almadori G *et al.*
Schachern P *see* Ruah CB *et al.*; de Souza C *et al.*
Schalén L *see* Harsten G *et al.*; Stjernquist-Desatnik A *et al.*
Schandene L *see* Saussez S *et al.*
Scheel O *see* Nordahl SHG *et al.*
De Schepper A *see* de Varebeke SJ *et al.*
Schick B *see* Weber R *et al.*
Schiller A, Wormald PJ, Malleomyringoplasty using a silicone prosthesis. *Orig. Art.* **106**: 205
Schipper J *see* Maier W *et al.*
Schipper JH, Holecek BU, Sievers KW, A tumour derived from Ebner's glands: microcystic adnexal carcinoma of the tongue. *Clin. Rec.* **109**: 1211
Schmidt U, Metz KA, Schrader M, Leder L-D, Well-differentiated (oncocytoid) neuroendocrine carcinoma of the larynx with multiple skin metastases: a brief report. *Path. Focus* **108**: 272
von Schoenberg M, Robinson P, Ryan R, Nasal packing after routine nasal surgery — is it justified? *Orig. Art.* **107**: 902
Schofield JB *see* Al-Ayoubi A *et al.*; Asare-Owusu L *et al.*; Davis JP *et al.*; de Grip *et al.*; Ray J *et al.*
Schrader M *see* Metz KA *et al.*
Schumacher DU, Randall CJ, A survey to determine the extent of previous symptoms and surgery on patients presenting with nasal polyps. *Orig. Art.* **110**: 736
Schumacher DU, *see also* Adam EC *et al.*
Schumacher M *see* Marangos and Schumacher
Schumacher U *see* Adam EC *et al.*
Schutte HK *see* Van de Ven and Schutte
Schwaab G *see* Koka V *et al.*; Koka VN *et al.*; Salvan D *et al.*
Schwartz M *see* Podoshin L *et al.*
Schwer S *see* Stangerup S-E *et al.*
Sciot R *see* Hermans R *et al.*
Scott A, Raine M, Stansbie JM, Ethmoid metastasis of endometrial carcinoma causing mucocele of maxillary antrum. *Clin. Rec.* **112**: 283
Scott A, Stansbie JM, Actinomycosis presenting as a nasopharyngeal tumour: a case report. *Clin. Rec.* **111**: 163
Scott GA *see* Hickey SA *et al.*
Scott PMJ, Bleach NR, Perry AR, Cheesman AD, Complications of pharyngeal myotomy for alaryngeal voice rehabilitation. *Orig. Art.* **107**: 430
Scott PMJ, Dhillon RS, McDonald PJ, Cervical necrotizing fasciitis and tonsillitis. *Clin. Rec.* **108**: 435
Scott PMJ, Loftus WK, Kew J, Ahuja A, Yue V, van Hasselt CA, Diagnosis of peritonsillar infections: a prospective study of ultrasound, computerized tomography and clinical diagnosis. *Orig. Art.* **113**: 229
Scott PMJ, Morphopoulos G, Bleach N, Augmentation rhinoplasty in nasal sarcoidosis. *Clin. Rec.* **106**: 544
Scott RF, Collins MM, Wilson JA, Parapharyngeal lipoma. *Clin. Rec.* **113**: 935
Sealy GR *see* Jones TA *et al.*
Searle AE *see* Hartley BEJ *et al.*
Sebastian P *see* Cherian T *et al.*
Seco M *see* Llorente JL *et al.*
Sedallian A *see* Klossek JM *et al.*
See ACH, Patel SG, Montgomery PQ, Rhŷs-Evans PH, Fisher C, Intralaryngotracheal thyroid: ectopic thyroid or invasive carcinoma? *Clin. Rec.* **112**: 673
Seemungal TAR *see* Kalan A *et al.*
Segal K *see* Shpitzer T *et al.*
Segal S *see* Berenholz LP *et al.*; Englender M *et al.*
Segas J *see* Manolopoulos L *et al.*; Velegrakis G *et al.*
Seibaek M *see* Holm E *et al.*
Seidal T *see* Theander C *et al.*
Seidman M *see* Kitamura K *et al.*
Seijas R *see* Dueñas L *et al.*
Şekercioğlu N, Cansiz H, Günç M, Reconstruction with composite nasal septal cartilage and auricular cartilage in extended partial laryngectomy. *Orig. Art.* **110**: 739
Sekhar P, El-Jassar P, Ell SR, Recurrent unilateral tonsillitis secondary to a penetrating foreign body in the tonsil. *Clin. Rec.* **112**: 584
Seki H *see* Otsuka H *et al.*
Sekitani T *see* Yamashita H *et al.*
Selesnick SH *see* Yagoda and Selesnick
Selimoğlu E, Sütbeyaz Y, Çiftçioğlu MA, Parlak M, Esrefoğlu M, Öztürk A, Primary tonsillar tuberculosis: a case report. *Clin. Rec.* **109**: 880
Selimoğlu E *see also* Sütbeyaz Y *et al.*
Sellars I, Keen EN, Laryngeal growth in infancy. *Orig. Art.* **104**: 622
Sellars S *see* Phelps PD *et al.*
Sellars SL *see* Jones TA *et al.*; Thorp MA *et al.*; Wormald PJ *et al.*; Wormald and Sellars
Sen Gupta SK *see* Murthy DP *et al.*
Senders CW *see* Gadre AK *et al.*
Sendzischew H *see* Mesko TW *et al.*
Şener B, Hasçelik G, Önerci M, Tunçkanat F, Evaluation of the microbiology of chronic sinusitis. *Orig. Art.* **110**: 547

Senfors LE, Henriksen AO, Treatment of earache among the Lappish people/ *Orig. Art.* **104**: 109
Sengupta A, Dubey SP, Chaudhuri D, Sinha AK, Chakravarti P, Ortner's syndrome revisited. *Clin. Rec.* **112**: 377
Sennaroğlu G *see* Sennaroğlu L *et al.*
Sennaroğlu L, Dini FM, Sennaroğlu G, Gursel B, Ozkan S, Transtympanic dexamathasone application in Ménière's disease: an alternative treatment for intractable vertigo. *Orig. Art.* **113**: 217
Sennaroğlu L, Önerci M, Turan E, Sungur A, Infratemporal hydatid cyst — unusual location of echinococcosis. *Clin. Rec.* **108**: 601
Sennaroğlu L, Sozeri B, Sungur A, Otological findings in idiopathic hyperphosphatasia. *Clin. Rec.* **113**: 158
Sennerby L *see* Heo SJ *et al.*
Senthikumaran G, Crankson S, Yousef M, Spontaneous closure of acquired tracheo-oesophageal fistula. *Clin. Rec.* **110**: 685
Seo SY *see* Hong KH *et al.*
Sergeant RJ *see* Milton CM *et al.*; Premachandra DJ *et al.*; Shotton JC *et al.*; Worley GA *et al.*
Serin M *see* Kurtulmaz SY *et al.*
Serraino D *see* Barzan L *et al.*
Serrano E *see* Bachaud JM *et al.*; Percodani J *et al.*
Seshadri MS *see* Kurien M *et al.*
Seshadri R, Antrochonal polyp: a case report of treatment with intranasal steroids. *Clin. Rec.* **109**: 553
Sethi DS, Lau DPC, Chan C, Sphenoid sinus mucocele presenting with isolated oculomotor nerve palsy. *Clin. Rec.* **111**: 471
Sethi DS, Lau DPC, Chee LWJ, Chong V, Isolated sphenoethmoid recess polyps. *Clin. Rec.* **112**: 660
Sethi DS, Pillay PK, Stanley RE, Endoscopic management of lesions of the sella turcica. *Orig. Art.* **109**: 956
Sethi DS, Stanley RE, Deep neck abscesses — changing trends. *Orig. Art.* **108**: 138
Sethi DS, Stanley RE, Parapharyngeal abscess. *Orig. Art.* **105**: 1025
Sethi DS, Stanley RE, Pillay PK, Endoscopic anatomy of the sphenoid sinus and sella turcica. *Orig. Art.* **109**: 951
Sethi DS, *see also* Chew KK *et al.*; Goh and Sethi
Shabana YK, Allam H, Pederson CB, Laser stapedotomy. *Orig. Art.* **113**: 413
Shadaba A, Gaze MN, Grant HR, The response of adenoid cystic carcinoma to tamoxifen. *Clin. Rec.* **111**: 1186
Shadaba A, Graham JM, Posterior rhinoscopy revisited. *Short Comm.* **110**: 1055
Shadaba A, Zaidi S, Aneurysmal bone cyst of the hyoid. *Clin. Rec.* **106**: 71
Shadbolt C *see* Heaton JM *et al.*
Shafshak TS, Essa AY, Bakey FA, The possible contributing factors for the success of steroid therapy in Bell's palsy: a clinical and electrophysiological study. *Orig. Art.* **108**: 940
Shah BK *see* Hadfield PJ *et al.*
Shah K *see* Ahmed K *et al.*
Shah NS *see* Abdullah V *et al.*; Hern JD *et al.*
Shah P *see* Balakrishnan R *et al.*; Hazarika P *et al.*
Shah RB *see* Lakhia TS *et al.*
Shah S *see* Plent S *et al.*
Shah SC *see* Yaddanapudi and Shah
Shahani R *see* Baser B *et al.*
Shaheen OH *see* Walsh RM *et al.*
Shakespeare PG *see* Harries PG *et al.*
Shall L *see* Thompson AC *et al.*
Sham CL, Woo JKS, van Hasselt CA, Endoscopic resection of inverted papilloma of the nose and paranasal sinuses. *Orig. Art.* **112**: 758
Sham JST *see* Lau SK *et al.*
Shamboul KM, An unusual prevalence of complications of chronic suppurative otitis media in young adults. *Orig. Art.* **106**: 874
Shamim A *see* Thomas R *et al.*
Sharf B *see* Podoshin L *et al.*
Shariff S *see* Hasan S *et al.*
Sharma HS, Abdullah JM, Othman NH, Muhamad M, Teratocarcinosarcoma of the nasal cavity and ethmoid. *Path. Focus* **112**: 682
Sharma HS, Meorkamal MZ, Zainol H, Dharap AS, Eccrine cylindroma of the ear canal. *Path. Focus* **108**: 706
Sharma HS, Reddy SC, Mohamad A, Meor Kamal MZ, Halder D, Metastatic osteosarcoma of the ethmoid: an unusual cause of recurrent epistaxis and proptosis. *Clin. Rec.* **110**: 676
Sharma N *see* Md Iqbal S *et al.*
Sharma OP *see* Goel S *et al.*
Sharma PD *see* Izzat and Sharma
Sharma RK, Al-Khalifa A, Paulose KO, Ahmed N, Parotid duct stone — removal by a dormia basket. *Clin. Rec.* **108**: 699
Sharma RK, Paulose KO, Al-Khalifa S, Shenoy P, Pre-operative nasal preparation-nasal packing and spraying compared. *Short Comm.* **106**: 39
Sharma VK *see* Srinivasan S *et al.*
Sharma VL *see* Simo and Sharma
Sharnuby M *see* El-Simily and Sharnuby
Sharp HR, Blaney SPA, Morrison GAJ, Neonatal stridor in association with herpes simplex infection of the larynx. *Clin. Rec.* **112**: 1192
Sharp HR, Rowe-Jones JM, Biring GS, Mackay IS, Endoscopic ligation or diathermy of the sphenopalatine artery in persistent epistaxis. *Orig. Art.* **111**: 1047
Sharp HR, Spraggs PDR, Mackay IS, Combined approach intranasal endoscopic and external Lothrop procedure in chronic frontal sinus disease. *Short Comm.* **111**: 637
Sharp J *see* Hehar SS *et al.*
Sharp JF, Robinson JM, Treatment of tympanic membrane retraction pockets by excision. A prospective study. *Orig. Art.* **106**: 882
Sharp JF, Rodgers MJC, MacGregor FB, Meehan CJ, McLaren K, Angiolymphoid hyperplasia with eosinophilia. *Clin. Rec.* **104**: 977
Sharp JF, Rogers MJC, Riad M, Kerr ALG, Combined study to assess the role of calcium alginate swabs and ligation of the inferior tonsillar pole in the control of intra-operative blood loss during tonsillectomy. *Orig. Art.* **105**: 191
Sharp JF, Terzis TF, Robinson J, Myringoplasty for the anterior perforation: experience with the Kerr flap. *Orig. Art.* **106**: 14
Sharp JF, *see also* Babu Manohar M *et al.*; Carney AS *et al.*; Johnson IJM *et al.*; Lee and Sharp; Prior MJ *et al.*; Sonsale A *et al.*
Sharr MM *see* Mehta and Sharr *et al.*
Shaw HJ *see* Price LA *et al.*
Shaw J *see* Birzgalis AR *et al.*
Shaw JD *see* Fairley JW *et al.*
Shea CM *see* Sanna M *et al.*
Sheehan AL *see* Wake M *et al.*
Shehab NM *see* Yehia MM *et al.*
Shehab Z, Desousa S, Pahor AL, Metastasis in tongue from carcinoma of bronchus: a case report. *Clin. Rec.* **108**: 1099
Shehab Z, Pahor A, A valuable device in the management of epistaxis. *Short Comm.* **111**: 361
Shehab ZP *see* Kesse WK *et al.*
Shehata O *see* Abd-Al-Hady MR *et al.*
Sheikh S *see* Natarajan B *et al.*; Palmer O *et al.*
Sheikha A, Kameswaran M, Okafor BC, Al Saigh A-A, Otological manifestations of thalassaemia intermedia. *Orig. Art.* **106**: 316
Shek TWH, Peh WCG, Leung G, Chondromyxoid fibroma of skull base: a tumour prone to local recurrence. *Path. Focus* **113**: 380
Shenoy AM, Nanjundappa A, Kumar P, Kumar RV, Reddy BKM, Kannan V, Anantha N, Interjugular neck dissection and post-operative irradiation for neck control in advanced glottic cancers — are we justified? *Orig. Art.* **108**: 26
Shenoy AM, Nanjundappa M, Nayak UK, Bhargava AK, Naganoor IA, Vijayakumar M, Scalp flap — a utility and reconstructive option for head and neck surgeons. *Orig. Art.* **107**: 324
Shenoy AM, *see also* Bhargava AK *et al.*; Hasan S *et al.*
Shenoy P, David VC, A case of quinsey in a fifteen-month-old child. *Clin. Rec.* **107**: 354
Shenoy P, *see also* Murthy P *et al.*; Sharma RK *et al.*
Shenoy PK, David VC, Cervical thymic cyst — a case report. *Clin. Rec.* **107**: 950
Shenoy PK, *see also* Khan NA *et al.*; Murthy P *et al.*
Sherman IW, Phillips DE, Bowdler DA, Jones AS, Interpretation of maxillary sinus radiographs in children. *Orig. Art.* **105**: 541
Sherman IW, Swift AC, Haqqani MT, Primary mucosal malignant melanoma of the middle ear. *Clin. Rec.* **105**: 1061
Sherman IW, *see also* Lancaster JL *et al.*

Sherman Y *see* Nageris B *et al.*
Shetty SC *see* Kaur A *et al.*
Shiao G-M *see* Lu S-L *et al.*
Shibutani K *see* Okabe Y *et al.*
Shidara K, Uruma T, Yasuoka Y, Kamei T, Two cases of nasopharyngeal branchial cyst. *Clin. Rec.* **107**: 453
Shiga H *see* Ishimaru T *et al.*
Shigematsu A *see* Nakanishi R *et al.*
Shih C-T *see* Wu M-R *et al.*
Shimamoto K *see* Tsutsumi T *et al.*
Shimazaki T, Yoshida V, Hirano M, Arrangement and number of intralaryngeal ganglia and ganglionic neurons: comparative study of five species of mammals. *Orig. Art.* **109**: 622
Shimazu A *see* Nakanishi R *et al.*
Shimizu H, Kodama A, Severe acute pancreatitis as a first symptom of primary hyperparathyroid adenoma. *Clin. Rec.* **110**: 602
Shimizu Y *see* Kawashima O *et al.*
Shimoji Y *see* Tsunoda K *et al.*
Shinde KJ *see* Gupta A *et al.*
Shindell B *see* Cohen O *et al.*
Shinefield HR *see* Akhtar and Shinefield
Shinkin CA, Holmes AH, Freeland AP, Orf of the pinna. *Clin. Rec.* **105**: 947
Shinkwin C *see* Koyuncu M *et al.*; Murty GE *et al.*
Shinkwin CA, Gibbin KP, Neonatal upper airway obstruction caused by chlamydial rhinitis. *Clin. Rec.* **109**: 58
Shinkwin CA, Murty GE, Gibbin KP, Bradley PJ, Inhalation of a Montgomery safe T-tube plug. *Clin. Rec.* **106**: 1004
Shinkwin CA, Murty GE, Simo R, Jones NS, Per-operative antibiotic/steroid prophylaxis of tympanostomy tube otorrhoea: chemical or mechanical effect? *Orig. Art.* **110**: 531
Shinohara A *see* Hara A *et al.*
Shiraishi K *see* Harada H *et al.*
Shirali GN *see* Bhargava KB *et al.*
Shirazi A, Fenton JE, Fagan PA, Large vestibular aqueduct syndrome and stapes fixation. *Clin. Rec.* **108**: 989
Shirazi A, *see also* Fenton JE *et al.*
Shiwa M, Kojima H, Moriyama H, Expression of transforming growth factor-alpha (TGF-alpha) in cholesteatoma. *Orig. Art.* **112**: 750
Shizuka T *see* Kawashima O *et al.*
Shneyour A *see* Rakover Y *et al.*
Shone G, Kemink JL, Telian SA, Prognostic significance of hearing loss as a lateralising indicator in the surgical management of vertigo. *Orig. Art.* **105**: 618
Shone GR, Griffith IP, Titanium grommets: a trial to assess function and extrusion rates. *Orig. Art.* **104**: 197
Shone GR, Yardley MPJ, An audit into the incidence of handicap after unilateral radical neck dissection. *Orig. Art.* **105**: 760
Shone GR, *see also* Backhouse SS *et al.*
Shortridge, RTJ *see* Ahmad I *et al.*
Shorvon P *see* Balraj A *et al.*
Shotton JC, Milton CM, Allen JP, Multiple ganglioneuroma of the neck. *Clin. Rec.* **106**: 277
Shotton JC, Sergeant RJ, Tanner NSB, Allen JP, Lateral temporal bone resection for extensive pinnal malignancy: Has anything changed in forty years? *Orig. Art.* **107**: 697
Shotton JC, *see also* Al-Ayoubi A *et al.*; Asare-Owusu L *et al.*; Burns and Shotton; de Grip *et al.*; Milton CM *et al.*; Ray J *et al.*; Sinha and Shotton
Shotton JS, Russell GA, Milton CM, Sergeant RJ, Extra-pharyngeal neck pathology complicating pharyngeal pouch surgery. *Clin. Rec.* **107**: 1163
Shpitzer T, Stern Y, Segal K, Levy R, Carcinoma of the lip: observations on its frequency in females. *Orig. Art.* **105**: 640
Shubinski RE *see* Bachaud JM *et al.*
Shukla GK *see* Mishra SC *et al.*
Shum BS *see* Chow LT *et al.*
Shupak A *see* Gordon CR *et al.*
Shvero J, Hadar T, Feinmesser R, Fistula in the inner canthus associated with ethmoiditis. *Clin. Rec.* **106**: 1076
Shvero J, *see also* Hader T *et al.*; Raveh E *et al.*
Siar CH, Ng KH, Aggressive (malignant?) epithelial odontogenic ghost cell tumour of the maxilla. *Path. Focus* **108**: 269
Siar CH, Ng KH, Calcifying and keratinising ameloblastoma of the maxilla. *Path. Focus* **105**: 971
Siar CH, Ng KH, Ngui CH, Chuah CH, Atypical peripheral ameloblastoma of the palate. *Clin. Rec.* **104**: 252
Siar CH, *see also* Ng and Siar
Sichel J-Y *see* Nageris B *et al.*
Siddiq MA, Erythema multiforme after application of aural Gentisone HC drops. *Clin. Rec.* **113**: 1002
Siddique M *see* Maroof M *et al.*
Siddiqui N, Yung MW, Day-case adenoidectomy: how popular and safe in a rural environment. *Orig. Art.* **111**: 444
Siddiqui SA *see* Hazarika P *et al.*
Sidek DS *see* Indudharan R *et al.*; Lokman S *et al.*
Sierra A *see* Campos A *et al.*
Sievers KW *see* Schipper JH *et al.*
Siim C *see* Katholm M *et al.*
Sillars HA, Fagan PA, The management of multiple paraganglioma of the head and neck. *Orig. Art.* **107**: 538
Silva JM *see* Escada P *et al.*
Silver CE *see* Rubin and Silver
Silverman CL *see* Klumpp TR *et al.*
Silverstein H *see* Kitamura K *et al.*
Silvola J *see* Nieminen P *et al.*
Sim DW, Maran AGD, Harris D, Metastatic salivary pleomorphic adenoma. *Clin. Rec.* **104**: 45
Sim DW, *see also* Ah-See KW *et al.*; Warrick PD *et al.*; White A *et al.*
Sim RJ, Beasley N, Milford CA, Trigemenal neurinoma presenting with trismus. *Clin. Rec.* **113**: 1112
Sim RST, Tan HKK, A case of metastatic hepatocellular carcinoma of the sphenoid sinus. *Clin. Rec.* **108**: 503
Sim RST, *see also* Gibb AG *et al.*
Simaskos N, Palaiologos Y, Eliopoulos PN, Trichinosis and cancer of the larynx. *Clin. Rec.* **106**: 171
Simmen DPB *see* Lesser THJ *et al.*
Simms MH *see* Cocks HC *et al.*
Simo R, Hartley C, Malik T, Wilson GE, Taylor PH, Mandal BK, Primary non-Hodgkin's lymphoma of the larynx in an AIDS patient. *Clin. Rec.* **112**: 77
Simo R, Jones NS, Head bandaging following otoplasty — how we do it. *Short Comm.* **108**: 410
Simo R, Sharma VL, Treatment of rhinophyma with carbon dioxide laser. *Orig. Art.* **110**: 841
Simo R, *see also* Rejali D *et al.*; Shinkwin CA *et al.*
Simon K *see* Samet A *et al.*
Simon P *see* Smith MCF *et al.*
Simpson D, Robertson AG, Lamont D, A comparison of radiotherapy and surgery as primary treatment in the management of T_3 N_0 M_0 glottic tumours. *Orig. Art.* **107**: 912
Simpson PR *see* Chen KTK *et al.*
Simpson RHW *see* Ingelaere PPC *et al.*
Singh AM, Bahadur S, Tandon DA, Pande RM, Anterior mandibulotomy for oral and oropharyngeal tumours. *Orig. Art.* **107**: 316
Singh B, A safer transnasal technique for the management of bilateral choanal atresia. *Orig. Art.* **105**: 1004
Singh B, Bilateral choanal atresia: key to success with the transnasal approach. *Orig. Art.* **104**: 482
Singh B, Combined internal maxillary and anterior ethmoidal artery occlusion: the treatment of choice in intractable epistaxis. *Orig. Art.* **106**: 507
Singh B, Metastatic choriocarcinoma of the maxilla: an unusual cause of severe intractable epistaxis. *Clin. Rec.* **106**: 917
Singh B, Role of surgery in tuberculosis mastoiditis. *Orig. Art.* **105**: 907
Singh B, The management of lateral sinus thrombosis. *Orig. Art.* **107**: 803
Singh B, The management of sinogenic orbital complications. *Orig. Art.* **109**: 300
Singh B, Jugpershad Maharaj T, Tuberculosis of the parotid gland: clinically indistinguishable from a neoplasm. *Clin. Rec.* **106**: 929
Singh B, Maharaj TJ, Radical mastoidectomy: its place in otitic intracranial complications. *Orig. Art.* **107**: 1113
Singh B, Ramjettan S, Maharaj TPJ, Ramsaroop R, Schwannoma of the posterior pharyngeal wall. *Clin. Rec.* **109**: 883
Singh B, Ramsaroop R, Clinical features of malignant transformation in benign laryngeal papillomata. *Orig. Art.* **108**: 642
Singh B, Santos V, Guffin TN, Alexis R, Har-El G, Giant cell variant of malignant fibrous histiocytoma of the head and neck. *Clin. Rec.* **105**: 1079

Singh B, Van Dellen J, Ramjettan S, Maharaj TJ, Sinogenic intracranial complications. *Orig. Art.* **109**: 945
Singh IP *see* de Carpentier JP *et al.*
Singh KB, Hanna GS, Dinnen JS: Paraganglioma of the external auditory canal. *Clin. Rec.* **107**: 228
Singh KB, *see also* Gupta AK *et al.*
Singh M, Ahluwalia H, An unusual presentation of squamous cell carcinoma of the pyriform fossa as a pedunculated polypoidal mass-a case report. *Clin. Rec.* **109**: 157
Singh M, *see also* Kacker A *et al.*
Singh MP *see* Ohri AK *et al.*
Singh V, Annis JAD, Todd GB, Osteoma of the internal auditory canal presenting with sudden unilateral hearing loss. *Clin. Rec.* **106**: 905
Singh V, Brockbank MJ, Flower N, Frost RA, Tracheosophageal puncture using a flexible gastroscope and a percutaneous endoscopic gastrostomy set. *Orig. Art.* **111**: 447
Singh V, Brockbank MJ, Frost RA, Tyler S, Multidisciplinary management of dysphagia: the first 100 cases. *Orig. Art.* **109**: 419
Singh V, Brockbank MJ, Todd GB, Flexible transnasal endoscopy: is local anaesthetic necessary? *Orig. Art.* **111**: 616
Singh V, *see also* Norman L *et al.*
Singh VP *see* Mathur NN *et al.*
Singhal SK *see* Gupta AK *et al.*
Singhania PK *see* Bandyopadhyay S *et al.*
Singharo S *see* Mayall FG *et al.*
Sinha A, Shotton JC, An unusual migrating foreign body from pharynx to mediastinum. *Clin. Rec.* **110**: 279
Sinha A, *see also* Kumar BN *et al.*
Sinha AK *see* Sengupta A *et al.*
Siniluoto TMJ, Luotonen JP, Tikkakoski TA, Leinonen ASS, Jokinen KE, Value of pre-operative embolization in surgery for nasopharyngeal angiofibroma. *Orig. Art.* **107**: 514
Sinniah R *see* Leong HK *et al.*; Soh KBK *et al.*
Siodlak M *see* Nandapalan V *et al.*
Siodlak MA, Stell PM, Wilson JA, Green JA, Allison RS, Adler D, Squadrelli-Saraceno M, Alternating cisplatinum and VAC ineffective in end stage squamous cell carcinoma of the head and neck. *Orig. Art.* **104**: 631
Sirimanna KS, Madden GJ, Miles S, Anaesthesia of the tympanic membrane: Comparison of EMLA cream and iontophoresis. *Orig. Art.* **104**: 195
Sirimanna T *see* Bamiou DE *et al.*
Şirin S *see* Karaşen RM *et al.*; Murat Karasen R *et al.*
Sissons MCJ *see* Stringfellow HF *et al.*
Sithisarn P *see* Kunachak S *et al.*
Sivakumaran S *see* Elango and Sivakumaran
Sivakumaran TA *see* Sabitha R *et al.*
Sivaramakrishnan P *see* Cherian T *et al.*
Skevas A *see* Kastanioudakis I *et al.*
Skia B, Bibas A, Hickey SA, Ryley NG, Merkel cell carcinoma of the pinna. *Path. Focus* **111**: 1195
Skinner DW *see* Lee WC *et al.*; Reilly and Skinner
Skitarelić N, Mladina R, Matulić Z, Kovačić M, Necrotizing fasciitis after peritonsillar abscess in an immunocompetent patient. *Clin. Rec.* **113**: 759
Skoulakis C *see* Velegrakis G *et al.*
Skovgaard LT *see* Homøe P *et al.*
Skurnik Y *see* Talmi YP *et al.*
Slater A, Smallman LA, Drake-Lee AB, Increase in epithelial mast cell numbers in the nasal mucosa of patients with perennial allergic rhinitis. *Orig. Art.* **110**: 929
Sleiman J *see* Ayache D *et al.*
Slevin NJ, Collins CD, Hastings DL, Waller ML, Johnson RJ, Cowan RA, Birzgalis AR, Farrington WT, Swindell R, The diagnostic value of positron emission tomography (PET) with radiolabelled fluorodeoxyglucose (F-18-FDG) in head and neck cancer. *Orig. Art.* **113**: 548
Slevin NJ, Irwin CJR, Banerjee SS, Gupta NK, Farrington WT, Olfactory neural tumours — the role of external beam radiotherapy. *Orig. Art.* **110**: 1012
Slevin NJ, *see also* Logue JP *et al.*
Sloan J *see* Adams DA *et al.*
Slootweg PJ *see* Ravasz LA *et al.*
Small J *see* Hampton SM *et al.*
Small M, Hariri MA, Radio-necrosis of the temporal bone presenting as cerebellopontine angle lesion. *Clin. Rec.* **104**: 423
Small M, *see also* Ahmmed AU *et al.*; Birzgalis AR *et al.*; Rejali D *et al.*
Smallman LA *see* Agius AM *et al.*; Drake-Lee AB *et al.*; Hilger AW *et al.*; Johnson IJM *et al.*; Slater A *et al.*; Snow DG *et al.*
Smeets IMG, Engelberts I, The use of leeches in a case of post-operative life-threatening macroglossia. *Clin. Rec.* **109**: 442
Smelt GJC *see* Gibbin KP *et al.*; Kaddour and Smelt; Martin-Hirsch and Smelt
Smethurst A *see* Ahmed K *et al.*
Šmid L, Cowden's disease — its importance for otolaryngologists. *Clin. Rec.* **107**: 1064
Šmid L, Lavrenčak B, Žargi M, Laryngo-tracheo-bronchopathia chondro-osteoplastica. *Clin. Rec.* **106**: 845
Smit F *see* Ravasz LA *et al.*
Smith AP *see* Morrison D *et al.*
Smith CA *see* Nandapalan V *et al.*; Roland NJ *et al.*
Smith CET *see* Ohri AK *et al.*; Roberts DN *et al.*
Smith DJ *see* Murrison AW *et al.*
Smith I, Smith M, Mathias D, Wallis J, Cryoglobulinaemia and septal perforation: a rare but logical cause. *Clin. Rec.* **110**: 668
Smith I, Wilde A, Secondary tonsillectomy haemorrhage and non-steroidal anti-inflammatory drugs. *Orig. Art.* **113**: 28
Smith I, *see also* Blanshard JD *et al*
Smith IM *see see* Robson AK *et al.*; Maw AR *et al.*; Robson AK *et al.*
Smith JE *see* Kuo MJ *et al.*
Smith M *see* Smith I *et al.*
Smith MCF, Simon P, Ramalingham KK, Delayed facial palsy following uncomplicated stapedectomy. *Orig. Art.* **104**: 611
Smith MCF, *see also* Ramalingham and Smith; Ramanikanth TV *et al.*
Smith NM, Stafford FW, Post-cricoid lymphangioma. *Clin. Rec.* **105**: 220
Smith PAS *see* Roland NJ *et al.*
Smith R *see* Stafford N *et al.*
Smith TL *see* McQueen CT *et al.*
Smyth DA, Fenton J, Timon C, McShane DP, Occult pharyngeal perforation secondary to 'pencil injury'. *Rad. Focus* **110**: 901
Smyth DA, *see also* Callanan V *et al.*; Lacy PD *et al.*
Smyth GDL *see* Adams DA *et al.*; Brooker and Smyth; Toner JG *et al.*; Toner and Smyth; Wielinga and Smyth
Sng I *see* Chew KK *et al.*; Low WK *et al.*
Snik AFM *see* Makhdoum MJA *et al.*
Snow CRS, Intranasal button battery causing septal perforation: a case report. *Clin. Rec.* **108**: 589
Snow DG, Campbell JB, Morgan DW, The microbiology of peritonsillar sepsis. *Orig. Art.* **105**: 553
Snow DG, Campbell JB, Smallman LA, Fanconi's anaemia and post-cricoid carcinoma. *Clin. Rec.* **105**: 125
Snow DG, Hansel TT, Williams PE, Drake-Lee AB, Thompson RA, Sinus computerized tomography in primary hypogammaglobulinaemia. *Orig. Art.* **107**: 1008
Snow DG, Robinson JM, Peters J, Bone pate repair of the eroded incus — five years on. *Orig. Art.* **109**: 1048
Snow DG, *see also* Al-Fallouji HK *et al.*; Ali and Snow; Donaldson and Snow; Wilson PS *et al.*
Snow GB *see* Balm AJM *et al.*; Önder T *et al.*; Patel P *et al.*; Tiwari R *et al.*
Snow MH *see* Hajioff D *et al.*
Soames JV *see* Aldren CP *et al.*; Deans JAJ *et al.*; Goldsmith P *et al.*; Johnson IJM *et al.*; Livesey and Soames; Murty GE *et al.*; Watson MG *et al.*
Şoba E *see* Zidar N *et al.*
Sobki SH *see* Zakzouk SM *et al.*
Sobolos K *see* Nikolaou A *et al.*
Soda T *see* Harada H *et al.*
Soda Y *see* Tsunoda and Soda
Soda-Merhy A *see* Alfaro-Monge JM *et al.*
Soh KBK, Tan HKK, Sinniah R, Mucoepidermoid carcinoma of the middle ear: a case report. *Clin. Rec.* **110**: 249
Solanellas J, Esteban F, Soldado L, López-Lacomba D, Hierro C, Jimenez JM, Hodgkin's disease of middle ear and mastoid. *Clin. Rec.* **110**: 869
Soldado L *see* Solanellas J *et al.*
Solero P *see* Rossi G *et al.*
Sollmann WP *see* Laszig R *et al.*
Solomons NB, Livesey JR, Acute upper airway obstruction following Teflon injection of a vocal cord: the value of nebulised adrenaline and a helium/oxygen mixture in its management. *Clin. Rec.* **104**: 654

Solomons NB, Stearns MP, Haemangiosarcoma of the maxillary antrum. *Path. Focus* **104**: 831
Solomons NB, *see also* Irvine and Solomons; Kirkland PM *et al.*; Rowe-Jones JM *et al.*
Sombolos K *see* Daniilidis J *et al.*; Nikolaou A *et al.*
Somers T, Govaerts P, Janssens de Varebeke S, Offeciers E, Revision stapes surgery. *Orig. Art.* **111**: 233
Somjee S, A narcotic foreign body in the throat. *Clin. Rec.* **105**: 774
Somjee S, The SomjeeCrabtree temporal bone support clamp. *Short Comm.* **111**: 54
Somogyi I *see* Szilvassy J *et al.*
Somri M *see* Gaitini L *et al.*; Gaitini LA *et al.*
Sone M, Nakashima T, Yanagita N, Laryngotracheal separation under local anesthesia for intractable salivery aspiration: cricoidectomy with fibrin glue support. *Clin. Rec.* **110**: 72
Sone S *see* Wang Q *et al.*
Soni NK, Antroscopy in rhinoscleroma. *Orig. Art.* **106**: 697
Soni NK, Leprosy of the larynx. *Orig. Art.* **106**: 518
Soni NK, Microscopic rhinoscopy in lepromatous leprosy. *Orig. Art.* **111**: 122
Soni NK, Scleroma of the larynx. *Orig. Art.* **111**: 438
Soni NK, Scleroma of the lower respiratory tract: a bronchoscopic study. *Orig. Art.* **108**: 484
Soni NK, Snoring and oral submucous fibrosis. *Orig. Art.* **111**: 346
Soni NK, Hemani DD, Scleroma of the eustachian tube: salpingoscleroma. *Orig. Art.* **108**: 944
Sonsale A, Sharp JF, Johnson IJM, Gustatory sweating of the external auditory canal. *Clin. Rec.* **113**: 1000
Soo G, Nunez DA, A simple method for retaining the aural speculum. *Short Comm.* **109**: 230
Soo G *see also* Marshall JN *et al.*
Sood S, Henein RR, Girgis B, Pharyngeal pouch following anterior cervical fusion. *Clin. Rec.* **112**: 1085
Sood S, Nair SB, Fenwick JD, Horgan K, Metastatic melanoma of the tonsil. *Path. Focus* **113**: 1036
Sørensen JA, Godballe C, Andersen NH, Jørgensen K, Peritonsillar abscess. *Orig. Art.* **105**: 442
Sørensen VZ, Bonding P, Can ear irrigation cause rupture of the normal tympanic membrane?: an experimental study in man. *Orig. Art.* **109**: 1036
Sorensen WT, Moller-Andersen K, Behrendt N, Rheumatoid nodules of the larynx. *Clin. Rec.* **112**: 573
Sorooshian M *see* Rowe-Jones JM *et al.*
Sorrenti G *see* Casolino D *et al.*; Cavicchi *et al.*; Pirodda A *et al.*
Sorribes MM, Welinder NR, Stangerup S-E, Anti-neutrophil cytoplasmic antibody-associated mucocutaneous allergic vasculitis with oral manifestations caused by propylthiouracil. *Clin. Rec.* **113**: 477
Soufi HE, Kameswaran M, Malatine T, Khat and oral cancer. *Orig. Art.* **105**: 643
Soussi AC, Benghiat A, Holgate CS, Mojumdar B, Neuroendocrine tumours of the head and neck. *Clin. Rec.* **104**: 504
Soussi AC, O'Flynn P, McFarlane HW, Unusual cause of intranasal injury. *Clin. Rec.* **105**: 215
de Souza C, Karnad D, de Souza R, Raje A, Mansukhani K, Tilve GH, The stapedial reflex in cephalic tetanus. *Orig. Art.* **108**: 736
de Souza C, Paparella MM, Schachern P, Yoon TH, Pathology of labyrinthine ossification. *Orig. Art.* **105**: 621
de Souza CE, Karnad DR, Tilve GH, Clinical and bacteriological profile of the ear in otogenic tetanus: a case control study. *Orig. Art.* **106**: 1051
de Souza R *see* de Souza C *et al.*
Sözeri B, Önerci M, Hosal S, Ruacan S, Primary gingival leiomyosarcoma. *Clin. Rec.* **106**: 46
Sözeri B, *see also* Sennaroğlu L *et al.*
Spandow O, Hellström S, Dahlström M, Bohlin L, Comparison of the repair of permanent tympanic membrane perforations by hydrocolloidal dressing and paper patch. *Orig. Art.* **109**: 1041
Sparkes C, Lacey NK, A study of mercuric oxide and zinc-air battery life in hearing aids. *Orig. Art.* **111**: 814
Sparkes C, *see also* Osborne J *et al.*
Speculand B *see* O'Connell JE *et al.*
Spedding AV *see* Norman L *et al.*
Speight PM *see* Grant WE *et al.*; James PL *et al.*
Spencer GT *see* Hickey SA *et al.*
Spencer H *see* McCombe AW *et al.*
Spencer JA *see* Midwinter KI *et al.*
Spencer M *see* El Jassar P *et al.*
Spencer MG, Chondroplastic graft augmentation rhinoplasty. *Orig. Art.* **104**: 539
Spencer MG, Mackay AA, Viability of chondroplastic graft. *Clin. Rec.* **106**: 166
Spitzen T *see* Stern and Spitzen
Spitzer O *see* Gordon CR *et al.*
Spraggs PDR, Radiological diagnosis of spheno-choanal polyp. *Rad. Focus* **107**: 159
Spraggs PDR, Harries ML, The modified Valsalva manoeuvre to improve visualization of the hypopharynx during flexible nasopharyngoscopy. *Short Comm.* **109**: 863
Spraggs PDR, Macnamara M, Joseph T, A prospective randomized study to assess the efficacy of post-operative nasal medication after endonasal surgery. *Orig. Art.* **109**: 618
Spraggs PDR, Perry A, Cheesman AD, The 'Allan Johnson' voice prosthesis. A modification of the Bivona voice prosthesis for immediate post-fitting aphonia after secondary tracheo-oesophageal puncture. *Short Comm.* **108**: 579
Spraggs PDR, Rose DSC, Grant HR, Gallimore AP, Post-irradiation carcinosarcoma of the parotid gland. *Path. Focus* **108**: 443
Spraggs PDR, *see also* Grant A *et al.*; Greig AVH *et al.*; Ingrams DR *et al.*; McBrien F *et al.*; Sharp HR *et al.*
Squadrelli-Saraceno M *see* Siodlak MA *et al.*
Srinivasan S, Nehru VI, Mann SBS, Sharma VK, Bapuraj JR, Das A, Study of ethmoid sinus involvement in multibacillary leprosy. *Orig. Art.* **112**: 1038
Srinivasan V, Arasaratnem RBS, Jankelowitz GA, Day-case septal surgery under general anaesthesia and local anaesthesia with sedation. *Orig. Art.* **109**: 614
Srinivasan V, Deans JAJ, Nicol A, Sphenoid sinus schwannoma treated by endoscopic excision. *Clin. Rec.* **113**: 466
Srinivasan V, Ganesan S, Premachandra DJ, Lipoma of the parotid gland presenting with facial palsy. *Clin. Rec.* **110**: 93
Srinivasan V, Premachandra DJ, Use of a disposable electrode for recurrent laryngeal nerve monitoring. *Short Comm.* **112**: 561
Srinivasan V, *see also* Cuddihy and Srinivasan; Prior AJ *et al.*
Stables GI *see* Nicol JW *et al.*
Stack J *see* Fenton JE *et al.*
Stafford FW *see* Smith and Stafford; Welch AR *et al.*
Stafford N, Waldron J, Davies D, Walsh-Waring G, Smith R: Complications following fast neutron therapy for head and neck cancer. *Orig. Art.* **106**: 144
Stafford N, *see also* Connolly AAP *et al.*
Stafford ND *see* Connolly AAP *et al.*; Dilkes MG *et al.*; Ingrams DR *et al.*; Jassar P *et al.*
Stafford NDS *see* Toynton SC *et al.*
Štajner-Katušić S *see* Handžić-Ćuk J *et al.*
Stammberger H *see* Habermann W *et al.*
Stangerup S-E, Drozdziewicz D, Tos M, Trabalzini F, Surgery for acquired cholesteatoma in children: long-term results and recurrency of cholesteatoma. *Orig. Art.* **112**: 742
Stangerup S-E, Schwer S, Pedersen K, Brofeldt S, Niebuhr M, Prevalence of eardrum pathology in a cohort born in 1955. *Orig. Art.* **109**: 281
Stangerup S-E, Tjernström Ö, Harcourt J, Klokker M, Stokholm J, Barotitis in children after aviation: prevalence and treatment with Otovent. *Orig. Art.* **110**: 625
Stangerup S-E, *see also* Sorribes MM *et al.*
Stanković P *see* Petrović Z *et al.*
Stanley RE *see* Chew KK *et al.*; Leong HK *et al.*; Sethi DS *et al.*; Sethi and Stanley
Stansbie JM *see* Bhat and Stansbie; Pahor and Stansbie; Scott A *et al.*; Scott and Stansbie; Wake M *et al.*
Stanworth D *see* Drake-Lee A *et al.*
Stavroulaki P *see* Manolopoulos L *et al.*
Stearns MP *see* Alusi GH *et al.*; Robinson AC *et al.*; Solomons and Stearns
Steel KP *see* Bussoli and Steel; Hardisty RE *et al.*
Stefanescu H, JLO BACO Fellowship Report **113**: 1128
Stegnjajic A *see* Alvi and Stegnjajic
Stel HV *see* van Ingen G *et al.*
Stell PM, Prognosis in mouth cancer: host factors. *Orig. Art.* **106**: 399
Stell PM, *see also* Ell and Stell; Jones AS *et al.*; McCombe and Stell; Siodlak MA *et al.*; Viani L *et al.*; Vreeburg GCM *et al.*

Stenfors L-E, Olsen EG, Henriksen AO, Pars flaccida in tissue culture: Morphological study. *Orig. Art.* **104**: 91
Stenfors L-E, Räisänen S, Attachment of bacteria to tonsillar epithelium during acute tonsillitis. *Orig. Art.* **105**: 29
Stenfors L-E, Räisänen S, Bacterial attachment *in vivo* to epithelial cells of the nasopharynx during otitis media with effusion. *Orig. Art.* **106**: 111
Stenfors L-E, Räisänen S, Immunoglobulin-coated bacteria on the tonsillar surface during infectious mononucleosis. *Orig. Art.* **110**: 339
Stenfors L-E, Räisänen S, Quantitative analysis of the bacterial findings in otitis media. *Orig. Art.* **104**: 749
Stenfors L-E, Räisänen S, Secretory IgA and IgG-coated bacteria in chronically discharging ears. *Orig. Art.* **105**: 515
Stenfors L-E, *see also* Lilja M *et al.*; Nieminen P *et al.*; Olsen and Stenfors; Tikkakoski T *et al.*
Stephen MR *see* Watson C *et al.*
Stephens D, Some traditional treatments of hearing problems in Brittany and Wales. *Hist. Art.* **107**: 391
Stephens D, Orzan E, Galleti di San Cataldo F, Giuseppe Gradenigo and his contributions to Audiology. *Hist. Art.* **111**: 418
Stephens SDG, St Cadoc and the healing of the deaf. *Orig. Art.* **104**: 1
Stephens SDG, *see also* Newton VE *et al.*; Sadlier and Stephens
Stern Y, Spitzen T, Retrograde intubation of the trachea. *Orig. Art.* **105**: 746
Stern Y, *see also* Shpitzer T *et al.*
Steven JC *see* Parker AJ *et al.*
Stevens JC *see* Parker AJ *et al.*
Stevenson DS, Proops DW, Phelps PD, Severe cochlear dysplasia causing recurrent meningitis: a surgical lesson. *Clin. Rec.* **107**: 726
Stevenson DS, Proops DW, Wake MJC, Deadman MJ, Worrollo SJ, Hobson JA, Osseointegrated implants in the management of childhood ear abnormalities: the initial Birmingham experience. *Orig. Art.* **107**: 502
Stevenson DS, Webster G, Stewart IA, Acute tonsillectomy in the management of infectious mononucleosis. *Orig. Art.* **106**: 989
Stevenson J, Acute bacterial thyroiditis presenting as otalgia. *Clin. Rec.* **105**: 788
Stevenson M *see* Drake-Lee A *et al.*
Stewart A *see* Molony NC *et al.*
Stewart D *see* Wiet RJ *et al.*
Stewart IA *see* Ruske DR *et al.*; Stevenson DS *et al.*
Stewart M *see* Haider-Ali AM *et al.*
Stewart TJ *see* Capper R *et al.*; Mairs and Stewart
Stidley C *see* Wong G *et al.*
Stirling R *see* Cumberwoth VL *et al.*; Morrissey G *et al.*
Stjernquist-Desatnik A, Prellner K, Schalén C, High recovery of *Haemophilus influenzae* and group A Streptococci in recurrent tonsillar infection or hypertrophy as compared with normal tonsils. *Orig. Art.* **105**: 439
Stjernquist-Desatnik A, Samuelson P, Walder M, Penetration of penicillin V to tonsillar surface fluid in healthy individuals and in patients with acute tonsillitis. *Orig. Art.* **107**: 309
Stojčić G *see* Petrović Z *et al.*
Stokes M *see* Ruddy J *et al.*
Stokholm J *see* Stangerup S-E *et al.*
Stollwerck L *see* Graham J *et al.*
Stomeo F *see* Teatini GP *et al.*
Stone P *see* Houghton DJ *et al.*
Stoney PJ, Chakrabarti MK, Experience of pulse oximetry in children with croup. *Orig. Art.* **105**: 295
Stoney PJ, Davies W, Ho SF, Paterson IC, Griffith IP, Wegener's granulomatosis in two siblings: a family study. *Clin. Rec.* **105**: 123
Stopps K, Macdonald F, Linkage analysis and the tracking of susceptibility genes. *Mol. Biol.* **112**: 323
Strachan D, Sudden sensorineural deafness and hormone replacement therapy. *Clin. Rec.* **110**: 1148
Strachan D, Kamath B, Wengraf C, How we do it: use of a venous cannulation needle for endoscopic teflon injection to the vocal folds. *Short Comm.* **109**: 1184
Strachan DP, Impedance tympanometry and the home environment in seven-year-old children. *Orig. Art.* **104**: 4
Strachan DR, Grace ARG, Jackson IJB, Richardson GL, Use of the Carden anaesthetic tube for surgery around a tracheostome. *Short Comm.* **108**: 46
Strachan DR, *see also* Bradwell RA *et al.*; England RJA *et al.*
Strachan T *see* Evans DGR *et al.*; Neary WJ *et al.*
Strander H *see* Dueñas L *et al.*
Strauss M, Saccogna PW, Allphin AL, Cephazolin and metronidazole prophylaxis in head and neck surgery. *Orig. Art.* **111**: 631
Stringfellow HF, Khan IA, Sissons MCJ, Solitary fibrous tumour arising in the nasal cavity. *Clin. Rec.* **110**: 468
Stucker FJ *see* Qiu WW *et al.*
Stylopoulos N *see* Ferrerio and Stylopoulos
Su AP *see* Choy and Su
Su C-Y, Valve section of the eustachian tube. *Orig. Art.* **109**: 486
Su C-Y, Hwang C-F, Near total laryngopharyngectomy with pectoralis major myocutaneous flap in advanced pyriform carcinoma. *Orig. Art.* **107**: 817
Su C-Y, *see also* Hwang C-F *et al.*; Liu and Su; Wu C-M *et al.*
Suárez C *see* Llorente JL *et al.*; Rodrigo JP *et al.*
Subburaman N, Chaurasia MK, Skull base osteomyelitis interpreted as malignancy. *Rad. Focus* **113**: 775
Suen WM *see* Porter MJ *et al.*
Sugiachi Y *see* Suzuki Y *et al.*
Sugimoto T, Wakizono S, Uemura T, Tsuneyoshi M, Enjoji M, Malignant oncocytoma of the parotid gland: a case report with an immunohistochemical and ultrastructural study. *Path. Focus* **107**: 69
Sugimoto T, *see also* Hisashi K *et al.*; Kitamura K *et al.*
Sugita K *see* Takasaki T *et al.*
Sugita R *see* Watanabe K *et al.*
Suh B-D *see* Cho J-H *et al.*
Sulsenti G *see* Sarandeses-García A *et al.*
Sulter AM *see* Dikkers and Sulter
Summerfield MJ, White PS, Ventilation tube insertion using topical anaesthesia in children. *Short Comm.* **106**: 427
Sun D *see* Mu L *et al.*
Sun K-M *see* Wang D-H *et al.*
Sun XY *see* Huang H *et al.*
Sun ZH *see* Yue WL *et al.*
Sundaram KR *see* Tandon DA *et al.*
Sungupta SK *see* Vele DD *et al.*
Sungur A *see* Sennaroğlu L *et al.*
Süoglu Y, Erdamar B, Cölhan I, Katirrioglu OS, Çevikbas U, Tuberculosis of the parotid gland. *Path. Focus* **112**: 588
Suonpaa J *see* Joensuu H *et al.*
Suryanarayana KV *see* Bhatoe HS *et al.*
Sütay S, Guneri EA, Gunbay MU, Spontaneous regression of a symptomatic laryngopyocele. *Clin. Rec.* **108**: 60
Sütay S, Tekinsoy B, Ceryan K, Aksoy Y, Submaxillary hypoglossal neurilemmoma. *Clin. Rec.* **107**: 953
Sütay S, *see also* Güneri A *et al.*; Güneri *et al.*
Sütbeyaz V, Selimoğlu E, Karasen M, Ciftcioglu A, Öztürk A, Haemangiopericytoma of the middle ear: case report and literature review. *Clin. Rec.* **109**: 977
Sütbeyaz Y *see* Karaşen RM *et al.*; Murat Karasen R *et al.*; Selimoğlu E *et al.*
Sutter R, Grossenbacher R, Resection of palatal tumours with the CO_2 laser. *Orig. Art.* **104**: 20
Suvarna SK *see* Whitworth IH *et al.*
Suzuki J-I *see* Kaga K *et al.*; Suzuki Y *et al.*
Suzuki M, Ichimiya I, Matsushita F, Mogi G, Histological features and prognosis of patients with mucoepidermoid carcinoma of the parotid gland. *Orig. Art.* **112**: 944
Suzuki M, Nishida I, Hirakawa K, Nikaido M, Harada Y, Cochlear fistula found in a naturally healed tympanic cavity. *Clin. Rec.* **105**: 656
Suzuki M, *see also* Takimoto T *et al.*
Suzuki T *see* Ohguro S *et al.*
Suzuki Y, Kaga K, Sugiachi Y, Ishii T, Suzuki J-I, Takiguchi T, Sudden bilateral hearing loss due to gastric carcinoma, and its histological evidence. *Orig. Art.* **111**: 1142
Svendstrup F, Husby M, Parenchymal pulmonary endometriosis. *Clin. Rec.* **105**: 235
Svetitsky PV, Effect of microwave and ionizing radiation in patients with recurrent laryngeal carcinoma. *Orig. Art.* **104**: 704

Swan IRC, Browning GG, A prospective evaluation of direct referral to audiology departments for hearing aids. *Orig. Art.* **108**: 120
Swanston AR *see* Prior and Swanston
Swift AC, Charlton G, Sinusitis and the acute orbit in children. *Orig. Art.* **104**: 213
Swift AC, Denning DW, Skull base osteitis following fungal sinusitis. *Clin. Rec.* **112**: 92
Swift AC, *see also* Al-Jassim and Swift; Karkanevatos A *et al.*; Sherman IW *et al.*
Swindell R *see* Slevin NJ *et al.*
Syed A, van Hasselt CA, To KF, Pigmented villonodular synovitis of the temporomandibular joint. *Clin. Rec.* **107**: 853
Symeonidis V *see* Daniilidis J *et al.*
Symon L *see* Vowles R *et al.*
Syrjänen K *see* Nuutinen J *et al.*
Szepezi S *see* Klima A *et al.*
Szilvassy J, Czigner J, Jori J, Toth F, Szilvassy Z, de Mora Mieszkowski J, Kiss JG, Cochlear implantation of a Hungarian deaf and blind patient with discharging ears suffering from Behçet's disease. *Clin. Rec.* 169
Szilvassy J, Czigner J, Somogyi I, Jori J, Kiss JG, Szilvassy Z, Cochlear implantation in a patient with grand mal epilepsy. *Clin. Rec.* **112**: 567
Szilvassy Z *see* Szilvassy J *et al.*
Szutowicz HE *see* Gray RF *et al.*

Tabchy B *see* Abboud B *et al.*
Tadpatrikar MH *see* Johnson IJM *et al.*
Taguchi K *see* Sakaguchi M *et al.*
Tahsin A *see* Mustafa and Tahsin
Taibah A *see* Aslan A *et al.*; Bhatia S *et al.*; *see* Chashaba A *et al.*
Taibah AK *see* Gamoletti R *et al.*; Naguib MB *et al.*; Saleh E *et al.*
Taibah K, Ahmed M, Baessa E, Saleem M, Rifai A, Al-Arifi A, An unusual cause of obstructive sleep apnoea presenting during pregnancy. *Clin. Rec.* **112**: 1189
Tait R *see* Al-Sader MH *et al.*
Taitelbaum R *see* Cinamon U *et al.*
Takahashi H *see* Ikeda M *et al.*; Sakakura A *et al.*; Yamamoto Y *et al.*
Takahashi K *see* Kitamura K *et al.*
Takahashi M *see* Harada H *et al.*; Yamashita Y *et al.*
Takahashi S *see* Tsunoda K *et al.*
Takano-Yamamoto T *see* Li D-J *et al.*
Takanozawa M *see* Tsunoda K *et al.*
Takasaka T *see* Watanabe K *et al.*
Takasaki T, Higashikawa M, Motoyama S, Sugita K, Kurane I, Serum antibodies to human herpesvirus 7, human herpesvirus 6 and cytomegalovirus in patients with idiopathic facial nerve palsy or sudden deafness. *Orig. Art.* **112**: 617
Takasaki T, *see also* Sakakura A *et al.*
Takashima H *see* Miyaguchi M *et al.*
Takashima S *see* Wang Q *et al.*
Takayama E, Ikeda M, Tsuru S, Ogura M, Kitahara S, Inouye T, Healy GB, Is injectable collagen truly safe? *Orig. Art.* **106**: 704
Takayama E, *see also* Kitahara S *et al.*
Takayama F *see* Wang Q *et al.*
Takeno S *see* Wake M *et al.*
Takeyama I *see* Kato I *et al.*
Takiguchi T *see* Suzuki Y *et al.*
Takimoto T, Itoh M, Parapharyngeal abscess associated with the second pharyngeal pouch. *Clin. Rec.* **107**: 456
Takimoto T, Saito Y, Suzuki M, Nishimura T, Radiation-induced cranial nerve palsy: hypoglossal nerve and vocal cord palsies. *Clin. Rec.* **105**: 44
Takimoto T, Yoshizaki T, Ohoka H, Sakashita H, Fourth branchial pouch anomaly. *Clin. Rec.* **104**: 905
Takimoto T, *see also* Noshimura T *et al.*
Takooda S *see* Kato S *et al.*
Talamini R *see* Barzan L *et al.*
Talbot A, Tonkin J, Fagan P, Platt-Hepworth S, Vestibular schwannoma in an only hearing ear. *Clin. Rec.* **108**: 983
Talbot AR, Laryngeal amyloidosis. *Clin. Rec.* **104**: 147
Talbot AR, Paraganglioma of the maxillary sinus. *Clin. Rec.* **104**: 248
Talmi YP, Minimizing complications in neck dissection. *Rev. Art.* **113**: 101
Talmi YP, Bedrin L, Waller A, Horowitz Z, Skurnik Y, Adunski A, Kronenberg J, Second primary cancer of the larynx in patients with lung cancer. *Orig. Art.* **112**: 252
Talmi YP, Cotlear D, Waller A, Horowitz Z, Adunski A, Roth Y, Kronenberg J, Distant metastases in terminal head and neck cancer patients. *Orig. Art.* **111**: 454
Talmi YP, Halpern M, Finkelstein Y, Gal R, Zohar Y, True malignant mixed tumour of the parotid gland. *Path. Focus* **104**: 360
Talmi YP, Wolfe GT, Hazuka M, Krause CJ, Unknown primary of the head and neck. *Orig. Art.* **110**: 353
Talmi YP, *see also* Finkelstein Y *et al.*
Talmon Y *see* Samet A *et al.*
Tamagawa V, Kitamura K, Miyata M, Branchial cyst of the nasopharynx: resection via the endonasal approach. *Clin. Rec.* **109**: 139
Tammam N *see* Jamal A *et al.*
Tamura A *see* Kaga K *et al.*
Tan HKK *see* Kwong Fah and Tan; Sim and Tan; Soh KBK *et al.*
Tan J *see* Cai Z *et al.*
Tan KK *see* Gibb AG *et al.*
Tan L *see* Gardiner Q *et al.*
Tan LKS *see* Tay and Tan
Tan NG *see* Goh and Tan
Tanaka H *see* Haraguchi H *et al.*; Ito S *et al.*
Tanaka M *see* Nakashima T *et al.*; Yoshihara T *et al.*
Tanaka S, Kimura Y, Furukawa M, Pseudoaneurysm of the carotid artery with haemorrhage into the hypopharynx. *Clin. Rec.* **109**: 889
Tanaka S, *see also* Kimura Y *et al.*
Tanaka T *see* Ichimura and Tanaka
Tanaka Y, Yoshida Y, Hirano M, CGRP-immunoreactive cells supplying laryngeal sensory nerve fibres in the cat's nodose ganglion. *Orig. Art.* **107**: 916
Tanaka Y, Yoshida Y, Hirano M, Expression of Fos-protein activated by tactile stimulation on the laryngeal vestibulum in the cat's lower brain stem. *Orig. Art.* **109**: 39
Tanaka Y, Yoshida Y, Hirano M, Morimoto M, Kanaseki T, Distribution of SP- and CGRP- immunoreactivity in the cat's larynx. *Orig. Art.* **107**: 522
Tandon DA, Bahadur S, Laldina HC, Sundaram KR, Role of prophylactic antibiotics in surgery for advanced head and neck cancer. *Orig. Art.* **106**: 621
Tandon DA, Bahadur S, Misra NK, Deka RC, Kapila K, Parapharyngeal neurofibromas. *Orig. Art.* **106**: 243
Tandon DA, Bahadur S, Rath GK, Carcinoma of the soft palate. *Orig. Art.* **106**: 130
Tandon DA, *see also* Bahadur S *et al.*; Kakani RS *et al.*; Singh AM *et al.*; Thakar A *et al.*
Tandon P *see* Coales UF *et al.*
Tang C-K *see* Klumpp TR *et al.*
Tang NLS, Choy ATK, John DG, van Hasselt CA, The otological status of patients with nasopharyngeal carcinoma after mega-voltage radiotherapy. *Orig. Art.* **106**: 1055
Tankwal PM *see* Hathiram BT *et al.*
Tanner NSB *see* Shotton JC *et al.*
Targam A *see* Moustafa H *et al.*
Tariq M, Gluckman P, Thebe P, Metastatic testicular teratoma of the nasal cavity: a rare cause of severe intractable epistaxis. *Clin. Rec.* **112**: 1078
Tariq M *see also* Kalan A *et al.*
Tarlow MJ *see* Richardson MP *et al.*
Taskin M *see* Kacker and Taskin
Taskinalp O *see* Uzun C *et al.*
Taskoparan G *see* Akin I *et al.*
Tassignon MJ *see* Vanden Abeele D *et al.*
Tassone P *see* Worley GA *et al.*
Tatemoto K *see* Hisa Y *et al.*
Tatsukawa T *see* Hirakawa K *et al.*
Tausjø J *see* Natvig K *et al.*
Tavin ME, Rubin JS, Camacho FJ, Sudden sensorineural hearing loss in haemoglobin SC disease. *Clin. Rec.* **107**: 831
Tavio M *see* Barzan L *et al.*
Tay HL, Post-operative morbidity in electrodissection tonsillectomy. *Orig. Art.* **109**: 209
Tay HL, Post-tonsillectomy pain with selective diathermy haemostasis. *Orig. Art.* **110**: 446

Tay HL, Howitt RJ, Heterotopic pleomorphic adenoma in the neck. *Clin. Rec.* **109**: 445
Tay HL, Hussain SSM, The management of aural polyps. *Rev. Art.* **111**: 212
Tay HL, Mills RP, The assessment of hearing results following surgery for otitis media with effusion using the Glasgow Benefit Plot. *Orig. Art.* **108**: 733
Tay HL, Mills RP, Tympanic membrane atelectasis in childhood otitis media with effusion. *Orig. Art.* **109**: 495
Tay HL, Reilly PG, Akosa AB, Salivary terminal duct carcinoma. *Clin. Rec.* **106**: 649
Tay HL, Tan LKS, Surgical bone wax causing epistaxis. *Clin. Rec.* **110**: 267
Tay HL, Vaughan-Jones R, Qureshi SS, Ethmoidal sarcoidosis. *Clin. Rec.* **108**: 682
Tayama N *see* Ichimura K *et al.*
Taylor J, Tighe JVP, A minor salivary gland tumour presenting with dysphagia. *Clin. Rec.* **113**: 569
Taylor JFN *see* Umapathy N *et al.*
Taylor PH *see* de Carpentier JP *et al.*; Simo R *et al.*
Taylor RH *see* Robertson A *et al.*
Taylor WJ *see* Banfield GK *et al.*
Teatini GP, Stomeo F, Bozzo C: Transnasal sinusectomy with combined microscopic and endoscopic technique. *Orig. Art.* **105**: 635
Tec H *see* Hussain SSM *et al.*
Tekinsoy B *see* Sutay S *et al.*
Telatar M *see* Yildiz K *et al.*
Telian SA *see* Shone G *et al.*
Telios G *see* Watson MG *et al.*
Telischi FF *see* Frau GN *et al.*
Tell L *see* Feinmesser M *et al.*
Temperely I *see* Conlon B *et al.*
Temple RH, Axon PR, Ramsden RT, Keles N, Deger K, Yucel E, Auditory rehabilitation in neurofibromatosis type 2: a case for cochlear implantation. *Clin. Rec.* **113**: 161
Temple RH *see* Wheatley AH *et al.*
Temple RH *see also* Wheatley AH *et al.*
Tena AG *see* Gòmez Estanocona N *et al.*
Tenshin S *see* Cui P-C *et al.*; Li D-J *et al.*
Teotrakul S *see* Kangsanarak J *et al.*
Terris DJ, Tuffo KM., Fee WE, Modified facelift incision for parotidectomy. *Orig. Art.* **108**: 574
Terzis TF, Robinson JM, Use of hearing aids by patients with a closed mastoid cavity. *Orig. Art.* **105**: 174
Terzis TF *see* Sharp JF *et al.*
Tesei F, Farneti G, Cavicchi O, Antonelli P, Zanetti G, Leone O, A case of Merkel-cell carcinoma metastatic to the tonsil. *Path. Focus* **106**: 1100
Tessitori G *see* Poli P *et al.*
Tewary AK, Correlation between clinical response and injection quality in treatment of spasmodic dysphonia. *Orig. Art.* **110**: 551
Tewary AK, Day-case tonsillectomy: a review of the literature. *Orig. Art.* **107**: 703
Tewary AK, Riley N, Kerr AG, Long-term results of vestibular nerve section. *Orig. Art.* **112**: 1150
Tewary AK, Barr GS, Bickerton RC, Parental preferences for duration of hospital stay following tonsillectomy. *Orig. Art.* **107**: 709
Tewary AK, Cable HR, Barr GS, Steroids and control of post-tonsillectomy pain. *Orig. Art.* **107**: 605
Tewary AK, Curry AR, Same-day tonsillectomy. *Orig. Art.* **107**: 706
Tewary AK, Pahor AL, Leiomyosarcoma of the larynx: emergency laryngectomy. *Clin. Rec.* **105**: 134
Tewary AK, *see also* Barr and Tewary
Thabet H *see* Elwany S *et al.*; Elwany and Thabet
Thaha MA *see* Holland S *et al.*
Thakar A, Bahadur S, Tandon DA, Ranganathan A, Rath GK, Laryngeal preservation by treatment with induction chemotherapy and radiotherapy protocol for stage III & IV carcinoma larynx — results of a pilot study. *Orig. Art.* **113**: 433
Thakar A, Tandon DA, Bahadur S, Vijayaraghavan M, Extranotochordal chordoma presenting as multiple neck masses: report of a case. *Clin. Rec.* **107**: 942
Thakar A *see also* Papakostas K *et al.*
Thaker A *see* Kacker A *et al.*
Thaker H *see* Hajioff D *et al.*
Thakkar C *see* O'Reilly BJ *et al.*
Thakur S *see* Ogale SB *et al.*
Than T, Birch PJ, Dawes PJD, Verruciform xanthoma of the nose. *Path. Focus* **113**: 79
Theander C, Lödén B, Berglund J, Seidal T, Primary squamous carcinoma of the thyroid — a case report. *Clin. Rec.* **107**: 1155
Thebe P *see* Tariq M *et al.*
Theobald D *see* Ga Sze H *et al.*
Theodoropoulos PA *see* Alvi and Theodoropoulos
Thijssen HOM *see* van Leeuwen JPPM *et al.*
Thim L *see* Rejab E *et al.*
Thirlwall AS, Ortner's syndrome: a centenary review of unilateral recurrent laryngeal nerve palsy secondary to cardiothoracic disease. *Clin. Rec.* **111**: 869
Thirlwall AS, Bailey CM, Ramsay AD, Wyatt M, Laryngeal paraganglioma in a five-year-old child — the youngest case ever recorded. *Clin. Rec.* **113**: 62
Thomas DM, Abramovich S, Rakker-Thomas S, An unusual cause of cochlear implant failure. *Clin. Rec.* **109**: 542
Thomas DM, Wilkins MJ, Witana JS, Cook T, Jefferis AF, Walsh-Waring GP, Giant cell reparative granuloma of the cricoid cartilage. *Rad. Focus* **109**: 1120
Thomas DM *see* Hern JD *et al.*
Thomas DM *see also* Samuel D *et al.*
Thomas KM, Cumberworth VL, McEwan J, Orbital and skin metastases in a polymorphous low grade adenocarcinoma of salivary gland. *Path. Focus* **109**: 1222
Thomas M *see* Al-Khabori MJJ *et al.*; Nofal and Thomas
Thomas MR, Natarajan B, Garth RJN, The laryngectomee and swimming. *Rev. Art.* **109**: 481
Thomas MR, Nofal F, Cave APD, Dermoid cyst in the mouth: Value of ultrasound. *Clin. Rec.* **104**: 141
Thomas MR, Sadiq HA, Raweily EAA, Acanthoma fissuratum. *Clin. Rec.* **105**: 301
Thomas MR, Ward K, Al-Khabori M, Natarajan B, Oncocytic mixed nasal tumour. *Clin. Rec.* **107**: 732
Thomas MR *see* Pearson CR *et al.*
Thomas MR, *see also* Garth RJN *et al.*
Thomas R, Kameswaran M, Ahmed S, Khurana P, Morad N, Actinomycosis of the vallecula: report of a case and review of the literature. *Clin. Rec.* **109**: 154
Thomas R, Kameswaran M, Murugan V, Okafor BC, Sensorineural hearing loss in neurobrucellosis. *Clin. Rec.* **107**: 1034
Thomas R, Kumar EV, Kameswaran M, Shamim A, Al Ghamdi S, Mummigatty AP, Okafor BC, Post intubation laryngeal sequelae in an intensive care unit. *Orig. Art.* **109**: 313
Thomas RSA *see* Prichard AJN *et al.*
Thomas Westerman S *see* Golz A *et al.*
Thompson A *see* Pringle MB *et al.*
Thompson AC, Adult tonsillectomy — results and patient selection. *Orig. Art.* **105**: 836
Thompson AC, Bradley PJ, Iatrogenic epidermoid cyst of the parotid region following ear surgery. *Clin. Rec.* **105**: 227
Thompson AC, Crowther JA, Effect of nasal packing on Eustachean tube function. *Orig. Art.* **105**: 539
Thompson AC, Lamey PJ, Kawasaki syndrome in an adult. *Clin. Rec.* **104**: 37
Thompson AC, Shall L, Moralee SJ, Darier's disease of the external ear. *Clin. Rec.* **106**: 725
Thompson H *see* Lee SJ *et al.*
Thompson I *see* Hari CK *et al.*
Thompson P *see* Pfleiderer AG *et al.*
Thompson PG *see* Harrison HC *et al.*
Thompson RA *see* Snow DG *et al.*
Thompson SD *see* Hilger AW *et al.*
Thomsen J *see* Buchwald C *et al.*; Charabi S *et al.*; Nielsen TR *et al.*
Thomson MP *see* Riley N *et al.*
Thomson N *see* Blackshaw and Thomson
Thornton F *see* Baguley DM *et al.*
Thorp M *see* Mortimore and Thorp
Thorp MA, Kruger J, Oliver S, Nilssen ELK, Proscott CAJ, The antibacterial activity of acetic acid and Burow's solution as topical otological preparations. *Orig. Art.* **112**: 925
Thorp MA, Langman G, Sellars SL, Angiocentric T-cell lymphoma: an extensive lesion involving the posterior tongue, hypopharynx and supraglottis. *Clin. Rec.* **113**: 263

Thorp MA, *see also* Mortimore S *et al.*
Thorpe PA *see* Gonzalez-Garcia J *et al.*
Tierney P *see* Sarker SK *et al.*
Tierney PA, Farag I, Saunders CAB, The use of positron emission tomography and computed tomography in the assessment of trismus associated with head and neck malignancy. *Rad. Focus* **112**: 303
Tierney PA, Francis I, Morrison GAJ, Acquired subglottic cysts in the low birth weight pre-term infant. *Clin. Rec.* **111**: 478
Tierney PA *see* Samuel D *et al.*
Tighe JVP *see* Taylor and Tighe
Tikkakoski T, Stenfors L-E, Typpö T, Lohela P, Apaja-Sarkkinen M, Parathyroid adenomas: pre-operative localization with ultrasound combined with fine-needle biopsy. *Orig. Art.* **107**: 543
Tikkakoski TA *see* Siniluoto TMJ *et al.*
Tilve GH *see* de Souza C *et al.*; de Souza CE *et al.*
Timms MS *see* de Carpentier JP *et al.*; Lobo CJ *et al.*; Ramsden and Timms
Timon C *see* Freund and Timon; Smyth DA *et al.*
Timon CI, Brown D, Dardick I, Hyoid bone tumour mass presenting with cervical nodal metastasis. *Path. Focus* **107**: 967
Timon CI *see* Donnelly MJ *et al.*; Fenton JE *et al.*; Lacy PD *et al.*; Pollock AM *et al.*
Timon CV *see* Conlon BJ *et al.*
Timon CVI, Brown D, Gullane P, Internal jugular vein blowout complicating head and neck surgery. *Clin. Rec.* **108**: 423
Timon CVI *see* Curran AJ *et al.*; Lacy PD *et al.*
Tindall B *see* Harrison HC *et al.*
Tirelli U *see* Barzan L *et al.*
Tiwari R, Experiences with the sternocleidomastoid muscle and myocutaneous flaps. *Orig. Art.* **104**: 315
Tiwari R, Snow GB, van der Waal I, Reconstruction of the mandible with conventional bone graft: an evaluation. *Orig. Art.* **108**: 969
Tiwari R *see* Patel P *et al.*
Tiwari RM *see* Önder T *et al.*; van Ingen G *et al.*
Tjellström A *see* Heo SJ *et al.*
Tjellström I, Granström G, One-stage procedure to establish osseointegration: a zero to five years follow-up report. *Orig. Art.* **109**: 593
Tjernström Ö *see* Stangerup S-E *et al.*
To KF *see* John DG *et al.*; *see* Syed A *et al.*
To SS *see* Daya and To
Todd CEC *see* Watkinson JC *et al.*
Todd GB, Audit of the incidence of persistent perforation of the tympanic membrane following grommet removal or extrusion. *Orig. Art.* **107**: 593
Todd GB, Audit of the incidence of persistent perforation of the tympanic membrane following T-tube removal or extrusion. *Orig. Art.* **107**: 590
Todd GB *see* Singh V *et al.*
Todd JG *see* Ah-See RW *et al.*
Toft A *see* Johansen M *et al.*
Toi M *see* Kasuga Y *et al.*
Tokano H *see* Ishikawa N *et al.*; Muraoka H *et al.*
Toledano A *see* Bernáldez R *et al.*
Tolley N *see* Benson-Mitchell R *et al.*; Porter MJ *et al.*
Tolley NS, Phelps PD, Patulous Eustachian tube: A radiological perspective. *Orig. Art.* **104**: 291
Tolley NS, Ison K, Mirza A, Experimental studies on the acoustic properties of mastoid cavities. *Orig. Art.* **106**: 597
Tolley NS, Lloyd GAS, Williams HOL, Radiological study of primary spontaneous CSF rhinorrhoea. *Orig. Art.* **105**: 274
Tolley NS *see* Commins DJ *et al.*; Ghufoor K *et al.*; Hern JD *et al.*; Hollis LJ *et al.*; Mochloulis G *et al.*; Montgomery P *et al.*; Sarker SK *et al.*
Tolley NS, *see also* Oyarzabal MF *et al.*
Tolu I *see* Erkan M *et al.*
Toma A *see* Fisher EW *et al.*
Toma AG, Blanshard J, Eynon-Lewis N, Bridger MW, Post-tonsillectomy pain: the first ten days. *Orig. Art.* **109**: 963
Toma AG, Fisher EW, Cheesman AD, Autologous fibrin glue in the repair of dural defects in craniofacial resections. *Short Comm.* **106**: 356
Toma AG, Fisher EW: Osteoma of the external auditory meatus presenting as an aural polyp. *Clin. Rec.* **107**: 935
Toma AG *see* Davis JP *et al.*
Tomás M *see* Moñuz A *et al.*
Tomás MD, Torres A., Garcia-Polo J, Gavilán C, Life-threatening cervico-mediastinal haematoma after carotid sinus massage. *Clin. Rec.* **105**: 381
Tomasi J-P *see* Cao M-Y *et al.*
Tomita H *see* Watanabe Y *et al.*
Tomkinson A, Craven C, Brown MJKM, Palatal myoclonus affected by neck position. *Clin. Rec.* **109**: 61
Tomkinson A, Mills RGS, Cantrell PJ, The pathophysiology of otitic hydrocephalus. *Clin. Rec.* **111**: 757
Tomkinson A, Roblin DG, Quine SM, Flanagan P, Tympanic thermometry and minor ear surgery. *Short Comm.* **110**: 454
Tomkinson A *see* Quine SM *et al.*; Reynolds JM *et al.*
Toner JG, Walby AP, Comparison of electro- and chemical cautery in the treatment of anterior epistaxis. *Orig. Art.* **104**: 617
Toner JG, John G, McNaboe EJ, Cochlear implantation under local anaesthesia, the Belfast experience. *Orig. Art.* **112**: 533
Toner JG, Smyth GDL, Comparison of methods of evaluating hearing benefit of middle ear surgery. *Orig. Art.* **107**: 4
Toner JG, Smyth GDL, Kerr AG, Realities in ossiculoplasty. *Orig. Art.* **105**: 529
Toner JG *see* Camilleri AE *et al.*; Hampton SM *et al.*
Toner JG, *see also* Moffat DA *et al.*
Toner M *see* Pollock AM *et al.*
Tong FM, Chow SK, Primary tuberculous tracheitis. *Clin. Rec.* **112**: 579
Tong MCF, Woo JKS, van Hasselt CA, A double-blind comparative study of ofloxacin otic drops versus neomycin-polymyxin b-hydrocortisone otic drops in the medical treatment of chronic suppurative otitis media. *Orig. Art.* **110**: 309
Tong MCF *see* Ku PKM *et al.*
Tong MDF *see* Rushton HC *et al.*
Tonkin J *see* Talbot A *et al.*
Tono T, Ushisako Y, Morimitsu T, Cochlear implantation in an intralabyrinthine acoustic neuroma patient after resection of an intracanalicular tumour. *Clin. Rec.* **110**: 570
Tony MCF *see* Choy ATK *et al.*
Tooke JE *see* Flynn MD *et al.*
Topcu Í *see* Osma Ü *et al.*
Topham J *see* Harkness P *et al.*
Torca J *see* Gòmez Estanocona N *et al.*
Toriyama Y *see* Kosaki H *et al.*
Torkut A *see* Akin I *et al.*
de la Torre A *see* Regueiro CA *et al.*
Torre-Cisneros J *see* Navarro Cunchillos M *et al.*
Torres A *see* Tomás MD *et al.*
Torres J *see* Cánovas DL *et al.*
Tos M, Lau T, Arndal H, Plate S, Tympanosclerosis of the middle ear: Late results of surgical treatment. *Orig. Art.* **104**: 685
Tos M *see* Buchwald C *et al.*; Charabi S *et al.*; Nandapalan and Tos; Stangerup S-E *et al.*; Turgut and Tos
Tos M, *see also* Møller and Tos
Toskala E, Nuutinen J, Rautiainen M, Scanning electron microscopy findings of human respiratory cilia in chronic sinusitis and in recurrent respiratory infections. *Orig. Art.* **109**: 509
Tostevin P *see* Kirkland and Tostevin
Tostevin PMJ, de Bruyn R, Hosni A, Evans JNG, The value of radiological investigations in pre-endoscopic of children with stridor. *Orig. Art.* **109**: 844
Tostevin PMJ, Hollis LJ, Bailey CM, Pharyngeal trauma in children — accidental and otherwise. *Orig. Art.* **109**: 1168
Tostevin PMJ *see* Hicklin L *et al.*
Toth F *see* Szilvassy J *et al.*
Tovi F, Gatot A, Fliss DM: Air cyst of the maxillary sinus (*Pneumosinus dilatans*, pneumocoele). *Clin. Rec.* **105**: 673
Tovi F, Gatot A, Hertzanu Y, CT demonstration of metastatic anaerobic orbital abscess. *Rad. Focus* **105**: 1086
Tovi F *see* Bar-Lavie Y *et al.*; Bodner L *et al.*
Tovi F, *see also* Leibermann A *et al.*; Levy I *et al.*
Tow S *see* Leong HK *et al.*
Townsley P *see* Natarajan B *et al.*
Toynton S *see* Al-Saati A *et al.*
Toynton SC, Wilkins MJ, Cook HT, Stafford NDS, True malignant mixed tumour of a minor salivary gland. *Path. Focus* **108**: 76
Toynton SC *see also* Bath AP *et al.*
Trabalzini F *see* Stangerup S-E *et al.*

Traissac L *see* Carrat X *et al.*
Tran Ba Huy P *see* Marianowski R *et al.*
Tranter RM *see* van Eeden S *et al.*
Traub P *see* Hickey SA *et al.*
Tremoulet M *see* Deguine L *et al.*
Trendell-Smith NJ, Oates J, Crocker J, The evaluation of salivary gland tumours using proliferating cell nuclear antigen. *Orig. Art.* **111**: 551
Triantos S *see* Lefantzis D *et al.*
Triglia J-M, Belus J-F, Nicollas R, Arytenoidopexy for bilateral vocal fold paralysis in young children. *Orig. Art.* **110**: 1027
Triglia JM *see* Dessi P *et al.*
Triglias JM, Portaspana T, Cannoni M, Pech A, Subglottic cyst in a newborn. *Clin. Rec.* **105**: 222
Trivelli M *see* Almadori G *et al.*
Trobbe O *see* Bjerkhoel and Trobbe
Trovò GM *see* Barzan L *et al.*
Tsai MH *see* Yen PT *et al.*
Tsakris A, Psifidis A, Douboyas J, Complicated suppurative otitis media in a Greek diver due to a marine halophilic *Vibrio* sp. *Clin. Rec.* **109**: 1082
Tsakris A *see* Manolis E *et al.*
Tsang RKY, Woo JKS, van Hasselt CA, Compartmentalized maxillary sinus mucocele. *Clin. Rec.* **113**: 1106
Tsang WYW, Chan JFC, Ho WK, Yu HC, Chow LTC, Extranodal Rosai-Dorfman disease: an uncommon cause of persistent nodule in the ear. *Clin. Rec.* **106**: 249
Tsang YW, Ngan KC, Chan JKC, Primary mucoid adenocarcinoma of the larynx. *Clin. Rec.* **105**: 315
Tsang YW, Tung Y, Chan JKC, Polymorphous low grade adenocarcinoma of the palate in a child. *Clin. Rec.* **105**: 309
Tsangaroulakis A *see* Kandiloros DC *et al.*
Tschang T-P *see* Chen KTK *et al.*
Tse A *see* Kumar BN *et al.*; Lee WC *et al.*; Walsh RM *et al.*
Tse KC *see* Wan SK *et al.*
Tseng T-C *see* Wang C-P *et al.*
Tsiakou E *see* Kastanioudakis I *et al.*
Tsiotos PD *see* Goumas P *et al.*
Tsukuda M *see* Kitahara S *et al.*; Mochimatsu I *et al.*; Nishimura G *et al.*
Tsuneyoshi M *see* Sugimoto T *et al.*
Tsunoda A, Lipoma in the peri-tonsillar space. *Clin. Rec.* **108**: 693
Tsunoda A, Komatsuzaki A, Muraoka H, Gou-Tsu K, A case with symptoms of vestibular neuronitis caused by an intramedullary lesion. *Clin. Rec.* **109**: 545
Tsunoda A, Yamada M, Komatsuzaki A, Influence of phylogeny on jugular fossa shape and otological disorder. *Orig. Art.* **111**: 1027
Tsunoda A *see* Muraoka H *et al.*; Tsutsumi T *et al.*; Yamada M *et al.*
Tsunoda K, Nosaka K, Housui M, Murano E, Ishikawa M, Imamura Y, A rare case of laryngeal myxoma. *Clin. Rec.* **111**: 271
Tsunoda K, Soda Y, Hoarseness as the initial manifestation of systemic lupus erythematosus. *Clin. Rec.* **110**: 478
Tsunoda K, Takahashi S, Takanosawa M, Shimoji Y, The influence of pregnancy on sensation of ear problems — ear problems associated with healthy pregnancy. *Orig. Art.* **113**: 318
Tsunoda K, Takanozawa M, Choh K, Sudden onset aphonia caused by a Japanese-style bath. *Clin. Rec.* **112**: 480
Tsunoda R, Fukaya T, Extracranial meningioma presenting as a tumour of the external auditory meatus: a case report. *Clin. Rec.* **111**: 148
Tsur H *see* Kaplan HY *et al.*
Tsuru S *see* Ikeda M *et al.*; Takayama E *et al.*
Tsuta Y *see* Hosoi H *et al.*
Tsutsumi K *see* Kato *et al.*
Tsutsumi T, Komatsuzaki A, An adequate parameter evaluating the galvanic body sway test: comparison with the caloric test in patients with vestibular schwannoma. *Orig. Art.* **113**: 118
Tsutsumi T, Oku T, Komatsuzaki A, Solitary plexiform neurofibroma of the submandibular gland. *Clin. Rec.* **110**: 1173
Tsutsumi T, Tsunoda A, Shimamoto K, Komatsuzaki A, Aberrant jugular bulb vein obstructing approach to intracanalicular vestibular schwannoma. *Clin. Rec.* **112**: 772
Tuffo KM *see* Terris DJ *et al.*
Tulbah A *see* Babu Manohar M *et al.*
Tunçkanat F *see* Şener B *et al.*
Tung Y *see* Tsang YW *et al.*
Tungekar MF, Tracheocarotid artery fistula infected with methicillin-resistant *Staphylococcus aureus*. *Path. Focus* **113**: 689
Tungekar MF *see* Harcourt and Tungekar
Tungland OP, Savage MO, Bellman SC, A new syndrome: hearing loss and familial salivary gland insensitivity to aldosterone in two brothers. *Orig. Art.* **104**: 956
Turan E *see* Sennaroğlu L *et al.*
Turgut S, Tos M, Correlation between temporal bone pneumatisation, location of the lateral sinus and length of the mastoid process. *Orig. Art.* **106**: 485
Türkütanit S *see* Başak S *et al.*
Turnbull LS *see* Roland NJ *et al.*
Turner J *see* Ajal M *et al.*; Buchanan DS *et al.*; Coakley DJ *et al.*; Fenton JE *et al.*
Turner JJ *see* Forrest AW *et al.*
Turner NO *see* O'Connell JE *et al.*; Watts SJ *et al.*
Turriziani A *see* Del Forno A *et al.*
Tuzuner N, Doğusoy G, Demirkesen C, Ozkan F, Altas K, Value of lymph node biopsy in the diagnosis of acquired toxoplasmosis. *Orig. Art.* **110**: 348
Tvinnereim M, Haight JS, Hansen RK, Cole P, A comparison between two methods of measuring pressure in the pharyngeal airway: transducer probe versus open catheter. *Orig. Art.* **109**: 414
Tweel Ivd *see* Ravasz LA *et al.*
Tyler S *see* Singh V *et al.*
Tyndel F *see* Heaton JM *et al.*
Typpö T *see* Tikkakoski T *et al.*
Tzagaroulakis A *see* Yiotakis J *et al.*
Tzounakos P *see* Ferekidis E *et al.*; Yiotakis J *et al.*

Udaipurwala IH *see* Iqbal K *et al.*
Udhi Kumar B *see* Dingle AF *et al.*
Udwadia RA, Maniar D, Acharya M, A transethmoid transorbital foreign body. *Rad. Focus* **108**: 441
Ueda H, Miyazawa T, Asahi K, Yanagita N, Factors affecting hearing results after stapes surgery. *Orig. Art.* **113**: 417
Ueda Y *see* Hoshino T *et al.*
Uemura T *see* Inamitsu M *et al.*; Sugimoto T *et al.*
Uesugi K *see* Kato I *et al.*
Uhari M *see* Niemelä M *et al.*
Umapathy N, Panesar J, Whitehead BF, Taytor JFN, Removal of a foreign body from the bronchial tree: a new method. *Clin. Rec.* **113**: 851
Umaria N, Chavda SV, Pahor AL, An unusual cause of nasal septum perforation. *Clin. Rec.* **113**: 1020
Ümit Isik A *see* Canbolat O *et al.*
Ünal ÖF, Ayhan A, Hoşal AS, Prognostic value of p53 expression and histopathological parameters in squamous cell carcinoma of oral tongue. *Orig. Art.* **113**: 446
Unanue JM *see* Gòmez Estanocona N *et al.*
Ündar L *see* Almaç A *et al.*
Ünlü Y, Ali Tekalan Ş, Cemiloğlu R, Ketenci İ, Kutluhan A, Guillotine and dissection tonsillectomy in children. *Orig. Art.* **106**: 817
Unnykrishnan P *see* Raju KGS *et al.*
Upile T *see* Axon PR *et al.*; Yates PD *et al.*
Uppal K *see* Bais AS *et al.*
Uppal KS *see* Goyal A *et al.*
Uppal PK *see* Bhargava KB *et al.*
Uppal S, Wheatley AH, Transpharyngeal approach for the treatment of dysphagia due to Forestier's disease. *Clin. Rec.* **113**: 366
Urano H *see* Nakanishi R *et al.*
Uri N *see* Cohen-Kerem R *et al.*
Urruticoechea A *see* Gòmez Estanocona N *et al.*
Urruticoechea L *see* Gòmez Estanocona N *et al.*
Uruma T *see* Shidara K *et al.*
Ushisako Y *see* Tono T *et al.*
Ustündağ E *see* Aydin Ö *et al.*
Ustünosoy E *see* Akin I *et al.*
Uttley D, Archer DJ, Giant cell tumour of the sphenoid sinus: an unusual skull base tumour. *Clin. Rec.* **105**: 855
Uwents P *see* Debruyne F *et al.*
Uzal D *see* Özyar E *et al.*

Uzun C, Taskinalp O, Koten M, Adali MK, Karasalihoglu AR, Pekindil G, Phlebectasia of the left anterior jugular vein. *Clin. Rec.* **113**: 858

Va R *see* Jalaludin MA *et al.*
Vaewvichit K, Luangpitakchumpol P, Cochlear implantation in Thailand. *Orig. Art.* **113**: 515
Vafidis J *see* Dutton JEM *et al.*
Vaida S *see* Gaitini L *et al.*
Vaida SJ *see* Gaitini LA *et al.*
Vaillant L *see* Martin L *et al.*
Valcarcel FJ *see* Regueiro CA *et al.*
Valdano J *see* Guedea F *et al.*
Valentine P *see* Salib RJ *et al.*
Vallés H *see* Adiego MI *et al.*
Valtonen H, Qvarnberg Y, Nuutinen J, Tympanostomy in young children with recurrent otitis media: A long-term follow-up study. *Orig. Art.* **113**: 207
Valtonen H *see also* Blomgren K *et al.*
Valuyeetham KA *see* Indudharan R *et al.*
van Besouw JP *see* Hinton AE *et al.*
van Cauwenberge P *see* Xu Z-M *et al.*
Van Damme B *see* Hermans R *et al.*
Van de Heyning P *see* Van Laer C *et al.*
Van de Heyning PH *see* de Varebeke SJ *et al.*; Vanden Abeele D *et al.*
Van de Ven PM, Schutte HK, The pharyngocele: infrequently encountered and easily misdiagnosed. *Clin. Rec.* **109**: 247
Van Dellen J *see* Singh B *et al.*
van den Broek P *see* Makhdoum MJA *et al.*
Van der Beek JMH *see* Meulenbroeks AAWM *et al.*
van der Coer JMG, Marres HAM, Wielinga EMJ, Wong-Alcala LSM, Rhinosporidiosis in Europe. *Clin. Rec.* **106**: 440
van der Laan BFAM, Baris G, Gregor RT, Hilgers EJM, Balm AJM, Radiation-induced tumours of the head and neck. *Onc. Focus* **109**: 346
van der Waal I *see* Önder T *et al.*; Tiwari R *et al.*
van Eeden S, Lloyd RV, Tranter RM, Comparison of the endoscopic stapling technique with more established procedures for pharyngeal pouches: results and patient satisfaction survey. *Orig. Art.* **113**: 237
van Hasselt CA, Mastoid surgery and the Hong Kong Flap **108**: 825
Van Hasselt CA, Ng HK, Papillary adenocarcinoma of the nasopharynx. *Clin. Rec.* **105**: 853
van Hasselt CA *see* Chi Fai Tong M *et al.*; Choy ATK *et al.*; Gluckman PGC *et al.*; John DG *et al.*; Ku PKM *et al.*; Pak MW *et al.*; Porter MJ *et al.*; Rushton HC *et al.*; Scott PMJ *et al.*; *see* John DG *et al.*; Sham CL *et al.*; Syed A *et al.*; Tang NLS *et al.*; Tong MCF *et al.*; Tsang RKY *et al.*; Woo JKS *et al.*
van Hasselt CA *see also* Chalstrey SE *et al.*; Porter MJ *et al.*
van Houten RJ, Premachandra DJ, Topical active H_1-antihistamines and their effect on nasal airway resistance. *Orig. Art.* **109**: 841
van Ingen G, Stel HV, Tiwari RM, Atypical leiomyoma of the choana. *Clin. Rec.* **105**: 1065
Van Laer C, Hamans E, Neetens I, Van Marck E, Van Oosterom A, Van de Heyning P, Benign fibrous histiocytoma of the larynx: presentation of a case and review of the literature. *Clin. Rec.* **110**: 474
van Leeuwen JPPM, Cremers CWRJ, Thijssen HOM, Meyer HE, Unchanged unilateral hearing loss and ipsilateral growth of an acoustic neuroma from 1 to 4 cm. *Clin. Rec.* **107**: 230
van Leeuwen JPPM, Pruszczynski M, Marres HAM, Grotenhuis JA, Cremers CWRJ, Unilateral hearing loss due to a rhabdomyoma in a six-year-old child. *Clin. Rec.* **109**: 1186
Van Marck E *see* Van Laer C *et al.*
Van Oosterom A *see* Van Laer C *et al.*
van Veen ED, Jacobs JB, Bensing JM, Assessment of distress associated with tinnitus. *Orig. Art.* **112**: 258
van Velzen D *see* Roland NJ *et al.*
Van Vooren JP, Farber CM, Daelemans P, Delforge ML, Liesnard C, Acute Sjögren-like syndrome as the first manifestation of a generalized CMV infection in a patient with AIDS. *Clin. Rec.* **109**: 1113
Vanat Z *see* Gray RF *et al.*
Vanat ZH *see* Ray J *et al.*
Vanden Abeele D, Clemens A, Tassignon MJ, Van de Heyning PH, Blindness due to electrocoagulation following functional endoscopic sinus surgery. *Clin. Rec.* **110**: 261
Vandevelde L *see* Saussez S *et al.*
Vanniasegaram I, Prospective study of the use of vasoconstrictor and saline in septal surgery for infiltration. *Orig. Art.* **105**: 638
Vanniasegaram I, Bradley J, Bellman S, Clinical applications of transcranial bone conduction attenuation in children. *Orig. Art.* **108**: 834
van't Veer JL *see* Ceha HM *et al.*
de Varebeke SJ, De Schepper A, Hauben E, Declau F, Marck EV, Van de Heyning PH, Subcutaneous diffuse neurofibroma of the neck: a case report. *Clin. Rec.* **110**: 182
Varghese G, Murthy PSN, Puranik KR, Kurien M, Ram Narayan K, Fibromatosis on the dorsum of the nose. *Clin. Rec.* **106**: 821
Varley R *see* Drake-Lee A *et al.*
Varoğlu E *see* Karaşen RM *et al.*
Vartiainen E, Changes in the clinical presentation of chronic otitis media from the 1970s to the 1990s. *Orig. Art.* **112**: 1034
Vartiainen E, Factors associated with recurrence of cholesteatoma. *Orig. Art.* **109**: 590
Vartiainen E, Karjalainen S, Congenital and early-onset bilateral hearing impairment in children: the delay in detection. *Orig. Art.* **111**: 1018
Vartiainen E, Nuutinen J, Karjalainen S, Nykäinen K, Perilymph fistula–a diagnostic dilemma. *Orig. Art.* **105**: 270
Vartiainen E, Nuutinen J, Karjalainen S, Pellinen P, Posterior crus stapedectomy. *Orig. Art.* **107**: 795
Vartiainen E, Nuutinen J, Virtaniemi J, Long-term results of revision stapes surgery. *Orig. Art.* **106**: 971
Vartiainen E, Vartiainen J, Effect of aerobic bacteriology on the clinical presentation and treatment results of chronic suppurative otitis media. *Orig. Art.* **110**: 315
Vartiainen E, Vartiainen T, Effect of drinking water fluoridation on the prevalence of otosclerosis. *Orig. Art.* **111**: 20
Vartiainen E *see* Virtaniemi J *et al.*
Vartiainen J *see* Vartiainen and Vartiainen
Vasanthan S *see* Logue JP *et al.*
Vassalli L *see* Gamoletti R *et al.*
Vassallo G *see* Chashaba A *et al.*
Vassilopoulou-Sellin R *see* El-Naggar AK *et al.*
Vats A, Worley G, Wareing MJ, A novel dressing for tracheostomy decannulation. *Short Comm.* **113**: 999
Vats A *see also* Worley GA *et al.*
Vaughan CW *see* Cullen JR *et al.*
Vaughan MM, Parker AJ, Idiopathic spontaneous tonsillar haemorrhage. *Clin. Rec.* **107**: 44
Vaughan-Jones R, Mills RP, The Welch Allyn Audioscope and Microtymp: their accuracy and that of pneumatic otoscopy, tympanometry and pure tone audiometry as predictors of otitis media with effusion. *Orig. Art.* **106**: 600
Vaughan-Jones R *see* Millar EKA *et al.*
Vaughan-Jones R *see* Tay HL *et al.*
Vaughan-Jones RH, Padgham ND, Christmas HE, Irwin J, Doig A, One aid or two? — more visits please! *Orig. Art.* **107**: 329
Vaughan-Jones RJ *see* Mills RP *et al.*
Vaughan-Jones SA *see* Wareing MJ *et al.*
Vavrina J, Müller W, Gebbers J-O, Enlargement of salivary glands in bulimia. *Clin. Rec.* **108**: 516
Vazquez-Ramirez FJ *see* Galera-Ruiz H *et al.*
Veber F *see* Koka VN *et al.*
van't Veer JL *see* Ceha HM *et al.*
Vega M *see* Guedea F *et al.*
De Vel E *see* Xu Z-M *et al.*
Velagapudi SB *see* Saleem M *et al.*
Vele DD, Sengupta SK, Dubey SP, Dokup MK, Cystic lesions of the nasal cavity and the paranasal sinuses: report of two unusual cases. *Clin. Rec.* **110**: 1157
Velegrakis G, Skoulakis C, Bizakis J, Segas J, Helidonis E, Otorhinolaryngological diseases in the Minoan era. *Hist. Art.* **107**: 879
Velegrakis GA, Prokopakis EP, Papadakis CE, Karampekios SK, Koutsoubi KG, Helidonis ES, Osteoblastoma of the nasal cavity arising from the perpendiculate of the ethmoid bone. *Clin. Rec.* **111**: 865
Velegrakis G, *see also* Nikolaou A *et al.*
Velez A *see* Ochoa LF *et al.*
Vella EJ *see* Raj P *et al.*

Venkateswaran S *see* Job A *et al.*
Venn PJH *see* Morrissey MSC *et al.*
Vericel R *see* Koka V *et al.*
Vernham GA, Sadiq H, Mallon EA, Nasal leishmaniasis. *Clin. Rec.* **107**: 834
Veronesi A *see* Barzan L *et al.*
Verse T, Pirsig W, Age-related changes in the epiglottis causing failure of nasal continuous positive airway pressure therapy. *Clin. Rec.* **113**: 1022
Viallard M *see* Dominici L *et al.*
Viani L, Jones AS, Clarke R, Nasal airflow in inspiration and expiration. *Orig. Art.* **104**: 473
Viani L, Dammeijer P, Jones AS, Dalby JE, Stell PM, Recurrence of oropharyngeal carcinoma after radiotherapy. *Orig. Art.* **105**: 24
Viani L, McCormick MS, Duro-cutaneous fistula caused by a 'congenital' cholesteatoma. *Clin. Rec.* **104**: 241
Viani L *see* Gaffney RJ *et al.*
Vice PA *see* Hariri and Vice
Victoria LV, Hoffman HT, Robinson RA, Granular cell tumour of the larynx. *Clin. Rec.* **112**: 373
Vidler M *see* Neary WJ *et al.*
Viehl P *see* Klijanienko J *et al.*
Viera D *see* Dueñas L *et al.*
Vierna J *see* Laforga and Vierna
Vijaya-Sekaran S, Delap T, Abramovich S, Solitary plasmacytoma of the skull base presenting with unilateral sensorineural hearing loss. *Clin. Rec.* **113**: 164
Vijaya-Sekaran S *see also* Harcourt JP *et al.*
Vijayakumar M *see* Shenoy AM *et al.*
Vijayaraghavan M *see* Thakar A *et al.*
Vilchez R *see* Esteban F *et al.*
Villanueva Marcos JL *see* Navarro Cunchillos M *et al.*
Villar M *see* Mesko TW *et al.*
Villarejo PL, Baños EC, Ramos J, The antrum exclusion technique in cholesteatoma surgery. *Orig. Art.* **106**: 120
Villavicendo E *see* Dueñas L *et al.*
de Villiers JC *see* Wormald PJ *et al.*
Villman K *see* Davidsson Å *et al.*
Vinayak B *see* Mckiernan DC *et al.*
Vinayak BC, Cox GJ, Ashton-Key M, Pilomatrixoma of the external auditory meatus. *Clin. Rec.* **107**: 333
Vinayak BC, *see also* Reddy KTV *et al.*
Vinayak BP, Reddy KTV, Hibernoma in the parotid region. *Path. Focus* **107**: 257
Vinck B *see* Xu Z-M *et al.*
Vingolo GM *see* Magliulo G *et al.*
Violaris N, Bridger M, Prophylactic antibiotics and post-laryngectomy pharyngocutaneous fistulae. *Orig. Art.* **104**: 225
Violaris N *see* Buckland JR *et al.*; Patel K *et al.*
Violaris NS, Pahor AL, A variation of first branchial cleft anomalies. *Clin. Rec.* **107**: 625
Violaris NS *see* Jones RL *et al.*
Virtaniemi J, Laakso M, Nuutinen J, Karjalainen S, Vartiainen E, Hearing thresholds in insulin-dependent diabetic patients. *Orig. Art.* **108**: 837
Virtaniemi J *see* Vartiainen E *et al.*
Vishwanathan KA *see* Iqbal SM *et al.*
Visishta RK *see* Narayana HM *et al.*
Vital JP *see* Escada P *et al.*
Vize CE *see* Irani BS *et al.*; Martin-Hirsch DP *et al.*
Vlahos L, Yiotakis J, Gouliamos A, Kotoulas G, Adamopoulos G, Localized mastoiditis simulating a facial nerve schwannoma in MRI. *Rad. Focus* **108**: 1008
Vlahos LL *see* Athanassopoulou AC *et al.*
Voegels RL *see* Bento RF *et al.*
Vohra SB, Mason CJ, Spontaneous rupture of tympanic membrane during anaesthesia. *Clin. Rec.* **108**: 582
Vokurka J *see* Núñez-Fernández D *et al.*
von Blumenthal H, Fisher EW, Adlam DM, Moffat DA, Surgical emphysema: a novel complication of aural exostosis surgery. *Clin. Rec.* **108**: 490
von Blumenthal H *see also* Moffat DA *et al.*; Quine SM *et al.*
von Schoenberg M, Robinson P, Ryan R, Nasal packing after routine nasal surgery — is it justified? *Orig. Art.* **107**: 902
Vontetsianos H *see* Lefantzis D *et al.*
Vora IM *see* Bhattacharyya AK *et al.*
Vos GD, Marres EH, Heineman E, Janssens M, Tension pneumoperitoneum as an early complication after adenotonsillectomy. *Clin. Rec.* **109**: 440
Vos GD *see also* Meulenbrocks AAWM *et al.*
Voss SE *see* Merchant SN *et al.*
Vowles A *see* McGlashan JA *et al.*
Vowles R, Mendoza N, Cheesman A, Symon L, An unusual complication of glomus jugulare tumour resection: a case report and literature review. *Clin. Rec.* **108**: 776
Vowles R *see* Rowe-Jones JM *et al.*
Vowles RH, Ghiacy S, Jefferis AF, A clinic for the rapid processing of patients with neck masses. *Orig. Art.* **112**: 1061
Vowles RH, Myint S, Croft CB, The incidence and detection of HPV in the upper aerodigestive tract using brush and biopsy techniques. *Orig. Art.* **111**: 215
Vowles RH, *see also* Cerovac SS *et al.*
Vreeburg GCM, Stell PM, Holding JD, Lindup WE, Cisplatin-albumin complex for treatment of cancer of the head and neck. *Clin. Rec.* **106**: 832
de Vries WAEJ *see* Balm AJM *et al.*
Vuyk HD, Cartilage sparing otoplasty: a review with long-term results. *Rev. Art.* **111**: 424
Vyse T, Luxon LM, Walport MJ, Audiovestibular manifestations of the antiphospholipid syndrome. *Clin. Rec.* **108**: 57

van der Waal I *see* Önder T *et al.*; Tiwari R *et al.*
Wackym PA, Canalis RF, Feverman T, Subdural empyema of otorhinolaryngological origin. *Orig. Art.* **104**: 118
Wade MJ *see* Hussain SSM *et al.*
Wadler S *see* Rubin JS *et al.*
Wagner M *see* Jungehülsing M *et al.*
Wakasa H *see* Murakami M *et al.*
Wake M, ENT cancer in the West Midlands region of England. *Orig. Art.* **107**: 313
Wake M, McCullough DE, Audit of blood transfusion policy in head and neck surgery. *Orig. Art.* **104**: 28
Wake M, McCullough DE, Binnington JD, Effect of nasogastric tubes on eustachian tube function. *Orig. Art.* **104**: 17
Wake M, Phelps PD, Adenoid cystic carcinoma: a comparison between CT, MR and Gd MR imaging techniques. *Rad. Focus* **104**: 662
Wake M, Robinson JM, Sheehan AL, Bazerbachi S, Codling BW, The histology of 'stored' autologous ossicles. *Orig. Art.* **106**: 17
Wake M, Robinson JM, Whitcombe JB, Bazerbachi S, Stansbie JM, Phelps PD, Detection of recurrent cholesteatoma by computerised tomography after 'closed cavity' mastoid surgery. *Orig. Art.* **106**: 393
Wake M, Takeno S, Ibrahim D, Harrison R, Mount R, Carboplatin ototoxicity: an animal model. *Orig. Art.* **107**: 585
Wake M *see* Agius AM *et al.*
Wake MJC *see* Stevenson DS *et al.*
Wakeel R *see* Clark LJ *et al.*
Wakizono S *see* Sugimoto T *et al.*
Walby AP *see* Toner and Walby
Walch C, Anderhuber W, Preidler K, Humer U, Retro- and parapharyngeal ganglioneuroma. *Clin. Rec.* **110**: 87
Walder M *see* Stjernquist-Desatnik A *et al.*
Waldron J *see* Connolly AAP *et al.*; Stafford N *et al.*
Walker D *see* Lim PVH *et al.*
Walker J *see* Pollock AM *et al.*
Walker P *see* Ajal M *et al.*
Walker T *see* Hore I *et al.*
Wallace CS, Marriage HJ, A case of attempted division of the eighth nerve within the skull for the relief of tinnitus. *Clin. Rec.* **105**: 1101, **105**: 1102
Wallace, HC *see* Pearson and Wallace
Wallace M *see* Reddy KTV *et al.*
Wallace W *see* Anstey ST *et al.*
Wallace WA *see* Sanderson RJ *et al.*
Waller A *see* Talmi YP *et al.*
Waller ML *see* Slevin NJ *et al.*
Wallis J *see* Smith I *et al.*
Walport MJ *see* Vyse T *et al.*
Walsh AR *see* Ahmed SK *et al.*
Walsh M *see* Rowley H *et al.*; Russell JD *et al.*
Walsh MA *see* Gaffney and Walsh; Lacy PD *et al.*
Walsh MY *see* McCluggage P *et al.*
Walsh N *see* O'Hanlon DM *et al.*

Walsh R *see* McGlashan JA *et al.*
Walsh RM, Kumar BN, Tse A, Jones PW, Wilson PS, Post-tonsillectomy bacteraemia in children. *Orig. Art.* **111**: 950
Walsh RM, Leen EJ, Gleeson MJ, Solitary infantile and adult myofibromatosis of the nasal cavity: a report of two cases. *Clin. Rec.* **110**: 574
Walsh RM, Leen EJ, Gleeson MJ, Shaheen OH, Malignant vagal paraganglioma. *Clin. Rec.* **111**: 83
Walsh RM, Murty GE, Bradley PJ, Bilateral internal jugular phlebectasia. *Clin. Rec.* **106**: 753
Walsh RM, Pracy JP, Harding L, Bowdler DA, Management of retraction pockets of the pars tensa in children by excision and ventilation tube insertion. *Orig. Art.* **109**: 817
Walsh RM *see* Ayshford CA *et al.*; Bath AP *et al.*; Hollis LJ *et al.*; Kumar BN *et al.*; Lall GS *et al.*; Lee and Walsh; Lee WC *et al.*; Pracy JPM *et al.*
Walsh RM, *see also* Ingrams and Walsh; Kumar BN *et al.*
Walsh-Waring G *see* Stafford N *et al.*
Walsh-Waring GP *see* Thomas DM *et al.*; Whitworth IH *et al.*
Walsted A, Nielsen OA, Borum P, Salomon G, Hearing loss after neurosurgery. The influence of low cerebrospinal fluid pressure. *Orig. Art.* **108**: 637
Walter C *see* O'Reilly and Walter
Walter N *see* Job A *et al.*
Walter NM *see* Kumar BN *et al.*
Wan SK, Chan JKC, Tse KC, Basaloid-squamous carcinoma of the nasal cavity. *Clin. Rec.* **106**: 370
Wanamaker HH *see* Kitamura K *et al.*
Wang C-P, Tseng T-C, Lee R-C, Chang S-Y, The techniques of nonmuscular closure of hypopharyngeal defect following total laryngectomy: the assessment of complication and pharyngoesophageal segment. *Orig. Art.* **111**: 1060
Wang D-H, Guan X-L, Xiao L-F, Zhang X-P, Chen M-G, Sun K-M, Soft tissue chondroma of the parapharyngeal space: a case report. *Clin. Rec.* **112**: 294
Wang Q, Takashima S, Takayama F, Kobayashi S, Sone S, Power doppler imaging findings of multilocular giant parathyroid adenoma which caused hypercalcaemic crisis. *Rad. Focus* **112**: 796
Wang S-G *see* Roh H-J *et al.*
Wang Xiu-yun *see* Zhu Li-xiang and Wang Xiu-yun
Wang Z, Dilation of simultaneous laryngeal and oesophageal stricture with two T-tubes. *Short Comm.* **108**: 42
Wansa SA, Jones NS, Watkinson J, Unusual laryngeal cyst. *Clin. Rec.* **104**: 145
Ward K *see* Thomas MR *et al.*
Ward V *see* Read-Jones M *et al.*
Wardrop PJC *see* Laing RBS *et al.*
Wardrop W *see* Warrick PD *et al.*
Wareing M, Mitchell D, Drug-induced otalgia due to mesalazine and sulphasalazine. *Clin. Rec.* **110**: 466
Wareing M, Mitchell D, Laser assisted uvulopalatoplasty: an assessment of a technique. *Orig. Art.* **110**: 232
Wareing MJ, Callanan VP, Mitchell DB, Laser assisted uvulopalatoplasty: six and eighteen month results. *Orig. Art.* **112**: 639
Wareing MJ, Fisher EW, Manning RH, Gray RE, Lamb WT, The extraction and re-implantation of teeth for the difficult laryngoscopy. *Short Comm.* **108**: 44
Wareing MJ, Gray RF, Foley catheter fixation in position epistaxis. *Short Comm.* **107**: 1032
Wareing MJ, Irving RM, Moffat DA, Parapharyngeal space tumour presenting as recurrent uvular oedema. *Clin. Rec.* **107**: 640
Wareing MJ, Vaughan-Jones SA, McGibbon DH, Acrokeratosis paraneoplastica: Bazex syndrome. *Clin. Rec.* **110**: 899
Wareing MJ *see* Vats A *et al.*; Worley GA *et al.*
Warfield AT *see* Johnson IJM *et al.*; Kuo MJ *et al.*
Warrick PD, Wardrop W, Sim DW, Sensorineural hearing loss in MELAS syndrome. *Clin. Rec.* **111**: 279
Warwick-Brown N *see* Benson-Mitchell R *et al.*
Wassef M *see* Marianowski R *et al.*
Watanabe K, Kikuchi T, Katori Y, Fujiwara H, Sugita R, Takasaka T, Hashimoto S, The usefulness of computed tomography in the diagnosis of impacted fish bones in the oesophagus. *Orig. Art.* **112**: 360
Watanabe Y, Ikeda M, Kukimoto N, Kuga M, Tomita H, A case report of facial nerve palsy associated with chickenpox. *Clin. Rec.* **108**: 676
Watanabe Y *see* Nakagawa H *et al.*
Watkin P *see* Baldwin and Watkin
Watkinson A *see* Baer and Watkinson
Watkinson J *see* Wansa SA *et al.*
Watkinson JC, Todd CEC, Lazarus CR, Maisey MN, Clarke SEM, Technetium-99m(v) Dimercaptosuccinic acid planar scintigraphy in head and neck cancer: clinical, scintigraphic and radiological study. *Orig. Art.* **104**: 783
Watkinson JC *see* Ayshford CA *et al.*; Davis JP *et al.*; Hilger AW *et al.*; Hogg RP *et al.*; Johnson IJM *et al.*
Watkinson JC, *see also* Rockall TA *et al.*
Watson C, Necrosis of the incus by the chorda tympani nerve. *Clin. Rec.* **106**: 252
Watson C, Oncocytic metaplasia of the nasopharynx – unusual cause of secretory otitis media. *Clin. Rec.* **104**: 39
Watson C, Crowther JA, Stephen MR, Osteochondroma of the tongue. *Clin. Rec.* **104**: 138
Watson DJ, Parker AJ, MacLeod TIF, Lymphogranuloma venereum of the tonsil. *Clin. Rec.* **104**: 331
Watson HG *see* Denholm SW *et al.*
Watson MG, Marshall HF, Intranasal adhesions which recur despite splinting: an ominous sign? (Wegener's granulomatosis). *Clin. Rec.* **104**: 426
Watson MG, Birchall JP, Soames JV, Is 'lateral aberrant thyroid' always metastatic tumour? *Clin. Rec.* **106**: 376
Watson MG, Dawes PJD, Samuel PR, Marshall HF, Rayappa C, Hill J, Meikie D, Murty GE, Deans JAJ, Telios G, Aldren C, Birchall JP, Pritchard AJN, Livesey J, Appleton D, A study of haemostasis following tonsillectomy comparing ligatures with diathermy. *Orig. Art.* **107**: 711
Watson MG, Robertson AS, Colquhoun LR, Pseudoaneurysm of the internal carotid artery: A forgotten complication of tonsillitis? *Clin. Rec.* **105**: 588
Watson MG *see* Carrie S *et al.*
Watson MG, *see also* Crocker and Watson; Kent and Watson; Murty and Watson
Watters GWR, Milford CA, Isolated sphenoid sinusitis due to *Pseudallescheria boydii*. *Clin. Rec.* **107**: 344
Watters GWR, Molyneux AJ, Atypical carcinoid tumour of the larynx. *Path. Focus* **109**: 455
Watters GWR *see* Law and Watters; McDermott and Watters; Norman L *et al.*
Watters GWR *see also* McKiernan and Watters
Watts SJ, Turner NO, San-Juan J, Rockley TJ, Facial paralysis caused by a lymphoepithelial cyst located in the parotid gland. *Clin. Rec.* **110**: 799
Wayman DM, Pham HN, Byl FM, Adour KK, Audiological manifestations of Ramsay Hunt syndrome. *Orig. Art.* **104**: 104
Weber B *see* Graham J *et al.*
Weber R, Keerl R, Jaspersen D, Huppmann A, Schick B, Draf W, Computer-assisted documentation and analysis of wound healing of the nasal and oesophageal mucosa. *Orig. Art.* **110**: 1017
Weber R *see* Carrillo R *et al.*; Keerl R *et al.*
Webster G *see* Stevenson DS *et al.*
Wedzicha JA *see* Kalan A *et al.*
Wei J *see* Graham J *et al.*
Wei WI *see* Lau SK *et al.*; Yuen APW *et al.*
Wei WL *see* Lau SK *et al.*
Weighill J *see* Harkness P *et al.*
Weinberg RA *see* Chen KTK *et al.*
Weinel P *see* Maier W *et al.*
Weiner GM, Batch AJG, Endobronchial tuberculosis masquerading as foreign body aspiration. *Clin. Rec.* **109**: 1192
Weiner GM, Batch AJG, Radford K, Dysphonia as an atypical presentation of gastro-oesophageal reflux. *Clin. Rec.* **109**: 1195
Weiner GM, O'Connell JE, Pahor AL, The role of surgery in tuberculous mastoiditis: appropriate chemotherapy is not always enough. *Clin. Rec.* **111**: 752
Weiner GM, Pahor AL, Deep lobe parotid lipoma: a case report. *Clin. Rec.* **109**: 772
Weiner GM, Pahor AL, Tuberculous nasopharyngeal cyst: diagnostic aspiration using the nasendoscope. *Clin. Rec.* **108**: 505
Weiner GM, Pahor AL, Tuberculous parotitis: limiting the role of surgery. *Clin. Rec.* **110**: 96

Weiner GM, Williams B, Prevention of intracranial problems in ear and sinus surgery: a possible role for Cefotaxime. *Orig. Art.* **107**: 1005
Weiner GM *see* Lee WC *et al.*
Weinstein G *see* Crevier-Buchman L *et al.*; Laccourreye O *et al.*
Weir J, Kramer v Wilde: an ideological debate. *Orig. Art.* **104**: 381
Weir J *see* Williamson PA *et al.*
Weir JN *see* Badia L *et al.*
Weir N, Adam Politzer's influence on the development of international otology. *Hist. Art.* **110**: 823
Weir N, Ear surgery camps in Nepal and the work of the Britain Nepal Otology Service (BRINOS). *Clin. Rec.* **105**: 1113
Weir N, The future of ORL-HNS and associated specialities series. Highlights of the development of ENT in the 20th century **113**: 1060
Weir N *see* Little P *et al.*
Weir N, *see also* Daya H *et al.*
Welch AR, Birchall JP, Stafford FW, Occupational rhinitis — possible mechanisms of pathogenesis. *Orig. Art.* **109**: 104
Welch AR *see* Deans JAJ *et al.*; Murty GE *et al.*
Welinder NR *see* Sorribes MM *et al.*
Wells A *see* Drake-Lee A *et al.*
Wells M *see* Nunez DA *et al.*
Wells MD, Michaels L, Mode of growth of acquired cholesteatoma. *Orig. Art.* **105**: 261
Wells SC *see* Ravi and Wells
Welsby PD *see* Laing RBS *et al.*
Welsh A *see* El-Naggar M *et al.*; Rashad U *et al.*
Welsh J, Westra WH, Eisele D, Hogan R, Lee D-J, Solitary plasmacytoma of the epiglottis: a case report and review of the literature. *Clin. Rec.* **112**: 174
Welsh MJ *see* Graham SM *et al.*
Wen QH, Nishimura T, Miwa T, Nagayama I, Furukawa M, Expression of EGF, EGFR, and PCNA in laryneal lesions. *Orig. Art.* **109**: 630
Wendall Todd N, Alvarado CS, Brewer DB, Cisplatin in children: hearing loss correlates with iris and skin pigmentation. *Orig. Art.* **109**: 926
Wengraf C *see* Salam and Wengraf; Strachan D *et al.*
Wenig BM, Lipomas of the larynx and hypopharynx: a review of the literature with the addition of three new cases. *Path. Focus* **109**: 353
Wenig BM *see* Aguilera NSI *et al.*
Wenxuan C *see* Zhi W *et al.*
Wenzhong L *see* Zhi W *et al.*
Werner JA *see* Brademann G *et al.*; Mahnke CG *et al.*
Wersäll J *see* Yamashita H *et al.*
Westerman ST *see* Catalfumo FJ *et al.*
Westman G *see* Davidsson Å *et al.*
Westmore GA, Cervical abscess: a life-threatening complication of infectious mononucleosis. *Clin. Rec.* **104**: 358
Westmore GA, Staple gun in the surgery of hypopharyngeal diverticula. *Orig. Art.* **104**: 553
Westmore GA, *see also* Plent S *et al.*
Westra WH *see* Welsh J *et al.*
Weyl-Ben-Arush M *see* Danino J *et al.*
Whallett EJ, Pahor AL, Herpes and the head and neck: the difficulties of diagnosis. *Clin. Rec.* **113**: 573
Wharton SB *see* Lau DPC *et al.*
Wharton SM, Davis A, Familial paraganglioma. *Clin. Rec.* **110**: 688
Wheatley AH, Temple RH, Camilleri AE, Childhood obstructive sleep apnoea syndrome due to nasopharyngeal viral papillomatosis. *Clin. Rec.* **111**: 976
Wheatley AH, Temple RH, Camilleri AE, Jones PH, ENT open access clinic: an audit of a new service. *Aud. Art.* **113**: 657
Wheatley AH *see* Uppal and Wheatley
Whinney DJ, Williamson PA, Bicknell PG, Punctate diathermy of the soft palate: a new approach in the surgical management of snoring. *Orig. Art.* **109**: 849
Whitby D *see* Ramamurthy L *et al.*
Whitcombe JB *see* Wake M *et al.*
White A, Sim DW, Maran AGD, Reinke's oedema and thyroid function. *Orig. Art.* **105**: 291
White P *see* Connolly AAP *et al.*
White PS, Endoscopic ligation of the sphenopalatine artery (ELSA): a preliminary description. *Orig. Art.* **110**: 27
White PS, Cowan IA, Robertson MS, Limited CT scanning techniques of the paranasal sinuses. *Orig. Art.* **105**: 20
White PS, Maclennan AC, Connolly AAP, Crowther J, Analysis of CT scanning referrals for chronic rhinosinusitis. *Orig. Art.* **110**: 641
White PS *see* Baird AR *et al.*; Gardiner Q *et al.*; Holland S *et al.*; Houghton and White; Ram B *et al.*; Summerfield and White
White SA, Goddard MJ, Metastatic Hurthle cell tumour causing central airway obstruction. *Clin. Rec.* **107**: 957
White SA, Narula AA, A complication of indoor pistol shooting. *Clin. Rec.* **110**: 663
White-Thompson M *see* Callanan V *et al.*
Whitehead BF *see* Umapathy N *et al.*
Whitehead E, Experience with a subcutaneous implantable bone conduction hearing aid (Xomed Audiant) in a district general hospital. *Orig. Art.* **105**: 828
Whitehead E, Salam MA, Use of the carbon dioxide laser with the Montgomery T-tube in the management of extensive subglottic stenosis. *Clin. Rec.* **106**: 829
Whitehead E *see* Salam and Whitehead
Whiteside JC *see* Wyatt ME *et al.*
Whittam DE, Hellier W, Haemangiopericytoma of the parotid salivary gland. *Clin. Rec.* **107**: 1159
Whittet H *see* Morrissey MSC *et al.*
Whittet HB, Lund VJ, Brockbank M, Feyerabend C, Serum cotinine as an objective marker for smoking habit in head and neck malignancy. *Orig. Art.* **105**: 1036
Whittet HB *see* Andaz C *et al.*; Koay CB *et al.*; Raine NMN *et al.*; Robson AK *et al.*
Whittet HB, *see also* Leighton SEJ *et al.*
Whittet HW, Barker S, Anslow P, Leighton S, Heterotopic brain tissue: A rare cause of adult recurrent meningitis. *Clin. Rec.* **104**: 328
Whitworth IH, Suvarna SK, Wight RG, Walsh-Waring GP, Fourth branchial arch anomaly: a rare incidental finding in an adult. *Clin. Rec.* **107**: 238
Wickham MH *see* Parker AJ *et al.*
Wickstead M *see* Kedjanyi WK *et al.*
Widgren S *see* Zbaeren P *et al.*
Wielinga EMJ *see* van der Coer JMG *et al.*
Wielinga EWJ, Smyth GDL, Comparison of the Goode T-Tube with the Armstrong tube in children with chronic otitis media with effusion. *Orig. Art.* **104**: 608
Wiernik G *see* Alcock GJ *et al.*
Wiesel JM *see* Ostfeld EJ *et al.*
Wiet RJ, Bauer GP, Stewart D, Zappia JJ, Intraoperative facial nerve monitoring — a description of a unique system. *Orig. Art.* **108**: 551
Wight RG *see* Collins and Wight; Kale US *et al.*; Parker AJ *et al.*; Whitworth IH *et al.*
Wightman AJA *see* Marais J *et al.*
Wijburg FA *see* Berkovits RNP *et al.*
Wild D *see* Mayall and Wild
Wilde A *see* Smith and Wilde
Wilde AD, England J, Jones AS, An alternative to regular dressings for otitis externa and chronic supperative otitis media? *Orig. Art.* **109**: 101
Wilde JT *see* Raj P *et al.*
Wilkins MJ *see* Thomas DM *et al.*; Toynton SC *et al.*
Wilkins RH *see* McElvenn JT Jr *et al.*
Wilkinson SM, Beck MH, Hypersensitivity to topical corticosteroids in otitis externa. *Orig. Art.* **107**: 597
Willatt DJ *see* Hartley and Willatt; Mirza S *et al.*; Pang and Willatt
Williams A *see* Dhaliwal J *et al.*
Williams B *see* Weiner and Williams
Williams ED *see* Hill J *et al.*
Williams HOL, Fisher EW, Golding-Wood DG, 'Two-stage turbinectomy': Sequestration of the inferior turbinate following submucosal diathermy. *Orig. Art.* **105**: 14
Williams HOL *see* Chalstrey SE *et al.*; Pracy JPM *et al.*
Williams HOL, *see also* Golding-Wood DG *et al.*; Tolley NS *et al.*
Williams PE *see* Snow DG *et al.*
Williams RG, Douglas-Jones T, Mycobacterium marches back. *Rev. Art.* **109**: 5
Williams SB, Ellis GL, Meis JM, Heffner DK, Ossifying fibromyxoid tumour (of soft parts) of the head and neck: a clinicopathological and immunohistochemical study of nine cases. *Path. Focus* **107**: 75

Williams Z, Norbash A, Goode RL, Cavernous sinus syndrome caused by a primary paranasal sinus non-Hodgkin's lymphoma. *Clin. Rec.* **112**: 777
Williamson IG, Dunleavy J, Bain J, Robinson D, The natural history of otitis media with effusion – a 3 year study of the incidence and prevalence of abnormal typanograms in four South West Hampshire Infant and First schools. *Orig. Art.* **108**: 930
Williamson JMS *see* Armour and Williamson; Coup A *et al.*
Williamson P *see* Abdullah V *et al.*; McCombe A *et al.*
Williamson PA, Weir J, Baldwin DL, Supraglottic transection: results of repair and functional outcome. *Clin. Rec.* **109**: 340
Williamson PA *see also* Whinney DJ *et al.*
Williamson TJ *see* Richardson MP *et al.*
Willis G *see* Morgan DW *et al.*
Willson PD *see* Montgomery P *et al.*
Willumsen L *see* Katholm M *et al.*
Wilsher TK *see* Coakley *et al.*
Wilson F *see* Anwar R *et al.*
Wilson GE *see* Simo R *et al.*
Wilson JA *see* Hajioff D *et al.*; Morgan M *et al.*; Scott RF *et al.*; Siodlak MA *et al.*
Wilson PS, Distribution of ear drops in normal ears. *Short Comm.* **105**: 359
Wilson PS, Mucosal thickening on sinus x-rays and its significance. *Orig. Art.* **104**: 694
Wilson PS, Dingle A, Grocutt M, Reid AP, Distribution of ear drops using a non-aerosol delivery system. *Short Comm.* **105**: 651
Wilson PS, Hoare TJ, Johnson AP, Milk nasendoscopy in the assessment of dysphagia. *Orig. Art.* **106**: 525
Wilson PS, Snow DG, O'Connel J, Proops DW, Barrow M, Role of routine fluid replacement in children undergoing tonsillectomy. *Short Comm.* **104**: 801
Wilson PS *see* Kumar BN *et al.*; Walsh RM *et al.*
Win MN *see* Indudharan R *et al.*
Wing Yuen P *see* Ming Li X *et al.*
Wishahi HF *see* Amar MS *et al.*
Witana JS, An *ad hoc* tympanocentesis apparatus. *Short Comm.* **106**: 425
Witana JS *see* Thomas DM *et al.*
Wittig FJ, Hickey SA, Kumar M, Double epiglottis in Weyer's acrofacial dysostosis. *Clin. Rec.* **112**: 976
Wolansky LJ, Chiang PK, Zurlo J, Baredes S, Baker SR, Encephalocoele as a complication of intranasal sinus surgery: optimal evaluation with magnetic resonance imaging. *Rad. Focus* **112**: 790
Wolfe GT *see* Talmi YP *et al.*
Wolfensberger M *see* Dort JC *et al.*
Wolford RD *see* McElvenn JT Jr *et al.*
Won Y-S *see* Cho J-H *et al.*
Wong G, Stidley C, Dressler L, Castillo M, Crooks L, Bartow S, Predictive value of flow cytometric analysis in DNA contents in patients with locally advanced head and neck carcinoma. *Orig. Art.* **110**: 243
Wong JCH *see* Ali Raza S *et al.*
Wong-Alcala LSM *see* van der Coer JMG *et al.*
Woo JKS, van Hasselt CA, Gluckman PGC, Myringitis bullosa haemorrhagica: clinical course influenced by tympanosclerosis. *Clin. Rec.* **106**: 162
Woo JKS *see* Pak MW *et al.*; Sham CL *et al.*; Tong MCF *et al.*; Tsang RKY *et al.*
Wood BP *see* Bent and Wood
Wood G *see* Akhtar S *et al.*
Wood S *see* Bottrill ID *et al.*
Woodhead CJ *see* Kaddour and Woodhead; Martin-Hirsch DP *et al.*
Woodroof JM *see* Edmonds JL *et al.*
Woodward B *see* Premachandra DJ *et al.*
Woodward BM *see* Milton CM *et al.*
Wooh K *see* Lanza J *et al.*
Woolford TJ, Birzgalis AR, Lundell C, Farrington WT, Vomiting in pregnancy resulting in oesophageal perforation in a 15-year-old. *Clin. Rec.* **107**: 1059
Woolford TJ, Birzgalis AR, Ramsden RT, An extensive vestibular schwannoma with both intracranial spread and lateral extension to the external auditory canal. *Clin. Rec.* **108**: 149
Woolford TJ *see* de Carpentier JP *et al.*; Mawman DJ *et al.*; Saeed SR *et al.*
Worley G *see* Vats A *et al.*
Worley GA, Hern JD, O'Sullivan GJ, Tassone P, Hinton AE, Mycotic aneurysm of the external carotid artery. *Rad. Focus* **112**: 793
Worley GA, Vats A, Harcourt J, Albert DM, Bilateral congenital cholesteatoma in branchio-oto-renal syndrome. *Clin. Rec.* **113**: 841
Worley GA, Wareing MJ, Sergeant RJ, Myxoid chondrosarcoma of the external auditory meatus. *Clin. Rec.* **113**: 742
Worley GA *see also* Ray J *et al.*
Wormald PJ, Pre-operative information in mastoidectomy: what about the facial nerve and hearing loss. *Rev. Art.* **110**: 10
Wormald PJ, Surgical management of benign necrotizing otitis externa. *Orig. Art.* **108**: 101
Wormald PJ, Alun-Jones T, Anatomy of the temporalis fascia. *Orig. Art.* **105**: 522
Wormald PJ, McDonogh M, "Bath-plug" technique for the endoscopic management of cerebrospinal fluid leaks. *Orig. Art.* **111**: 1042
Wormald PJ, McDonogh M, The 'swing-door' technique for uncinectomy in endoscopic sinus surgery. *Orig. Art.* **112**: 547
Wormald PJ, Prescott CAJ, Adenoids: comparison of radiological assessment methods with clinical and endoscopic findings. *Orig. Art.* **106**: 342
Wormald PJ, Sellars SL, Bismuth subgallate: a safe means to a faster adenotonsillectomy. *Orig. Art.* **108**: 761
Wormald PJ, Sellars SL, de Villiers JC, Bilateral facial nerve palsies. *Orig. Art.* **105**: 625
Wormald PJ *see* Nilssen E *et al.*; Nilssen and Wormald
Wormald PJ, *see also* Mortimore S *et al.*; Mortimore and Wormald; Nilssen and Wormald; Rushton HC *et al.*; Schiller and Wormald
Worrollo SJ *see* Stevenson DS *et al.*
Wouters J *see* Debruyne F *et al.*
Wright A *see* Friedmann I *et al.*
Wu C-M, Hwang C-F, Lin C-H, Su C-Y, External ear canal schwannoma: an unusual case report. *Clin. Rec.* **107**: 829
Wu C-M *see* Hwang C-F *et al.*
Wu C-Y *see* Jiang R-S *et al.*
Wu M-R, Shih C-T, Yeh C-W, Transorbital penetrating injury of the paranasal sinuses. *Rad. Focus* **112**: 1202
Wu W *see* Huang H *et al.*
Wu Y *see* Guo Y *et al.*
Wunderlich JL *see* Hickey SA *et al.*
Wyatt M *see* Reece PH *et al.*; Thirlwall AS *et al.*
Wyatt ME, Bailey CM, Whiteside JC, Update on paediatric tracheostomy tubes. *Orig. Art.* **113**: 35
Wyatt ME, Finlayson CJ, Moore-Gillon V, Kaposi's sarcoma masquerading as pyogenic granuloma of the nasal mucosa. *Clin. Rec.* **112**: 280
Wyatt ME *see* Hinton AE *et al.*
Wyatt ME *see also* Hicklin L *et al.*
Wyatt RA *see* Ramamurthy L *et al.*
Wylie I *see* O'Reilly BJ *et al.*

Xavier R, Paiva A, Ribeiro da Silva P, Gameiro dos Santos A, Primary malignant melanoma of the palatine tonsil: a case report. *Clin. Rec.* **110**: 163
Xenellis J, Bibas A, Savy L, Maragoudakis P, Nomicos P, Monostotic fibrous dysplasia of the temporal bone. *Rad. Focus* **113**: 772
Xhang X *see* Cai Z *et al.*
Xiao L-F *see* Wang D-H *et al.*
Xiao S *see* Huang H *et al.*
Xiuyun W *see* Liziang and Xiuyun
Xu L *see* Liu X *et al.*
Xu Y *see* Liu X *et al.*
Xu Z-M, Vinck B, De Vel E, van Cauwenberge, P, Mechanisms in noise-induced permanent hearing loss: an evoked otoacoustic emission and auditory brainstem response study. *Orig. Art.* **112**: 1154

Yacoub MH *see* Fairley JW *et al.*
Yadav SPS *see* Garg LN *et al.*

Yaddanapudi S, Shah SC, Bilateral phrenic nerve injury after neck dissection: an uncommon cause of respiratory failure. *Clin. Rec.* **110**: 281
Yagoda MR, Selesnick SH, Temporal bone fibrous dysplasia and cholesteatoma leading to the development of a parapharyngeal abscess. *Clin. Rec.* **108**: 51
Yakumaru K *see* Kaga K *et al.*
Yamada I *see* Noguchi Y *et al.*
Yamada M, Tsunoda A, Muraoka H, Komatsuzaki A, Three-dimensional reconstruction of the incudostapedial joint with helical CT. *Orig. Art.* **113**: 707
Yamada M *see* Tsunoda A *et al.*
Yamada Y *see* Hara A *et al.*
Yamaguchi K *see* Kitahara S *et al.*
Yamamoto Y, Saka T, Makimoto K, Takahashi H, Histological changes during progression of adenoid cystic carcinoma. *Path. Focus* **106**: 1016
Yamamoto Y *see* Sakakura A et.
Yamamura Y *see* Yoshihara and Yamamura
Yamashita H, Bagger-Sjöbäck D, Sekitani T, Expression of carbonic anhydrase isoenzymes in the developing endolymphatic sac of the human fetus and the mouse embryo. *Orig. Art.* **106**: 98
Yamashita H, Bagger-Sjöbäck D, Wersäll J, Sekitani T, Glycoconjugates in the human fetal endolymphatic sac as detected by lectins. *Orig. Art.* **105**: 711
Yamashita H, Noguchi T, Takahashi M, Recurrent cervical abscess due to pyriform sinus fistula. *Clin. Rec.* **109**: 886
Yanagihara N *see* Yumoto E *et al.*
Yanagita N *see* Sone M *et al.*; Ueda H *et al.*
Yang S *see* Li G-D *et al.*
Yang Z *see* Cai Z *et al.*
Yaniv E *see* Hader T *et al.*
Yanovski B *see* Gaitini LA *et al.*
Yardeni E *see* Percodani J *et al.*
Yardley MP *see* Panarese A *et al.*
Yardley MPJ, Tonsillectomy, adenoidectomy and adenotonsillectomy: are they safe day case procedures? *Rev. Art.* **106**: 299
Yardley MPJ *see* Shone and Yardley
Yardley MPJ, *see also* Nicol JW *et al.*
Yasumoto K, Miyagi C, Nakashima T, Baba H, Katsuta Y, Papillary and follicular thyroid carcinoma: the treatment results of 357 patients at the National Kyushu Cancer Centre of Japan. *Orig. Art.* **110**: 657
Yasumoto K *see* Nakanishi R *et al.*
Yasumura S *see* Ohashi N *et al.*
Yasuoka Y *see* Shidara K *et al.*
Yates PD, Upile T, Axon PR, de Carpentier J, *Aspergillus* mastoiditis in a patient with acquired immunodeficiency syndrome. *Clin. Rec.* **111**: 560
Yatigammana N *see* Murthy P *et al.*
Yazuyama Y *see* Hashiguchi K *et al.*
Ye Q *see* Li D-J *et al.*
Yebra Pimental M, Lopez Amado M, Garcia Sarandeses A, Recurrent sialadenoma papilliferum of the buccal mucosa. *Path. Focus* **109**: 787
Yee LD *see* Mesko TW *et al.*
Yeh C-W *see* Wu M-R *et al.*
Yehia MM, Al-Habib HM, Shehab NM, Otomycosis: A common problem in North Iraq. *Orig. Art.* **104**: 387
Yellin A *see* Kessler A *et al.*
Yen PT, Lee HY, Tsai MH, Chan ST, Huang TS, Clinical analysis of external laryngeal trauma. *Orig. Art.* **108**: 221
Yiğitbaşi OG *see* Güney E *et al.*
Yildirim M *see* Karaşen RM *et al.*
Yildiz FR *see* Günhan O *et al.*
Yildiz K, Köksal H, Özoran Y, Muhtar H, Telatar M, Papillary carcinoma in a thyroglossal duct remnant with normal thyroid gland. *Path. Focus* **107**: 1174
Yilmaz AB *see* Altas E *et al.*
Yilmaz O *see* Akiner MN *et al.*
Yilmaz T *see* Önerci M *et al.*
Yin SS *see* Qiu WW *et al.*
Ying M *see* Ahuja A *et al.*
Yiotakis J, Tzounakos P, Manolopoulos L, Tzagaroulakis A, Adamopoulos G, Actinomycosis of the thyroid gland masquerading as a neoplasm. *Clin. Rec.* **111**: 172
Yiotakis J *see* Lascaratos J *et al.*; Manolopoulos L *et al.*; Vlahos L *et al.*
Yiotakis JE *see* Kandiloros DC *et al.*
Ylikoski J, Pathological features of the facial nerve in patients with facial palsy of varying aetiology. Light and electronic microscopic study. *Orig. Art.* **104**: 294
Yocum P *see* Brook and Yocum
Yoon H-R *see* Cho J-H *et al.*
Yoon J-H *see* Kim K-S *et al.*
Yoon SM *see* McQueen CT *et al.*
Yoon TH *see* de Souza C *et al.*
Yorizane S *see* Lai M-T *et al.*
Yoshida S *see* Fuse T *et al.*
Yoshida Y *see* Shimazaki T *et al.*; Tanaka Y *et al.*
Yoshihara T, Tanaka M, Itoh M, Ishii T, Carcinoma ex pleomorphic adenoma of the soft palate. *Clin. Rec.* **109**: 240
Yoshihara T, Yamamura Y, An unusual case of laryngeal carcinoma metastasizing to the small intestine. *Clin. Rec.* **111**: 575
Yoshizaki T, Horikawa T, Nonomura A, Furukawa M, Leiomyosarcoma of the larynx. *Clin. Rec.* **113**: 167
Yoshizaki T *see* Takimoto T *et al.*
Yoskovitch A, Hier MP, Bégin LR, Nachtigal D, Black MJ, Fibromatosis. *Path. Focus* **113**: 486
Yotakis I *see* Adamopoulos G *et al.*
Young Y-H, Lou P-J, Post-irradiation sudden deafness. *Orig. Art.* **113**: 815
Youngs R, Epithelial migration in open mastoidectomy cavities. *Orig. Art.* **109**: 286
Youngs R, Human immunodeficiency virus in otolaryngology. *Edit. Rev.* **111**: 209
Youngs R, Temporal bone histopathology of open mastoidectomy cavities. *Path. Focus* **107**: 569
Yousef M *see* Senthikumaran G *et al.*
Yousif H *see* Pamaraju N *et al.*
Yu G *see* Cai Z *et al.*
Yu HC *see* Tsang WYW *et al.*
Yu L *see* Huang H *et al.*
Yucel E *see* Temple RH *et al.*
Yue V *see* Rushton HC *et al.*; Scott PMJ *et al.*
Yue WL, Ma ZZ, Sun ZH, Diagnostic importance of the nucleolar organizer regions in Wegener's granulomatosis. *Orig. Art.* **111**: 825
Yuen APW, Ho CM, Wei WI, Lam LK, Analysis of recurrence after surgical treatment of advanced laryngeal carcinoma. *Orig. Art.* **109**: 1063
Yuen K *see* Lai M-T *et al.*
Yumoto E, Nakamura K, Mori T, Yanagihara N, Pharapharyngeal vagal neurilemmoma extending to the jugular foramen. *Clin. Rec.* **110**: 485
Yung MW, The use of rigid endoscopes in cholesteatoma surgery. *Orig. Art.* **108**: 307
Yung MW *see* Siddiqui and Yung

Zabner J *see* Graham SM *et al.*
Zachariah A *see* Kurien M *et al.*
Zafer Uğuz M *see* Öncel S *et al.*
Zagonel V *see* Barzan L *et al.*
Zahavi Y *see* Finkelstein Y *et al.*
Zaher S *see* Abu Shara KA *et al.*; Daghistani KJ *et al.*
Zahir ZM *see* Gendeh BS *et al.*
Zaidi S *see* Shadaba and Zaidi
Zainol H *see* Sharma HS *et al.*
Zakhary MM *see* Amar MS *et al.*
Zakzouk S *see* Asiri S *et al.*
Zakzouk SM, Sobki SH, Mansour F, Al Anazy FH, Hearing impairment in association with distal renal tubular acidosis among Saudi children. *Orig. Art.* **109**: 930
Zakzouk SM *see* Al-Anazy and Zakzouk; Ali Bafaqeeh S *et al.*
Zalesska-Kręcicka M *see* Kręcicki T *et al.*
Zaman A *see* Owa AO *et al.*
Zammit-Maempel I *see* Goldsmith P *et al.*
Zanaret M *see* Dessi P *et al.*; Moulin G *et al.*
Zanelli G *see* Barzan L *et al.*
Zanetti G *see* Tesei F *et al.*
Zapater E *see* Basterra J *et al.*
Zappia JJ *see* Wiet RJ *et al.*
Zardo F *see* Magliulo and Zardo
Žargi M *see* Šmid L *et al.*
Zarod AP *see* de Carpentier JP *et al.*

Zbaeren P, Lehmann W, Widgren S, Acinic cell carcinoma of minor salivary gland origin. *Clin. Rec.* **105**: 782
Zbären P, Läng H, Beer K, Beeker M, Plasma cell granuloma of the supraglottic larynx. *Path. Focus* **109**: 895
Zeitoun H, El-Husseiny W, El-Sawi M, Mandour MA, Bronchoalveolar lavage in chronic upper respiratory tract infections. *Orig. Art.* **109**: 859
Zeitoun H, Robinson P, A potential hazard for night denture wearers. *Clin. Rec.* **108**: 350
Zeitoun H, Robinson P, Incidence of previously undetected disease in routine paediatric otolaryngology admissions. *Aud. Art.* **110**: 557
Zeitoun H, Sandhu GS, Kuo M, Macnamara M, A randomized prospective trial to compare four different ear packs following permeatal middle ear surgery. *Orig. Art.* **112**: 140
Zeman AZJ *see* Porter MJ *et al.*
Zhang R *see* Huang H *et al.*
Zhang S *see* Liu X *et al.*
Zhang X-P *see* Wang D-H *et al.*
Zhanling T *see* Lixiang Z *et al.*
Zhi W, Rucheng C, Wenxuan C, Wenzhong L, Mucosal wound and cicatricial stricture formation in the dog trachea: an experimental study. *Orig. Art.* **105**: 207
Zhou JH *see* Huang H *et al.*
Zhou L-X *see* Nishimura G *et al.*
Zhou S *see* Huang H *et al.*
Zhou SM *see* Huang H *et al.*
Zhu Li-xiang, Wang Xiu-yun, New technique for treating pseudocyst of the auricle. *Short Comm.* **104**: 31
Zidar N, Ferluga D, Hvala A, Popović M, Šoba E, Contribution to the pathogenesis of radiation-induced injury to large arteries. *Path. Focus* **111**: 988
Zidar N, Gale N, Cör A, Kambič V, Expression of Ki-67 antigen and proliferative cell nuclear antigen in benign and malignant epithelial lesions of the larynx. *Orig. Art.* **110**: 440
Zidar N, Gale N, Podboj J, Unusual inflamed thyroglossal cyst. *Path. Focus* **109**: 899
Zikry MA *see* Khalifa MS *et al.*
Zini C *see* Gamoletti R *et al.*; Sanna M *et al.*
Ziora D *see* Misiolek M *et al.*
Ziskind E *see* Puterman M *et al.*
Ziyada WF, Brookes JD, Penman HG, Expectorated tissue leading to the diagnosis of renal adenocarcinoma. *Clin. Rec.* **108**: 1108
Zohar Y *see* Talmi YP *et al.*
Zurlo J *see* Wolansky LJ *et al.*

SUBJECT INDEX

Vol. 104 1990 Vol. 105 1991 Vol. 106 1992 Vol. 107 1993 Vol. 108 1994

Vol. 109 1995 Vol. 110 1996 Vol. 111 1997 Vol. 112 1998 Vol. 113 1999

Abducens nerve
otitis media **110**: 872
sphenoid sinus mucocele **111**: 644
Abscess
Bezold's **105**: 765
bone, as cause of dysphagia **105**: 1084
cervical bilateral, fatal cyclical neutropenia **105**: 487
infectious mononucleosis **104**: 358, **112**: 1186
intra-operative ultrasound-guided drainage **112**: 1098
Luc's, middle ear infection **111**: 461
otogenic intracranial, risks **104**: 468
pyriform sinus fistula **109**: 886
Salmonella, with jugular vein thrombosis **105**: 966, **111**: 489, **113**: 1122
Staphylococcus aureus (MRSA), infant **110**: 78
Streptococcus bovis, undiagnosed colon cancer **111**: 666
see also organs and locations (cervical, parapharyngeal, retro-pharyngeal etc.)
Acanthoma fissuratum 105: 301
Accessory nerves
nasopharyngeal carcinoma **110**: 987
nerve sheath tumours **113**: 942
Acetic acid
antibacterial activity **112**: 925
Acetone
superglue removal from ear canal **109**: 1219
Acidic protein
immunosuppressive, head and neck cancer **105**: 939
Acidosis
renal tubular, in association with hearing loss **109**: 930
Acinic cell neoplasms
salivary gland **105**: 782
bilateral **105**: 796
DNA flow cytometry **104**: 410
undifferentiated spindle transformation **108**: 902
Acoustic analysis
tracheo-oesophageal vs oesophageal speech **108**: 325
Acoustic evaluation *see* Voice disorders
Acoustic impedance tests
adenoids in school-aged children **109**: 196
chloral hydrate **105**: 421
Eustachian tube barotitis **110**: 625
tympanic membrane perforation **105**: 716
Acoustic nerve
agenesis **113**: 1008
Acoustic neurinoma/neuroma
bilateral **105**: 769
cerebello-pontine angle lesions, ENT clinic **113**: 518
clinical correlates of morphology **107**: 290
closure of petrous apex of temporal bone with ionomeric cement **108**: 202
cochlear implantation **113**: 458
after resection of intracanalicular tumour **110**: 570
auditory rehabilitation **113**: 161
elderly patients, necessity for surgery? **107**: 295
electrocochleography **111**: 967
hearing preservation **109**: 374
oestrogen and progesterone receptors **104**: 865
population studies **113**: 818
Ramsay Hunt syndrome, mimicking on MRI **109**: 1013
surgery
1978-1990 **105**: 165
contralateral recovery of auditory brainstem response abnormalities after surgery **104**: 565
endoscopic-assisted excision **113**: 973
evaluation of facial nerve function **107**: 1119
translabyrinthine approach **105**: 34
via posterior fossa, hearing conservation **104**: 463
traumatic origin **104**: 270
unilateral hearing loss **107**: 230
unilateral tinnitus **113**: 818
see also Vestibular schwannoma
Acoustic rhinometry
control of height and angle **109**: 536
nasal polyps **105**: 178
septoplasty, and compensatory inferior turbinate hypertrophy **107**: 413
vs rhinohygrometry **109**: 503
Acoustic schwannoma
surgery, hearing preservation **106**: 500
translabyrinthine, effect of removal on tinnitus **106**: 329
Acrofacial dysostosis
double epiglottis **112**: 976
Acrokeratosis paraneoplastica
Bazex syndrome **110**: 899
Acromegaly
respiratory problems **104**: 52
Actinomycosis
middle ear **112**: 800
nasopharyngeal tumours **111**: 163
oto-mastoiditis **111**: 1069
posterior triangle **111**: 1082
presenting as acute upper respiratory tract obstruction **108**: 801
submandibular swelling **107**: 1169
thyroid gland **111**: 172
vallecula **109**: 154
Acute phase proteins
laryngeal carcinoma **106**: 613
surgical treatment of laryngeal carcinoma **106**: 613
Adenocarcinoma
in adult glue ear **110**: 62
basal cell, salivary gland, review of literature **107**: 862
ethmoid, metastatic **109**: 759
intestinal features **104**: 900
larynx, metastasis from rectal primary **112**: 199
maxilla **110**: 503
middle ear **104**: 915
mucoid, larynx **105**: 315
nasopharynx, papillary **105**: 853
oesophageal colonic interposition graft **108**: 80
palate, polymorphous low grade **105**: 309
papillary
lectin receptors **107**: 600
nasopharynx **105**: 853
paranasal sinus, intestinal type **110**: 805
salivary gland, metastatic to orbit and skin **109**: 1222
submandibular gland, positive serum and tissue immunohisto-chemical staining for both CEA and CA-125 **108**: 719
temporal bone **108**: 710
terminal duct, parotid gland **109**: 466
thyroid masses **110**: 192
tongue **110**: 700
Adenoid cystic carcinoma
CT, MR and Gd MR imaging techniques **104**: 662
histological changes **106**: 1016
and Hodgkin's disease **105**: 224
invasion of recurrent laryngeal nerve, vocal fold paralysis **113**: 260
larynx **112**: 712
parotid gland **111**: 491
sublingual salivary gland **111**: 485
tamoxifen **111**: 1186
trachea, excision **109**: 774
Adenoidectomy
day-case surgery **106**: 299, **109**: 1166, **111**: 444
review of literature **107**: 703
girl with haemophilia **105**: 957
and tonsillectomy

oropharyngeal microbial flora **108**: 763
paediatric admission and discharge policy **112**: 1047
Adenoids
and adenoidectomy, endoscopic approach and histopathology **104**: 965
cephalometric analysis **105**: 71
hypertrophy
arterial blood gases in children **105**: 436
HIV infection **104**: 58
nasopharyngeal airway obstruction **113**: 899
radiological assessment methods, vs clinical and endoscopic findings **106**: 342
in school-aged children **109**: 196
Adenolipoma
thyroid gland **110**: 1088
Adenolymphoma of parotid gland
carcinomatous transformation **104**: 656
Adenoma
basal cell, and pleomorphic, coexisting, parotid gland **111**: 182
base of tongue mass **111**: 1177
cystadenoma, parotid gland, unusual stroma **111**: 883
external auditory canal **110**: 52
heterotopic pleomorphic, external nares **110**: 376
malignant pleomorphic of parotid gland, multiple metastases **106**: 652
minor salivary glands **111**: 985
ossifying pleomorphic, maxillary antrum **106**: 50
parathyroid **111**: 459, **111**: 585
acute pancreatitis **110**: 602
parotid gland **113**: 779
pituitary
ectopic causing Nelson's syndrome **111**: 565
extension into nasopharynx **113**: 1109
pleomorphic
ancient schwannoma **111**: 1088
carcinomatous **109**: 677
child **109**: 343
clear cell carcinoma arising, submandibular gland **108**: 529
heterotopic, in neck **109**: 445
immunohistochemistry, differential diagnosis **105**: 1057
nasal septum **113**: 483
parotid gland
with cystic degeneration **108**: 446
cystic degeneration **108**: 446
recurrent **107**: 546
seeding **109**: 671
soft palate **109**: 240, **109**: 343
Adenomatoid hyperplasia
salivary glands **110**: 167
Adenosine deaminase
and superoxide dismutase, cancerous laryngeal surgery **108**: 849
Adenosquamous carcinoma
hypopharynx **105**: 678
Adenotonsillectomy
bismuth subgallate **108**: 761
middle meatus microbiology **113**: 24
tension pneumoperitoneum **109**: 440
Adiposis dolorosa (Dercum's disease) 113: 174
Admissions
children, otolaryngology **110**: 557
Adrenal suppression
betamethasone **106**: 827
Adrenaline
nasal mucosal blood flow **105**: 918
Adrenaline paste
and bismuth subgallate, role in tonsillectomy **109**: 206
Adrenoceptors
beta, human nasal mucosa **105**: 632
Aesthesioneuroblastoma 112: 446, **112**: 628
Ageing
animal model **110**: 13
and head and neck cancer **104**: 634
Ageusia
and anorexia **110**: 598
Aglossia 110: 1057
AGM-1470 (TNP-470)
nasopharyngeal carcinoma, experimental antiangiogenic therapy of **112**: 849
Agnosia
focal EEG abnormality **109**: 431
AIDS *see* HIV infections
Air travel
barotitis in children **110**: 625
induced meningitis following vestibular schwannoma (acoustic neuroma) surgery **110**: 258
Airflow *see* Nasal airflow
Airway control
failure, Hunter's syndrome **112**: 380
Airway obstruction
actinomycosis **108**: 801
after partial laryngectomies by radiological method, and flow–volume loop analysis **108**: 954
Brighton epistaxis balloon **107**: 140
causes **109**: 252
cricothyrotomy **105**: 883
encephalocele **113**: 369
Hurthle cell tumour metastases **107**: 957
immunocompromised child, candidiasis **106**: 168
infectious mononucleosis **112**: 1186
intraoperative herniation of a tracheostomy tube cuff **109**: 159
laryngeal cysts **110**: 854
laryngeal neoplasms in infants **110**: 969
neonatal upper airway obstruction caused by chlamydial rhinitis **109**: 58
neurofibroma of larynx, paediatrics **110**: 1065
Pierre Robin syndrome **111**: 1155
prenatal diagnosis with ultrasonography **110**: 583
retropharyngeal haematoma, metastatic carcinoma **113**: 258
ruptured aneurysmal arterio-venous fistula **109**: 562
sickle cell disease **105**: 851
snoring and oral submucous fibrosis **111**: 346
snoring and sleep apnoea **111**: 1151
with stridor, nasal secretions **109**: 331
thyroid carcinoma **110**: 1078, **110**: 1176
thyroid goitre **109**: 892
Vallecula angioleiomyoma **104**: 341
vocal fold paralysis **110**: 1027
well-differentiated thyroid carcinoma **107**: 752
Airway resistance
comparison of methods **109**: 414
histamine H_1 receptor blockade **109**: 841
peak inspiratory flow, plateau effect **109**: 399
pressure measurement, transducer probe vs open catheter **109**: 414
Alar cartilages
external perichondrium, ala of thyroid cartilage, non-diseased side **108**: 770
haematoma **108**: 500, **113**: 1104
Aldosterone
familial insensitivity of salivary glands **104**: 956
Algorithms
aspergillus sinusitis **108**: 314
Allergic reactions
bismuth-iodoform-paraffin paste, following ear surgery **112**: 335
Allergic rhinitis *see* Rhinitis
Allergic vasculitis
ANCA-associated, propylthiouracil **113**: 477
Allergy
molecular and cell biology **112**: 1126
Alpha-amylase
tracheobronchial secretions in tracheostomies **109**: 640
Amalgam tattoo
soft palate, energy dispersive x-ray analysis **106**: 834
Ambulatory care *see* Day-case care
Amelanotic melanoma
metastatic to the epiglottis **105**: 776
Ameloblastoma
maxilla **105**: 971, **109**: 1019
calcifying and keratinising **105**: 971
palate **104**: 252
Aminoglycosides
active mucosal chronic suppurative otitis media **113**: 10
erythema multiforme **113**: 1002
Ménière's disease **113**: 916
Amphotericin
rhinocerebral mucormycosis **105**: 575

Amylase activity
laryngectomized patients **109**: 637
tracheotomy patients **109**: 640
Amyloidoma
giant, tonsillar **110**: 613
Amyloidosis
external auditory canal **108**: 49
with laryngocele **113**: 361
larynx **108**: 339
massive haemorrhage of upper respiratory tract **107**: 51
Anacusis
residual hearing **113**: 714
Anaemia
and outcome in early squamous cell carcinoma, larynx, radical radiotherapy **113**: 829
see also specific anaemias
Anaesthesia
epidural, size of spinal needle, effect on post-operative hearing loss **106**: 783
Anaesthesia, inhalation
jet insufflation, microlaryngeal surgery, monitoring **106**: 42
laryngeal mask airway **110**: 383
Anaesthesia, local
cochlear implantation **112**: 533
endoscopy **110**: 540
Ligmaject system **104**: 606
otology **104**: 606
maxillary sinus lavage **110**: 763
uvulopalatopharyngoplasty **113**: 542
Analgesia
post-tonsillectomy pain **109**: 963
Anastomosis, surgical
recurrent laryngeal nerve, dogs **110**: 748
ANCA
negative, Wegener's granulomatosis **108**: 420
Aneurysmal bone cyst
hyoid **106**: 71
maxillary sinus **104**: 501
Aneurysms
arterio-venous fistula, ruptured **109**: 562
carotid artery, epistaxis and otalgia **109**: 865
extracranial internal carotid artery, child **113**: 373
false, maxillary sinus **106**: 1103
internal carotid arteries, epistaxis **109**: 650
jugular veins **110**: 179
leaking aortic aneurysm presenting as a recurrent neck swelling **109**: 163
mycotic, external carotid artery **112**: 793
petrous internal carotid artery **112**: 196, **113**: 55
pseudoaneurysm of carotid artery **109**: 889
unruptured intracranial, superficial siderosis **109**: 549
Angiocentric T-cell lymphoma
tongue, hypopharynx and supraglottis **113**: 263
Angioedema
secondary to angiotensin converting enzyme inhibitors **108**: 696
Angiofibroma
juvenile, imaging **113**: 127
nasopharyngeal masses **110**: 962
postnasal space **105**: 547
radiation therapy **104**: 725
see also Fibroma
Angiography
digital subtraction, penetrating neck injury **108**: 522
Angioimmunoblastic T-cell lymphoma
tonsillar squamous cell carcinoma **111**: 580
Angioleiomyoma
acute airway obstruction **104**: 341
nasal cavity, review of literature **108**: 244
nasal tip **107**: 448
Angiolymphoid hyperplasia
with eosinophilia **104**: 977, **109**: 262
with eosinophilia of parapharyngeal space **112**: 802
Kimura's disease **110**: 1084
Angiomyoma
retropharyngeal space **112**: 290
Angiosarcoma
head and neck **111**: 175
hypopharynx **108**: 905
nasal cavity **106**: 368
Animal models
acoustic properties of mastoid cavities **106**: 597
Apaceram, tissue reaction **109**: 14, **111**: 702
c-Fos, expression activated by tactile stimulation on laryngeal vestibulum, cat lower brainstem **109**: 39
canine trachea **105**: 207
carboplatin ototoxicity **107**: 585
CGRP-immunoreactive cells, laryngeal sensory nerve fibres, nodose ganglion of cat **107**: 916
cochlea
localization and specificity of guinea pig inner ear antigenic epitopes **109**: 19
post-natal bone growth **111**: 23
endoscopic nasal and sinus surgery training **110**: 425
immunohistochemistry, IgG, planum semilunatum of guinea pig **106**: 93
labyrinthitis, *Candida albicans* infection in ageing mice **110**: 13
lectin histochemistry **111**: 141
localization and specificity of guinea pig inner ear antigenic epitopes **109**: 19
maxillary sinus surgery **110**: 644
neurorrhaphy of recurrent laryngeal nerve **110**: 748
repair of facial nerve, carbon dioxide laser surgery **108**: 466
skin transplantation **110**: 629
training in endoscopic nasal and sinus surgery **110**: 425
Aniridia
and deafness, inherited disorder **104**: 419
Anisakiasis
tonsils **110**: 387
Ankylosing vertebral hyperostosis-Forestier's disease 104: 236
Anodontia
Waardenburg's syndrome **113**: 672
Anorexia
drug-associated **110**: 598
retropharyneal abscess **110**: 483
Anosmia
chlorine-induced **111**: 1075
Anthropology
Greenlandic Inuits, otitis media, study of past and present **110**: 1114
Antibacterial activity
acetic acid and Burow's solution **112**: 925
Antibiotics
acute and complicated sinusitis **112**: 264
biocompatible implantable, for necrotising external otitis **105**: 252
glycerine and ichthammol **110**: 319
grommet insertion, cost-benefit analysis following **110**: 527
head and neck masses, surgery, piperacillin and ornidazole **106**: 409
long-term therapy, ciliary beat frequency in chronic rhinosinusitis **109**: 24
mastoiditis **113**: 1081
otitis media **110**: 309
penicillin V, tonsillar surface fluid, in healthy individuals and in patients with acute tonsillitis **107**: 309
post-laryngectomy, pharyngocutaneous fistulae **104**: 225
prophylactic
postlaryngectomy pharyngocutaneous fistula **104**: 225
surgery for advanced head and neck cancer **106**: 621
tympanostomy tube otorrhoea **107**: 188, **110**: 531
rhinoscleroma, electron microscopy **104**: 772
sinusitis management in children **109**: 1159
steroid ear drop preparations **104**: 862
ventilation tube care **107**: 188
tonsillectomy, audit in children **110**: 357
topical, distribution in mastoid cavities **106**: 247
see also Aminoglycosides; *Other named*
Antibodies
respiratory tract viruses **105**: 337
Antidiuretic hormone
inappropriate secretion (SIADH)
after trans-spheroidal pituitary adenomectomy **104**: 894
consequence of neck dissection **111**: 449
Anti-neutrophil cytoplasmic antibodies (ANCA)
mucocutaneous allergic vasculitis, propylthiouracil **113**: 477
Antiphospholipid syndrome
audiovestibular manifestations **108**: 57

Antiseptic mouthwash
surgery of oral cavity and oropharynx **108**: 973
Antrochoanal fibrosarcoma
radiation injury **106**: 547
Antrochoanal polyps
endoscopy **110**: 272
strangulation **107**: 342
transcanine surgery **108**: 1055
treatment with intranasal steroids **109**: 553
Antroscopy
rhinoscleroma **106**: 697
Antrum exclusion technique
cholesteatoma surgery **106**: 120
Apaceram
animal models **109**: 14, **111**: 702
Aphasia
acquired, without deafness, Landau–Kleffner syndrome **107**: 623
Aphonia
functional **106**: 610
sudden onset **112**: 480
Apoptosis (cell death) 112: 822
Argon laser
epistaxis, hereditary haemorrhagic telangiectasia **111**: 34
Argon plasma coagulation
recurrent papillomatosis **111**: 381
Arnold–Chiari malformation
tinnitus and hearing loss **110**: 1060
Arterial anomalies
middle ear, associated with stapes ankylosis **108**: 237
Arterial blood gases
children, enlarged adenoids **105**: 436
Arteriovenous fistula
aneurysm, airway obstruction **109**: 562
and pulsatile tinnitus, occipital artery ligation **104**: 421
Arteriovenous malformations
carotico–cavernous fistula **113**: 744, **113**: 844
Arthritis, rheumatoid
inner ear involvement **109**: 713
Artificial larynx 109: 137, **109**: 1068
pneumatic, Hong Kong **108**: 852
Aryepiglottoplasty
laryngomalacia **105**: 1040
Arytenoid calcification
suspected foreign body **106**: 1089
Arytenoid carcinoma
and pancreatic neuroendocrine carcinoma **105**: 373
Arytenoid cartilage
complications of radiotherapy **110**: 789
vocal fold paralysis, paediatric surgery **110**: 1027
Arytenoidectomy
and posterior cordectomy **105**: 454
Aspergillosis
in AIDS **112**: 488
larynx **108**: 883
mastoiditis, HIV infection **111**: 560
necrotizing external otitis, in AIDS **112**: 98
paranasal **107**: 773
paranasal sinuses **111**: 1168
rhinocerebral **106**: 981
sinusitis
algorithmic approach **108**: 314
with proptosis **106**: 799
skull base osteitis **112**: 92
sphenoid sinus, transnasal endoscopic surgery **107**: 837
Aspiration
laryngeal closure at level of false cord **107**: 826
surgery **107**: 121
Aspiration cytology *see* Fine needle aspiration cytology
Atlanto–axial joint subluxation
otolaryngological diseases and procedures **109**: 1005
Atrophic rhinitis *see* Rhinitis
Audiology
clinical applications of oto-acoustic emissions, paediatrics **106**: 301
clinics
evaluation of direct referral for hearing aids **108**: 120
severe deafness **105**: 534
glomus tumours **111**: 218
head trauma **104**: 927
Audiometry
accuracy in medicolegal assessments **105**: 518
bilateral hearing loss **110**: 727
brain stem evoked response **109**: 605
complications, misdiagnosis of hearing loss due to ear canal collapse **110**: 561
cost–benefit analysis **110**: 527
developmental retardation, behavioural observation **109**: 605
evoked response, multiple sclerosis **110**: 252
head and neck neoplasms **109**: 744
speech and pure tone audiometry, secretory otitis media **107**: 787
tinnitus severity measurement **105**: 89
see also Hearing loss
Audiovestibular manifestations
antiphospholipid syndrome **108**: 57
Audit
antibiotics in tonsillectomy **110**: 357
blood transfusion policy, head and neck surgery **104**: 28
cochlear implant service, Manchester **110**: 1046
day-case surgery, peer review **112**: 161
emergency services **113**: 657
ENT pre-admission clinics **111**: 358
ENT unit **105**: 611
handicap, and unilateral neck dissection **105**: 760
management of cancers of larynx and pharynx **112**: 948
management of epistaxis, district general hospitals **108**: 38
mastoid surgery **109**: 971
nasal septum surgery **109**: 320
otitis externa, ENT casualty clinic, peer review **109**: 130
otolaryngology, children, routine admissions **110**: 557
overseas postgraduate training programme in ENT **108**: 1072
peritonsillar abscess **109**: 531
quality of tonsillectomy **113**: 135
regional screening guidelines for vestibular schwannoma **112**: 860
Scottish Otolaryngology Audit, laryngeal cancer **108**: 332
Scottish Tonsillectomy Audit *see Supplement No* 20
stapedectomy **109**: 317
suction toilet **109**: 971
tinnitus management **109**: 826
tympanic membrane, perforation following grommet or T-tube removal or extrusion **107**: 593
Auditory agnosia
with focal EEG abnormality **109**: 429
Auditory brain stem evoked responses
abnormalities after neuroma surgery **104**: 565
after radiotherapy for nasopharyngeal carcinoma **106**: 887
in infantile Gaucher's disease **112**: 1069
study of noise-induced deafness **112**: 1154
Auditory canal *see* Ear canal
Auditory evoked potentials
increased stimulus rate, head trauma **104**: 191
Auditory meatus *see* Ear canal
Auditory nerve
agenesis **113**: 1008
division, relief of tinnitus **105**: 1099, **105**: 1101, **105**: 1102, **105**: 1106
sarcoidosis **109**: 1089
vascular cross-compression by VIIth cranial nerve **106**: 436
Auditory ossicle
Apaceram treatment, rats **111**: 702
synthetic (Apaceram), tissue reaction **109**: 14
Auditory threshold
noise-induced hearing loss vs Ménière's disease **107**: 780
Augmentation rhinoplasty *see* Rhinoplasty
Aural papillomatosis
carbon dioxide laser **112**: 565
Aural polyps
inflammatory, conservative treatment **106**: 313
management **111**: 212
mast cells **109**: 491
metastasis from renal cell carcinoma **111**: 1066
as osteoma, external auditory meatus **107**: 935
as predictor of middle ear disease **105**: 268
Auricular cartilage *see* Ear, external

Auricular nerve
parotidectomy **111**: 556
Auronasopharyngeal polyp
and cholesteatoma **104**: 809
Autoantibodies
localization and specificity of guinea pig inner ear antigenic epitopes **109**: 19
Autografts
cartilage, capsule prolapse, temporomandibular joint **108**: 30
ossicular chain reconstruction **106**: 688, **106**: 692
Autopsy dissection
temporal bone **110**: 219
Autosuture GIA gun
treatment of hypopharyngeal diverticula **107**: 723

B-cell lymphoma *see* Lymphoma
Babington, Benjamin Guy
and his mirror **112**: 235
Bacteraemia
following tonsillectomy **111**: 950
Bacterial meningitis
sensorineural hearing loss **113**: 1011
Bacterial thyroiditis
presenting as otalgia **105**: 788
Bacteriology
adult middle meatus **110**: 847
cerumen, common aerobic flora **112**: 613
colonization of infant pacifiers **111**: 614
cyanobacteria, rhinosporidiosis **113**: 523
Fusobacterium necrophorum **105**: 119
group A Streptococci **105**: 439
Haemophilus influenzae **105**: 439
in vivo epithelial cells, nasopharynx, otitis media with effusion **106**: 111
maxillary sinuses, endoscopically normal **113**: 825
middle meatus, children requiring adenotonsillectomy **113**: 24
otitis media
chronic **110**: 315, **110**: 950
findings **104**: 749
inadequately treated **105**: 341
Pasteurella multocida **105**: 571
peritonsillar sepsis **105**: 553
Pseudomonas aeruginosa, typing **104**: 678
purulent secretions, chronic rhinosinusitis **112**: 1162
Salmonella spp. **105**: 966
secretory IgA and IgG-coated bacteria, chronically discharging ears **105**: 515
sinusitis **110**: 547
Streptococcus sanguis **104**: 430
tonsillar abscesses **111**: 392
tonsillitis **105**: 29
Balance disorders
sway weigh balance platform **109**: 836
Balloon
see also Epistaxis
Balloon dilatation
laryngostenosis **109**: 876
oesophageal stenosis, children **110**: 683
Barium sulphate aspiration
causing acute pneumonitis **107**: 347
Barotitis
in children after aviation **110**: 625
Barotrauma
adults **110**: 258
maxillary sinus, fifth cranial nerve involvement **105**: 217
Basal cell adenocarcinoma
parotid gland **104**: 150
salivary gland, review of literature **107**: 862
Basal cell carcinoma
external auditory canal **113**: 578
and Gorlin–Goltz syndrome **111**: 850
Basaloid squamous cell carcinoma 106: 370, **112**: 710
Basisphenoid
fractures, epistaxis **113**: 561
Bateman, Sir Geoffrey Hirst
obituary **112**: 1122
Bazex syndrome
acrokeratosis paraneoplastica **110**: 899

Bcl-2
nucleolar organizer regions, maxillary sinus tumours **111**: 38
Beclomethasone dipropionate
non-atopic rhinitis **105**: 12
Behçet's disease
cochlear implantation **112**: 169
Bell's palsy
recurrence, pregnancy **104**: 713
steroid therapy, electrophysiological study **108**: 940
tympanoplasty **110**: 1090
Beta adrenoceptors
human nasal mucosa **105**: 632
Betamethasone
adrenal suppression **106**: 827
hyposmia **110**: 132
Bezold's abscess 105: 765
Bilateral neck dissection
complication, blindness **104**: 154
Bing–Neel syndrome
malignant external otitis, Waldenstrom's macroglobulinaemia **108**: 492
Biochemical studies
bone destruction **110**: 534
Biocompatible materials
subcutaneous tissue reaction to synthetic auditory ossicle (Apaceram) in rats **109**: 14, **111**: 422
Biological dressings
clinical trials, middle ear surgery **112**: 140
Biopsy
Creutzfeldt–Jakob disease (vCJD) **113**: 1064
relapsing polychondritis **113**: 663
submandibular gland **109**: 853
ultrasound-guided
neoplasm metastases **113**: 988
salivary gland **113**: 988
see also Fine needle aspiration cytology
BIPP packs
mastoidectomy **105**: 916
BIPP-induced methaemoglobinaemia 105: 78
Birmingham bone-anchored hearing aid programme (1988–1995)
Supplement No 21, Vol. 110
Birmingham Mummy 109: 273
Bismuth subgallate
faster adenotonsillectomy **108**: 761
role in tonsillectomy **109**: 203
Bismuth tribromophenate
vs calcium sodium alginate, management of epistaxis **106**: 1067
Bismuth-iodoform-paraffin paste
allergic reactions **112**: 335
Bivona voice prosthesis
tracheo–oesophageal puncture **108**: 579
Blast injuries
ear **105**: 890
review of mechanisms and pathology **108**: 925
hearing loss **111**: 1137
non-explosive, ear **108**: 395
and weapons noise exposure, asymmetrical hearing loss **109**: 291
Blindness *see* Visual loss
Blom–Singer valve
submental abscess **108**: 1093
Blood coagulation tests
epistaxis **113**: 1086
Blood gas monitoring
children, enlarged adenoids **105**: 436
Blood transfusion
head and neck surgery, audit **104**: 28
laryngectomy for laryngeal carcinoma **105**: 293
Bone abscess
cause of dysphagia **105**: 1084
Bone autografts
ossicular chain reconstruction **106**: 688, **106**: 692
Bone cement
ionameric, neuro-otological surgery **106**: 949
Bone conduction
errors at high frequencies, medico-legal practice **107**: 305
transcranial attenuation in children, clinical applications **108**: 834

Bone disorders
ankylosing vertebral hyperostosis **104**: 236
maxillary sinus cyst **104**: 501
Bone exostoses
external auditory canal **105**: 844
Bone grafts
augmentation rhinoplasty **105**: 1018
deep oval windows **105**: 725
ossiculoplasty
audit **107**: 695
graft mass and hearing change at different frequencies **107**: 690
surgical techniques and hearing results **107**: 686
reconstruction of mandible **108**: 969
Bone polyostosis 105: 80
Bone regeneration
attic cholesteatoma **109**: 703
Bone remodelling
osteoma of paranasal sinuses **107**: 633
Bone and temporal fascia graft
closure of nasal septum perforation **112**: 1167
Bone wax
causing epistaxis **110**: 267
Bosnia
penetrating laryngeal injury: two case reports **109**: 144
Botryomycosis 111: 77
Botulinum toxin
Frey's syndrome **111**: 839
type A, for intrinsic rhinitis **112**: 248
voice disorders **110**: 551
Brachiocephalic trunk
successful management of tracheo-innominate artery fistula using interposition of a thymus pedicle flap **109**: 161
Brachytherapy
endoscopic ultrasound-guided, head and neck cancer **113**: 41
recurrent nasopharyngeal and naso-ethmoidal tumours **107**: 115
recurrent oropharyngeal tumours, salvage brachytherapy following radiotherapy **109**: 45
Brain herniation
middle ear cleft **105**: 477
Brain masses
hyposmia **113**: 750
Brain stem
vocal fold paralysis **110**: 884
Brain stem evoked response audiometry
developmental retardation **109**: 605
expression activated by tactile stimulation on laryngeal vestibulum in cat **109**: 39
increased stimulus rate, head trauma **104**: 191
Brain stem pathology
infantile Gaucher's disease, limited auditory brain stem response **112**: 1069
Brain tissue
heterotopia, adult recurrent meningitis **104**: 328
Branchial apparatus
branchial fistula **109**: 999, **110**: 391
Branchial arch/cleft/pouch
anomalies **106**: 137
carcinoma **111**: 80
first
anomalies **107**: 625
defects **108**: 240
fistula surgical technique **108**: 1078
fourth
anomalies **104**: 905, **107**: 238
evidence for thyroid development **108**: 71
fistula **107**: 458
thyroid development **108**: 71
third, fistula **108**: 1095
Branchial cyst 105: 790
aetiology, past and present theories **108**: 653
carcinoma **113**: 1031
cervical node metastases **108**: 1068
endoscopy **106**: 1006
MRI study, and per-oral excision **107**: 1054
nasopharyngeal **107**: 453
resection via endonasal approach **109**: 139
peroral excision **104**: 143
Branchial region
fistula **110**: 391
Branchio–oto–renal syndrome
bilateral congenital cholesteatoma **113**: 841
Branchioma
of nasopharynx, resection via endonasal approach **109**: 139
papillary thyroid carcinoma **110**: 490
parotid gland, facial paralysis **110**: 799
Breast carcinoma metastases
external auditory canal **108**: 808
British Association for Paediatric Otorhinolaryngology (BAPO)
abstracts **107**: 1180, **109**: 572, **112**: 204, **113**: 595, **113**: 1039,
British Institute of Radiology
carcinoma of laryngopharynx, fractionation regimes, radiotherapy **106**: 147
British Skull Base Society abstracts **107**: 81, 658, **108**: 909, **109**: 791
British Society for the History of ENT abstracts **110**: 297, **111**: 397, 1207, **113**: 282
Bronchial carcinoma
metastasis to tongue **108**: 1099
second primary tumours of larynx **104**: 629
Bronchial compression
detection during foreign body removal, pulse oximetry **104**: 50
Bronchial tree
foreign bodies **113**: 851
Bronchioloalveolar carcinoma 110: 503
Bronchoalveolar lavage fluid
respiratory tract infections **109**: 859
Bronchodilator therapy
device, tracheostomies **111**: 363
Bronchogenic cyst 112: 893
Bronchoscopy
diagnostic, training **113**: 149
endotracheal intubation **112**: 786
foreign bodies **105**: 466
and laryngoscopy, aided by laryngeal mask airway **106**: 722
radiological investigations, pre-endoscopic assessment of children with stridor **109**: 844
removal of foreign body **113**: 849
Brow incision
modification for access to anterior skull base and paranasal sinuses **109**: 134
Brown, Alfred Gardiner (1838-1882) 113: 304
Brucellosis
sensorineural hearing loss **107**: 1034
Buccal epithelium
in vivo culture, mastoiditis **105**: 413
Buccal fat pad (BFP)
and palatal rotating flaps **113**: 834
Bulimia
salivary gland hypertrophy **108**: 516
Burkitt's lymphoma
tonsil **104**: 991
Burning sensation in throat
caloripharyngeus **108**: 235
Burns
anterior nasal stenosis **104**: 497
Burow's solution
antibacterial activity **112**: 925
Button battery
foreign body **108**: 871
Byzantine texts
324–1453 AD **112**: 25

Caffeine
vocal folds, effects **113**: 341
Calcitriol therapy
in craniometaphyseal dysplasia **110**: 328
Calcium alginate
in tonsillectomy **105**: 191
vs bismuth tribromophenate, management of epistaxis **106**: 1067
Calculi
frontal sinus **112**: 570
salivary gland masses **109**: 767
salivary glands **112**: 784
Caldwell–Luc procedure
post-operative complications **110**: 228

Callus
laryngeal, presenting as neck lump **108**: 354
Caloric test
vs galvanic body sway test, vestibular schwannoma **113**: 118
Caloripharyngeus
burning sensation in throat **108**: 235
***Candida albicans* infection**
airway obstruction, immunocompromised child **106**: 168
cause of stridor in previously irradiated patient **112**: 575
epiglottitis, AIDS, oral fluconazole **109**: 337
invasive
jejunal free flap **112**: 1090
tonsil **111**: 1199
labyrinthitis in ageing mice **110**: 13
laryngeal chondroradionecrosis **110**: 789
silicone elastomers **110**: 240
Cannabis
in external ear **107**: 444
foreign bodies **105**: 774
Cannulas
surgical decannulation in tracheostomy **107**: 217
Capillary haemangioma
parotid **111**: 588
Capsaicin
pretreatment in experimentally-induced secretory otitis media **113**: 114
Carbamazepine
ageusia **110**: 598
Carbonic anhydrase isoenzymes
endolymphatic sac, human fetus and mouse embryo **106**: 98
Carboplatin
ototoxicity, animal model **107**: 585
Carcinoembryonic antigen (CEA)
adenocarcinoma of submandibular gland **108**: 719
Carcinogenesis
carcinoma of external ear **113**: 1004
exposure to sulphuric acid fumes from lead acid batteries **108**: 881
Carcinoid tumours
bilateral parotid, metastases **105**: 489
laryngeal **104**: 264, **105**: 683
atypical **109**: 455, **112**: 710
Carcinoma *see sites and types of carcinomas*
Carcinomatous transformation
malignant adenolymphoma of parotid gland **104**: 656
Carcinosarcoma
parotid gland, radiation injury **108**: 443
Carden anaesthetic tube
surgery around tracheostome **108**: 46
Carotico–cavernous fistula
following septorhinoplasty **113**: 844
presenting as pulsatile tinnitus **113**: 744
Carotid arteries
aberrant, repair of oesophageal stricture **111**: 772
aneurysm
causing severe dysphagia **108**: 67
epistaxis **109**: 650
epistaxis and otalgia **109**: 865
compression of the facial nerve **110**: 1081
external, mycotic aneurysm **112**: 793
extracranial internal aneurysm, child **113**: 373
fistula infected with MRSA **113**: 689
foreign bodies **110**: 793
internal, pseudoaneurysm in tonsillitis **105**: 588
intrapetrous internal, spontaneous dissection **104**: 491
invasion by tumour, B-Mode ultrasound **106**: 73
ligation, for posterior epistaxis, claudication on mastication **112**: 73
petrous internal, giant aneurysm **112**: 196
pseudoaneurysm **109**: 889
stab transection **112**: 387
subtemporal exposure, anatomical study **113**: 717
surgical flaps **109**: 1176
traumatic intracavernous pseudo-aneurysm, delayed massive epistaxis **112**: 396
Carotid endarterectomy
vocal fold paralysis **113**: 439
Carotid sinus massage
cervico-mediastinal haematoma **105**: 381
Carotid sinus syndrome
parapharyngeal tumours **107**: 955
Cartilage
auricular *see* Ear, external
Cartilage disorders
chondropathy, inherited degenerative, autosomal dominant **109**: 433
Cartilage-sparing otoplasty 111: 424
Cartilaginous metaplasia
chondrolipoma **111**: 656
epiglottis **104**: 903
Castleman's disease
head and neck masses **110**: 896
Casualty service
open access **106**: 719
Catheter
central venous, aberrant **105**: 491
central venous, and vocal fold paralysis **109**: 1107
Caustic injuries
oesophageal stenosis, stents **110**: 1041
Cautery *see* Silver nitrate
Cavernous haemangioma
facial nerve **111**: 858
hypopharynx, with numerous phleboliths **104**: 262
infraorbital nerve canal of maxillary sinus **112**: 872
nasal bones **106**: 264
temporal bone **106**: 1086
Cavernous lymphangioma
parotid **111**: 590
Cavernous sinus
thrombosis following manipulation of fractured nasal bones **110**: 69
Cavernous sinus syndrome
primary paranasal sinus, non-Hodgkin's lymphoma **112**: 777
Cefotaxime
intracranial complications of ear surgery **107**: 1005
prophylaxis in major non-contaminated head and neck surgery, one-day *vs* seven-day therapy **107**: 30
Cell count
subcutaneous tissue reaction to synthetic auditory ossicle (Apaceram) in rats **109**: 14
Cell–cell adhesion molecules
E-cadherin, in tongue carcinoma cell lines **108**: 957
Cellular mechanisms
ossicular erosion, chronic suppurative otitis media **107**: 12
Cellular proliferation markers
squamous cell carcinoma of head and neck **108**: 859
Cellulitis
computed tomographic findings **109**: 449
synergistic necrotizing, peritonsillar abscess **110**: 887
Cemento–ossifying fibroma
petromastoid **111**: 152
Central nervous system *see* Neurological; *specific names, organs and regions*
Cephalometric analysis
children with otitis media with effusion **105**: 71
Cephazolin
and metronidazole prophylaxis, head and neck surgery **111**: 631
Cerebellar artery
aneurysm **109**: 429
Cerebellar disease
(Lhermitte–Duclos), tinnitus **113**: 464
Cerebellar encephalocele
chronic suppurative otitis media, mastoid surgery **104**: 982
Cerebellar masses
sudden deafness **108**: 584
Cerebellopontine angle tumours 107: 1087
cerebral lymphoma **107**: 937
epidermoid tumour, diagnosis by MRI **108**: 438
lesions, ENT clinic **113**: 518
lipoma **107**: 553
meningioma **111**: 1022
metastasis from clear cell renal carcinoma, presenting as ear bleeding **110**: 370
posteriorinferior cerebellar artery aneurysm **109**: 429
primary malignant lymphoma **112**: 476

Cerebral aneurysms
unruptured intracranial, superficial siderosis **109**: 549
Cerebral masses
lymphoma, bilateral cerebellopontine angle lesions **107**: 937
naso-ethmoid schwannoma **105**: 578
Cerebrospinal fluid rhinorrhoea 111: 125
diffuse erosion of skull base **112**: 679
endoscopic management **111**: 1042
fistula, through inner ear, and meningitis **107**: 492
following vestibular schwannoma surgery, extended subtotal petrosectomy with obliteration **107**: 1122
and pneumocephalus, biopsy-associated in papilloma **112**: 657
presenting with tension pneumocephalus and hemiparesis **112**: 654
protein electrophoresis **106**: 504
radiography **105**: 274
Cerumen
common aerobic flora **112**: 613
Ceruminous gland tumours 106: 727, **109**: 180
Cervical cord compression
complicating tracheo-oesophageal puncture **105**: 1082
Cervical cyst *see* Branchial cyst
Cervical fusion
pharyngeal pouch following **112**: 1085
Cervical lymph nodes
non-conventional squamous carcinoma of larynx **113**: 619
palpation vs ultrasound, assessment of malignancy **107**: 821
ultrasound **111**: 245
see also Lymph nodes
Cervical lymphadenitis
Mycobacterium avium-intracellulare **109**: 70
Cervical lymphadenopathy
fine needle aspiration cytology **104**: 24
mycobacterial infection, diagnostic protocol **107**: 614
nodal metastasis, and hyoid bone mass **107**: 967
secondary to atypical mycobacterial infection **110**: 48
Cervical lymphomata
midline presentation **104**: 737
Cervical masses
abscess
in infectious mononucleosis **104**: 358
necrobacillosis **106**: 374
pyriform sinus fistula **109**: 886
carcinoma, chemotherapy **109**: 744
goitres, CT imaging **106**: 65
hamartomatous thymoma, extensive myoid differentiation **107**: 155
lymphadenopathy, haemangioma **104**: 513
meningocele, neck mass in patient with neurofibromatosis type-1 **106**: 463
tuberculosis **105**: 786
Cervical necrotizing fasciitis 110: 81
and radiotherapy **112**: 298
tonsillitis **108**: 435
Cervical nodal metastasis
features of branchial cysts **108**: 1068
Cervical osteomyelitis
cord compression, complicating pharyngeal myotomy **108**: 511
following laryngectomy **106**: 1096
Cervical osteophytes (Forestier's disease) 104: 236
dysphagia, transpharyngeal approach **113**: 366
stridor **113**: 65
Cervical pain syndromes
cricoid, hyoid, thyroid cartilages **109**: 49
Cervical sympathetic chain schwannoma
Horner's syndrome **111**: 493
Cervical thymic cyst 107: 950
Cervical vagus nerve
plexiform neurofibroma **106**: 643
Cervico–mediastinal haematoma
after carotid sinus massage **105**: 381
Cervicofacial actinomycosis
as acute upper respiratory tract obstruction **108**: 801
submandibular swelling **107**: 1169
Cetirizine
effects on nasal polyposis **112**: 1042
CGRP-immunoreactive cells
laryngeal sensory nerve fibres, nodose ganglion of cat **107**: 916
and SP, in cat larynx **107**: 522
Charing Cross protocol
endoscopic sinus surgery, CT scanning **109**: 1057
Cheiloplasty
reconstruction of floor of mouth defects **108**: 486
Chemical cautery
vs electrocautery, treatment of anterior epistaxis **104**: 617
see also Silver nitrate
Chemical labyrinthectomy
and cochlear implantation, Ménière's disease **113**: 666
Chemodectoma
glomus tympanicum, radiology **108**: 607
Chemotherapy
abscess in pterygopalatine fossa **112**: 296
aesthesioneuroblastoma **112**: 446, **112**: 628
combination, head and neck cancer, vs surgery with/without radiotherapy **107**: 211
head and neck neoplasms **109**: 744, **110**: 449, **111**: 607
ineffective in end stage squamous cell carcinoma **104**: 631
laryngeal necrosis **111**: 763
laryngeal preservation **105**: 7, **105**: 930, **113**: 433
Chiari-I malformation 107: 441
Chickenpox
facial nerve palsies **108**: 676
Chlamydia pneumoniae
otitis media with effusion **106**: 490
seroprevalence in otolaryngeal diseases **106**: 208
severe acute tonsillitis **108**: 135
Chlamydia psittaci
sensorineural hearing loss **111**: 855
Chlamydia trachomatis
cause of upper airway obstruction **109**: 58
tonsillitis **107**: 27
Chloral hydrate
middle ear pressure **105**: 421
Choanal atresia
bilateral, transnasal technique **105**: 1004
craniodiaphyseal dysplasia, deafness and nasal obstruction **110**: 328
endoscopic fenestration **109**: 31
endoscopic surgery **106**: 528
laser surgery **110**: 429
in siblings **110**: 665
transnasal approach **104**: 482
Choanal fibrosarcoma
radiation injury **106**: 547
Choanal leiomyoma 105: 1065
Choanal polyp
radiological diagnosis **107**: 159
Cholesteatoma 105: 268, **105**: 409, **105**: 1113
attic, osteoplastic changes **109**: 703
and auro-nasopharyngeal polyp **104**: 809
biochemical studies of bone destruction **110**: 534
causing duro-cutaneous fistula **104**: 241
childhood **105**: 343, **105**: 820, **112**: 742
closed cavity mastoid surgery, CT scanning **106**: 393
congenital **105**: 995
branchio–oto–renal syndrome **113**: 841
petrous bone **113**: 52
CT scanning **105**: 990
giant, with middle fossa extension, hearing preservation after labyrinthectomy **112**: 472
growth **105**: 261
image processing, stereotaxic techniques **110**: 322
intact canal wall tympanoplasty **110**: 1090
lymphoblastic acute leukaemia **112**: 867
and mastoid surgery, International Conference, Japan **106**: 1107
middle ear and mastoid, combined approach tympanoplasty failure **109**: 710
ossicle selection **111**: 807
ossicular destruction **108**: 541
post-traumatic **105**: 367
posterior mesotympanic **106**: 496
recurrence factors **109**: 590
review of definition, terminology and pathology **107**: 483
skin transplantation, animal model **110**: 629
soft posterior meatal wall reconstruction **112**: 31
solubilization of keratin debris **108**: 13

Cholesteatoma (continued)
surgery
antrum exclusion technique **106**: 120
open vs closed techniques **105**: 820
paediatric **105**: 820
preservation of cochlear function **104**: 945
rigid endoscopy **108**: 307
techniques **111**: 521
transforming growth factor-α (TGF-α) **112**: 750
Cholesterol cyst
and cholesterol granuloma, petrous temporal bone **106**: 465
Cholesterol granuloma
maxillary sinus **112**: 65
Chondroblastoma
nose **110**: 696
temporal bone **108**: 1115
Chondroid syringoma 111: 862
Chondrolipoma
cartilaginous metaplasia **111**: 656
nasopharynx **112**: 75
Chondroma
external auditory canal **112**: 278
nasal tumour **105**: 670
parapharyngeal space **112**: 294
Chondromyxoid fibroma
ethmoid and frontal sinuses **109**: 258
skull base **113**: 380
Chondropathy
inherited degenerative, autosomal dominant, new clinical entity **109**: 433
Chondroplastic grafts
augmentation rhinoplasty **104**: 539
viability **106**: 166
Chondroradionecrosis *see* Radiation injury
Chondrosarcoma
external auditory meatus **113**: 742
hyoid bone **106**: 273, **107**: 642
larynx **106**: 450, **109**: 168, **112**: 712
maxilla **106**: 53
mesenchymal
maxilla **108**: 785
nasal region, congenital **106**: 1081
myxoid, maxillary sinus **105**: 676
nasal cavity and paranasal sinuses **108**: 947
parapharyngeal space **105**: 484
petrous apex **111**: 368
Chorda tympani nerve
necrosis of incus **106**: 252
Chordoma
clivus, aspiration cytology **108**: 426
extranotochordal, presenting as multiple neck masses **107**: 942
image processing, stereotaxic techniques **110**: 322
parapharyngeal space **106**: 549
Choriocarcinoma
metastases to maxilla, severe intractable epistaxis **106**: 917
Choristoma
tonsil **110**: 101, **110**: 611
Choroid metastasis
undifferentiated nasopharyngeal carcinoma **112**: 667
Choroid plexus tumour
invasive, in Von Hippel–Lindau disease **106**: 429
Chromium exposure
severe chronic inflammation of mucous membranes **108**: 591
Chronic obstructive pulmonary disease (COPD)
tracheomalacia **112**: 788
Churg–Strauss syndrome
exophthalmos **110**: 578
Chylous fistula
after neck dissection, nutritional support **105**: 1052
Ciliotoxicity
antibiotics, long-term therapy, chronic rhinosinusitis **109**: 24
Pseudomonas aeruginosa, II lectin in cystic fibrosis **111**: 760
Cisplatin
children, hearing loss **109**: 926
laryngeal preservation **105**: 930
ototoxicity, and its relationship to eye colour **105**: 7
and VAC, ineffective in end stage squamous cell carcinoma **104**: 631
Cisplatin–albumin complex
head and neck cancer **106**: 832
Clear cell carcinoma
glycogen-rich, tongue **108**: 716
in pleomorphic adenoma of submandibular gland **108**: 529
Clear cell neoplasms 106: 553
Cleft palate
ear ventilation and outcome **113**: 1068
Clinical photographs
teaching aids **109**: 741
Clinical studies
bilateral acoustic neurofibromatosis **107**: 6
Clinical trials
beclomethasone dipropionate, non-atopic rhinitis **105**: 12
biological dressings, middle ear surgery **112**: 140
otolaryngology, reference standards **112**: 460
randomized, 30 year review **111**: 611
tympanoplasty in children **112**: 1147
Clinics
see also Day-case clinics
***Clostridium botulinum* toxin**
palatal myoclonus **107**: 208
Cloward's procedure
complication **112**: 1087
CO–N reaction
serological activity index, Wegener's granulomatosis **107**: 607
Coagulation
infra-red, bleeding mucosal telangiectasia **106**: 992
Cocaine
endoscopy **110**: 540
precipitating acute angle closure glaucoma **113**: 250
with/without adrenaline, nasal mucosal blood flow **105**: 918
Cochlea
interdependence and micromechanics, primates, medial olivocochlear efferent system (MOES) **107**: 883
localization and specificity of guinea pig inner ear antigenic epitopes **109**: 19
post-natal bone growth in dog **111**: 23
Cochlear dysfunction
following occipital fracture **108**: 54
Cochlear dysplasia
causing recurrent meningitis **107**: 726
Scheibe, with macrocephaly, single channel implantation **112**: 1065
Cochlear fistula
tympanic cavity **105**: 656
Cochlear function
inner ear cholesteatoma **104**: 945
Cochlear implants 111: 924
anacusis, residual hearing **113**: 714
assessment clinic **107**: 103
audit of patient care **110**: 1046
benign paroxysmal positional vertigo **113**: 922
in bilateral transverse fracture of the petrous bone **104**: 997
bilingual hearing acquisition **110**: 776
and chemical labyrinthectomy, Ménière's disease **113**: 666
chronic suppurative otitis media **111**: 228
Cogan's syndrome **111**: 928
complications **113**: 321
re-implantation into the contralateral ear **110**: 881
congenital deformities **106**: 967
deaf–blindness
Behçet's disease **112**: 169
in mitochondrial cytopathy **113**: 353
European symposium **106**: 1109
extrusion
delayed **109**: 56
keratitis, ichthyosis and deafness syndrome **111**: 465
preventative procedure **109**: 425
failure **109**: 542
failure due to unexpected absence of eighth nerve **112**: 646
fat graft in mastoid surgery **113**: 881
following temporal bone fracture **113**: 454
in grand mal epilepsy **112**: 567
Ineraid multichannel implant **107**: 673
local anaesthesia **112**: 533
neurofibromatosis type-2 **113**: 458
acoustic neuroma **110**: 570
auditory rehabilitation **113**: 161

new incision **109**: 821
Nijmegan results **111**: 1008
one-stage surgical procedure for placement **108**: 1031
otosclerosis **111**: 262
paediatrics **111**: 240
problems and complications **111**: 325
psychological assessment of patients **107**: 298
radiography **105**: 85
reimplanatation **109**: 980
skull growth and positioning of receiver–stimulator, infants **113**: 212
superficial siderosis **110**: 1151
surgical implications **113**: 321
surgical removal **112**: 338
Thailand **113**: 515
three-array, ossified cochlea **113**: 811
Wegener's granulomatosis **110**: 958
Cochlear otosclerosis
statistical analysis of relationship of spiral ligament hyalinization to hearing loss **104**: 952
Cochleo–vestibular failure
polyarteritis nodosa **104**: 562
Coffin–Lowry syndrome
sensorineural deafness, and labyrinthine anomaly **108**: 147
Cogan's syndrome
cochlear implantation **111**: 928
Colitis
sensorineural hearing loss **111**: 277
Collagen
injectable, safety **106**: 704
type-2, autoimmunity and Ménière's disease **107**: 994
Colon cancer
adenocarcinoma, metastasis to larynx **104**: 730
metastasis to palatine tonsil **108**: 449
undiagnosed, *Streptococcus bovis* abscess **111**: 666
Computer simulation
human tympanic membrane **106**: 878
Conchal flap meatoplasty 107: 1029
Concho–antropexy
vs total inferior turbinectomy, hypertrophy of inferior turbinates **107**: 1125
Conference Reports
cochlear implants **106**: 1109
Hong Kong and back 1991 **106**: 1105
Japan, on cholesteatoma and mastoid surgery **106**: 1107
Consent *see* Informed consent
Continuous ambulatory peritoneal dialysis
ototoxicity, gentamicin **107**: 681
Cord compression
cervical osteomyelitis **108**: 511
Cordectomy
teflon granuloma, vocal folds **109**: 1184
Cortical evoked potentials
criteria in objective assessment of auditory threshold, noise-induced hearing loss vs Ménière's disease **107**: 780
Corticosteroids
hypersensitivity, in otitis externa **107**: 597
nasal, long-term effects **106**: 810
Corynebacterium ulcerans
diphtheria, nasopharyngeal **106**: 824
Cost-benefit analysis
post-operative antibiotic ear drops following grommet insertion **110**: 527
vestibular schwannoma, screening protocol **110**: 1129
Costal cartilage implants
homologous **106**: 511
Cotinine
marker for smoking, head and neck cancer **105**: 1036
Cough
and stridor, investigations **107**: 639
Cowden's disease 107: 1064
palatal tonsil lymphocytes, immunophenotypes **106**: 640
Cowpox infection
of the nose **110**: 782
Cranial fasciitis
post-auricular mass **109**: 255
Cranial nerve palsies
Bell's palsy, recurrence in pregnancy **104**: 713
delayed, following stapedectomy **104**: 611
malignant otitis externa following mastoidectomy **113**: 1095
pathological features of facial nerve, electron microscopy **104**: 294
radiation-induced **105**: 44
recurrence, pregnancy **104**: 713
see also Facial nerve palsies
Cranial pneumatization
frequent Valsalva's manoeuvre **113**: 480
Cranial sinus anatomy
middle ear surgery **110**: 984
Craniofacial fibrous dysplasia 105: 662
Craniofacial implants
resonance frequency analysis **112**: 537
Craniofacial necrotizing fasciitis
secondary to sinusitis **112**: 371
Craniometaphyseal craniodiaphyseal dysplasia
deafness and nasal obstruction **110**: 328
Craniopharyngioma
ethmoid sinus **112**: 403
Creutzfeldt–Jakob disease (vCJD)
tonsillar biopsy **113**: 1064
Cricohyoepiglottopexy
long-term results **113**: 532
Cricoid cartilage
anterior cervical pain syndromes, treatment with triamcinolone acetonide **109**: 49
giant cell reparative granuloma **109**: 1120
release in preterm neonate **104**: 995
Cricoidectomy
with fibrin glue support, intractable salivary aspiration **110**: 72
Cricothyroidotomy
autopsy study **111**: 354
emergency **105**: 883
Crohn's disease
larynx **108**: 596
Croup
pulse oximetry **105**: 295
Crown Prince Frederick of Prussia: Suez and syphilis 109: 479
Cryoglobulinaemia
nasal septum **110**: 668
Cryosurgery
treatment of nasal obstruction **109**: 729
and turbinectomy, for hypertrophic inferior turbinates **110**: 732
CSF *see* Cerebrospinal
CT scanning
3-D helical **110**: 604
after intracordal autologous fat injection **112**: 971
blow-out fracture of orbital floor **107**: 161
cervical and mediastinal goitres **106**: 65
cholesteatoma, closed cavity mastoid surgery **106**: 393
chronic suppurative otitis media **105**: 990
complicated suppurative sinusitis **110**: 673
computerized axial, Charing Cross protocol, endoscopic sinus surgery **109**: 1057
and endoscopy, in sinus surgery **112**: 986
facial paralysis, decompression of first segment **109**: 935
helical, incudostapedial joint, 3-D reconstruction **113**: 707
image analysis, DNA in squamous cell carcinoma **111**: 141
impacted foreign body in oesophagus **112**: 360
inflammatory sinonasal disease **109**: 27
juvenile angiofibroma **113**: 127
laryngoceles **108**: 266
metastatic anaerobic orbital abscess **105**: 1086
and MRI **110**: 182, **110**: 269
following radiotherapy **107**: 565
lateral sinus thrombosis **105**: 693
nasal lipoma **110**: 269
nasopharyngeal carcinoma, radiotherapy of paranasal sinuses **110**: 19
necrotizing external otitis **112**: 98
osteoplastic changes **109**: 703
otolaryngology **110**: 604, **110**: 673
paranasal sinuses **105**: 20
endoscopic sinus surgery **104**: 477, **105**: 181
enlargement in Sturge–Weber syndrome **113**: 177
peritonsillar abscess and cellulitis **109**: 449
peritonsillar infections **113**: 229

CT scanning (continued)
and positron emission tomography, trismus **112**: 303
temporal bone, tuberculous otitis media **108**: 702
temporocele **113**: 661
tonsillar infections **113**: 229
upper respiratory tract scleroma **105**: 198
X-ray
diagnosis of inflammatory sinonasal disease **109**: 27
facial paralysis, and tuberculosis **109**: 1013
osteoplastic changes **109**: 703
Cuba
programme for laryngeal papillomatosis **111**: 134
Cutaneous neoplasms
B-cell lymphoma **112**: 186
Hodgkin's disease **113**: 765
lymphoma **113**: 948
metastases, laryngeal carcinoma **111**: 654
parotid gland **113**: 779
sebaceous gland carcinoma, postauricular region **105**: 954
Cyanoacrylate
otorhinolaryngology and head and neck surgery **111**: 536
Cyanobacteria
rhinosporidiosis **113**: 523
Cyclin D1
expression
laryngeal squamous cell carcinomas **111**: 622
prognostic factor in advanced hypopharyngeal carcinoma **112**: 552
progression from low-grade dysplasia to laryngeal carcinoma **112**: 455
Cystadenomatosis
papillary, larynx **106**: 656
parotid gland, unusual stroma **111**: 883
Cystic carcinoma
and Hodgkin's disease **105**: 224
Cystic fibrosis
gene therapy **113**: 329
Pseudomonas aeruginosa II lectin reaction **111**: 760
Cystic hygroma
massive, recurrence **104**: 908
parotid gland **107**: 855
Cystic lymph node
metastasis from occult thyroid carcinoma **106**: 932
Cystic lymphangioma
parotid **106**: 566
Cystic vestibular schwannomas
neuroimaging and growth rate **108**: 375
Cysts
air, maxillary sinus *(pneumosinus dilatans)* **105**: 673
dermoid **104**: 141, **104**: 578, **105**: 227, **107**: 335, **111**: 1179
giant cervical, occult thyroid carcinoma: **105**: 863
iatrogenic epidermoid cyst of the parotid region following ear surgery **105**: 227
nasolabial cyst **113**: 747
oncocytic cysts, of larynx **109**: 1226
parathyroid neck mass **113**: 73
peroral excision **104**: 143
polycystic disease of salivary glands **109**: 165
saccular, of larynx **109**: 653
subglottic, neonates **105**: 222
see also locations (parapharyngeal, peritonsillar, retropharyngeal etc.)
Cytology
fine needle aspiration
submandibular gland neoplasms **109**: 853
tuberculosis of thyroid gland **109**: 36
Cytomegalovirus
AIDS **109**: 1113
in idiopathic facial nerve palsy or sudden deafness **112**: 617
ulceration of oropharynx **105**: 739
Cytopathy
cochlear implantation **113**: 353

Dacryocystorhinostomy
holmium:YAG laser **111**: 1056
Dansac mini cap
waterproof ear protection **104**: 763
Dapsone
rhinosporidiosis **107**: 809
Darier's disease
external ear **106**: 725
Day-case clinics
admissions, evaluation for otolaryngology **110**: 557
casualty service **106**: 719
cerebello-pontine angle lesions **113**: 518
ENT pre-admission, audit **111**: 358
neurotology, evaluation of dizziness **113**: 19
open access, audit **113**: 657
otitis externa, audit **109**: 130
patient satisfaction **113**: 1072
setting up and first year of a freestanding unit **108**: 406
Day-case surgery
adenoidectomy **111**: 444
parental opinions and concerns **108**: 470
adenoidectomy and tonsillectomy **106**: 299
adult tonsillectomy **109**: 1166
head and neck surgery, future **110**: 717
KTP-532 laser tonsillectomy **109**: 515
microlaryngeal surgery **112**: 351
myringoplasty **110**: 421
nasal septal surgery **111**: 1034
nasal septum **109**: 614
neck masses **112**: 1061
peer review, audit **112**: 161
salivary gland lesions, fine needle aspiration cytology **107**: 1025
septoplasty **110**: 129
tonsillectomy **107**: 706
review of literature **107**: 703
Deafness *see* Hearing loss
Deglutition disorders
angiocentric T-cell lymphoma **113**: 263
bone abscess **105**: 1084
cricohyoepiglottopexy **113**: 532
dysphagia as major symptom of tetanus **106**: 923
foreign body in thyroid **107**: 1057
histiocytosis, with hoarseness and stridor **107**: 1061
in jugular foramen surgery **110**: 144
milk nasendoscopy **106**: 525
multidisciplinary management **109**: 419
presentation of myasthenia gravis **112**: 1194
real and imagined **105**: 807
and salivary gland neoplasms **113**: 569
secondary to invasive candidiasis of a jejunal free flap **112**: 1090
styloid apparatus anomaly **105**: 964
transpharyngeal approach in Forestier's disease **113**: 366
Dental osseointegrated implants
maxillary sinusitis **104**: 333
screw avulsion **105**: 573
Dental osseointegration
one-stage procedure **109**: 593
Dental sensation
altered following intranasal surgery **107**: 1011
Dental treatment
surgical emphysema **113**: 756
Dentigerous cysts 110: 1157
maxillary antrum, with epiphora **111**: 641
Dentures
potential hazard for night denture wearers **108**: 350
Dercum's disease (adiposis dolorosa) 113: 174
Dermoid cysts
following ear surgery **105**: 227
middle ear **107**: 335
midline sublingual presentation **104**: 578
mouth, ultrasound **104**: 141
tongue masses **111**: 1179
Desmoid-type fibromatosis
parotid gland **111**: 669
Dexamethasone
in Ménière's disease, intractable vertigo **113**: 217
Diabetes insipidus
and hypercalcaemia, secondary to nasopharyngeal carcinoma **104**: 43
Diabetes mellitus
hearing impairment in Mexican American adults, population-based study **112**: 835
hearing loss **107**: 179
hearing thresholds **108**: 837

ketoacidotic patient, rhinocerebral mucormycosis **107**: 233
melioidosis of parapharyngeal space **105**: 582
microangiopathy, inner ear **113**: 13
sudden sensorineural deafness **110**: 59
Dialysis
gentamicin administration **105**: 999
gentamicin ototoxicity **107**: 681
Diathermy
bipolar, complications **109**: 733
haemostasis at tonsillectomy, survey of UK otolaryngologists **104**: 549
or ligation, haemostasis in tonsillectomy, prospective study on post-operative pain **106**: 21
post-operative morbidity in electrodissection tonsillectomy **109**: 209
post-tonsillectomy pain control **110**: 446, **110**: 1038
punctate, surgery, soft palate **109**: 849
safety **104**: 408
sequestration of turbinate **105**: 14
Diet-modified sex hormone metabolism
squamous cell carcinoma **109**: 873
Digital subtraction angiography
penetrating neck injury **108**: 522
Diphtheria
Corynebacterium ulcerans, nasopharyngeal **106**: 824
Disinfectants
carcinoma of external ear **113**: 1004
Distress
tinnitus-associated **112**: 258
Diving infections
marine halophilic *Vibrio* sp., otitis media **109**: 1082
DNA analysis
myoepitheliomas, and nucleolar organizer regions (NORS) **106**: 616
squamous cell carcinoma, computerized image analysis **111**: 141
DNA flow cytometry *see* Flow cytometry
DNA probes
papilloma virus and p53 oncoprotein, verrucous carcinoma of larynx **110**: 742
Dogs
cowpox infection of the nose **110**: 782
see also Animal models
Down's syndrome
episodic macroglossia **104**: 494
macroglossia **104**: 494
Drug administration
alternatives for otitis externa and chronic suppurative otititis media **109**: 101
nasal drops
cocaine, and glaucoma **113**: 250
instillation positions **113**: 326
oropharyngeal drug therapy **113**: 1092
Dudenoside
intubation granuloma **113**: 427
Dural metastases
vocal fold paralysis **110**: 884
Duro–cutaneous fistula
caused by 'congenital' cholesteatoma **104**: 241
Dysequilibrium
otitis media with effusion **104**: 682
Dyskeratosis
congenital and nasopharyngeal atresia **106**: 996
Dysphagia *see* Deglutition disorders
Dysphonia
botulinum toxins **110**: 551

E-cadherin
cell–cell adhesion molecules, in tongue carcinoma cell lines **108**: 957
Ear
middle *see* Middle ear
Ear bleeding 107: 137
Ear canal
auditory meatus **105**: 112
conchal flap meatoplasty **107**: 1029
foreign body **111**: 1086
collapse, complicating audiometry **110**: 561
dressings, pope wick **106**: 327
eccrine cylindroma **108**: 706
exostoses and osteomata **108**: 106
foreign bodies, water used to visualize and remove **106**: 157
internal, lesions **112**: 650
irrigation, tympanic membrane rupture **109**: 1036
meatal fibrosis **110**: 417
osseointegrated screw avulsion **105**: 573
reconstruction, radiation-induced necrosis **112**: 1142
resonance and hearing loss **111**: 810
white noise generators for tinnitus, retraining therapy **111**: 810
superglue removal **109**: 1219
and temporomandibular joint fistula, complication of otitis externa **106**: 994
Ear canal neoplasms
acanthoma fissuratum **105**: 301
auditory meatus
meningioma **111**: 148
neurofibroma **111**: 145
osteoma presenting as aural polyp **107**: 935
pilomatrixoma **107**: 333
basal cell carcinoma **111**: 850
benign fibrous histiocytoma **110**: 98
bilateral carcinoma **105**: 112
bleeding, renal cell carcinoma metastasis **110**: 370
breast carcinoma metastases **108**: 808
'ceruminoma' **109**: 180
chondroma **112**: 278
meningioma, vestibular **113**: 1101
multiple myeloma **112**: 469
myxoma **105**: 364
non-Hodgkin's lymphoma, in HIV-positive patient **109**: 751
osteoma **110**: 158
unilateral hearing loss **106**: 905
paraganglioma **107**: 228
schwannoma **107**: 829, **109**: 1016
intracranial spread and lateral extension **108**: 149
sebaceous carcinoma **113**: 578
stenosis
parotid gland neoplasms **110**: 493
salivary gland neoplasms **110**: 493
vascular malformations **107**: 1039
xanthogranuloma, juvenile **109**: 975
Ear defects
osseointegrated implants, Birmingham **107**: 502
Ear drops
and antibiotics **104**: 862
delivery systems **105**: 359, **105**: 651
Ear, external
acute auricular haematoma **110**: 862
auditory meatus, myxoid chondrosarcoma **113**: 742
auricle, leiomyosarcoma **112**: 166
auricular cartilage
extended partial laryngectomy **110**: 739
pseudocyst **104**: 31, **107**: 39
and pseudocyst of auricle, histological examination **106**: 103
cannabis in **107**: 444
cartilages
infection, therapy **110**: 154
infolding of pinna **105**: 362
meatoplasty, Marfan syndrome **110**: 456
pseudocyst **110**: 767
surgery **110**: 864
Darier's disease **106**: 725
keratosis, pachyonychia congenita syndrome **110**: 1145
masses **110**: 52
carcinoma, hypochlorite disinfectants **113**: 1004
melanoma **107**: 798
pinnal malignancy
Merkel cell carcinoma **111**: 1195
temporal bone resection **107**: 697
Pneumocystis carinii **113**: 555
postauricular region, cutaneous sebaceous gland carcinoma **105**: 954
solitary myofibroma **113**: 155
orf of pinna **105**: 947
Pneumocystis carinii infection **113**: 555
sensory nerve supply **109**: 1141
somatic sensory supply, communicating branches **109**: 1141

Ear, external (continued)
sweating in auditory canal **113**: 1000
see also Otitis externa
Ear nodule
Rosai–Dorfman disease **106**: 249
Ear protection
Dansac mini cap **104**: 763
Ear surgery
intracranial complications, role for cefotaxime **107**: 1005
Ear swabs
tubotympanic CSOM **104**: 460
Ear syringing
malignant external otitis **104**: 709
Ear and temporal bone tumours
molecular genetics **112**: 1011
Ebner's gland tumour
microcystic adnexal carcinoma **109**: 1211
Eccrine cylindroma
ear canal **108**: 706
Echinococcosis 110: 978
hydatid cyst, temporal **108**: 601
Echography
metastatic nodes treated by radiotherapy **113**: 993
Ectodermal duct
nasolabial cyst **113**: 747
Ectodermal dysplasia 110: 379
Education *see* Medical education
EGF
and EGFR, laryngeal masses **109**: 630
Egypt
hypopharyngeal neoplasms, age and sex incidence **109**: 737
Eighth nerve *see* Auditory nerve
Electrocautery
para-incisional tattooing **113**: 244
vs chemical cautery, anterior epistaxis **104**: 617
Electrocoagulation
causing blindness, following functional endoscopic sinus surgery (FESS) **110**: 261
tracheotomy **110**: 765
Electrocochleography 104: 326
investigation of endolymphatic hydrops, hearing loss **108**: 125
Electrode
for recurrent laryngeal nerve monitoring **112**: 561
Electroencephalogram
odour stimulation in humans **110**: 652
Electron microscopy
chondromyxoid fibroma, skull base **113**: 380
facial palsy, pathological features of facial nerve **104**: 294
head and neck masses **106**: 403
mast cells ultrastructure **105**: 1006
nasopharyngeal carcinoma **105**: 349
paraganglioma **110**: 196
rhinoscleroma, rifampicin **104**: 772
Electrophoresis
diagnosis of cerebrospinal fluid rhinorrhoea **106**: 504
Embolization, therapeutic 109: 889
for epistaxis **113**: 252
glomus jugulare tumour, and facial palsy **113**: 268
surgery for nasopharyngeal angiofibroma **107**: 514
Embryology
atypically located submandibular gland diagnosed by Doppler ultrasound **110**: 1171
Emergency services
audit **113**: 657
EMLA cream
analgesic in painful otitis externa **104**: 887
vs iontophoresis, tympanic membrane anaesthesia **104**: 195
Empyema
bilateral thoracic, complicating adult epiglottitis **105**: 858
Encephalocele
airway obstruction **113**: 369
complication of intranasal sinus surgery, MRI **112**: 790
sphenoid sinus, Le Fort I osteotomy approach **112**: 779
Enchondroma 105: 148
Endarterectomy
vocal fold paralysis **113**: 439
Endochromatosis
Ollier's disease, and Maffucci's syndrome **113**: 861
Endocrine gland neoplasms
paraganglioma **113**: 978
Endolymphatic sac
carbonic anhydrase isoenzymes, human fetus and mouse embryo **106**: 98
fetal, glycoconjugates detected by lectins **105**: 711
hydrops
electrocochleography **108**: 125
precipitated by haemodialysis **104**: 641
inner ear deformity, MRI **111**: 754
operation for relief of vertigo **105**: 1109
revision surgery, long-term results **104**: 613
surgery in Ménière's disease **110**: 1008
Endometrial carcinoma metastasis
causing mucocele of maxillary antrum **112**: 283
Endometriosis
parenchymal pulmonary **105**: 235
Endoscopic anatomy
sphenoid sinus **113**: 122
Endoscopic surgery
acoustic neuroma **113**: 973
aspergillosis, sphenoid sinus **107**: 837
balloon dilatation, subglottic stenosis **109**: 876
computerized axial CT scanning **109**: 1057
ethmoid sinus, orbital protrusion **113**: 754
interpretation of dilated pupil during sinus surgery **112**: 622
ligation of sphenopalatine artery (ELSA) **110**: 27
metallic foreign body at sphenoethmoidal junction **106**: 998
nose and paranasal sinuses
with CT **112**: 986
deviated nasal septum **112**: 934
mucoceles **112**: 36
oro-nasal transfer of nasogastric tube **112**: 644
resection of inverted papilloma **112**: 758
uncinectomy **112**: 547
visual pathways **112**: 622
paranasal sinuses (FESS)
electrocoagulation causing blindness **110**: 261
visual evoked potentials (VEPs) **110**: 261
pharyngeal pouches **113**: 237
post-operative barium swallow radiography **113**: 233
posterior choanal atresia **106**: 528
sinus surgery, instrumentation **110**: 360
sinuses, management of chronic rhinosinusitis **108**: 749
sphenoid sinus schwannoma **113**: 466
stapling diverticulotomy, recurrent pharyngeal pouch **112**: 954
tracheo–oesophageal fistula **109**: 1077
training, nasal and sinus surgery, animal models **110**: 425
transcanal myringoplasty **106**: 493
Endoscopic ultrasound-guided brachytherapy
head and neck cancer **113**: 41
Endoscopically-assisted nasogastric feeding tube placement 113: 839
Endoscopy
branchial cyst of nasopharynx: resection via endonasal approach **109**: 139
choanal atresia in siblings **110**: 665
chronic sinusitis **110**: 926
computer-assisted image processing, nasal mucosa **110**: 1017
diagnosis of inflammatory sinonasal disease **109**: 27
epistaxis **110**: 432
fracture of basisphenoid **113**: 561
fenestration of choanal atresia **109**: 31
flexible **109**: 1077
laterofixation, vocal folds, bilateral abductor paralysis **106**: 31
lesions of sella turcica, management **109**: 956
local anaesthesia **110**: 540
multidirectional photography **112**: 464
nasal myiasis **108**: 1083
nasal polyps, antrochoanal, in a child **110**: 272
nasendoscopy guided removal of foreign bodies from base of tongue and vallecula **109**: 534
panendoscopy, complications **106**: 903
posterior fossa **112**: 227
posterior nasal obstruction **106**: 977
and radiology
assessment of children with stridor **109**: 844
maxillary sinus, primary atrophic rhinitis **106**: 702

removal of fish bones from base of tongue and vallecula **109**: 534
rhinosinusitis, children **113**: 1
rigid, in cholesteatoma surgery **108**: 307
sinusitis **110**: 641
sphenoid sinus **110**: 850
surgery, Charing Cross CT protocol **109**: 1057
upper gastrointestinal tract, globus syndrome **107**: 535
see also Laryngoscopy; *regions and procedures*
Endotoxins
damage to stria vascularis, sensorineural hearing loss secondary to otitis media **108**: 310
Endotracheal intubation *see* Tracheal intubation
Energy dispersive x-ray analysis
soft palate, amalgam tattoo **106**: 834
Engelmann's disease
vestibular nerve dysfunction and decompression **110**: 462
Enophthalmos
surgery **109**: 868
ENT *see* Otolaryngology
ENT Comparative Audit Meeting RCS(Eng) abstracts **112:** 1105, **113:** 1129
Enteral nutrition
nasogastric feeding tube **113**: 839
Enterocystoma
giant, infant's tongue **104**: 814
Entomophthoromycosis
of nose **110**: 1154
Eosinophilia
with angiolymphoid hyperplasia **104**: 977
parapharyngeal space, with angiolymphoid hyperplasia **112**: 802
Ephedrine
nebulized racemic, laryngeal relapsing polychondritis **106**: 63
Epidemiology
acoustic neurinoma/neuroma **113**: 818
allergic rhinosinusitis **112**: 1019
Bosnia, penetrating laryngeal injury **109**: 144
cerebello-pontine angle lesions, ENT clinic **113**: 518
Cuba, laryngeal papillomatosis **111**: 134
eardrum pathology in a cohort (born 1995) **109**: 281
Egypt, hypopharyngeal neoplasms, age and sex incidence **109**: 737
facial nerve palsies, bilateral **105**: 625
Greenlandic Inuits
otitis media **110**: 1114
study of past and present **110**: 1114
hearing impairment in diabetic Mexican Americans **112**: 835
hearing impairment in Saudi children **108**: 294
hearing loss and ear pathology, Nepal **107**: 395
Hong Kong, otitis media **111**: 804
India, mastoid air cell system variation **104**: 603
Jewish population of Jerusalem, childhood deafness **104**: 675
Jordan, nasopharyngeal carcinoma **105**: 432, **113**: 422
jugular bulb, position, influence of race **109**: 610
Kenya, nose and maxillary sinus tumours **106**: 337
Lapps, otalgia **104**: 109
lip carcinoma **105**: 640
Maori children, otitis media **105**: 257
mastoid surgery **105**: 409
Nepal, ear disease **105**: 1113
Nigeria, nasal septal haematoma **106**: 396
Nijmegan study, cochlear implantation **111**: 1008
North Iraq, otomycosis **104**: 387
oral carcinoma **105**: 643
otitis media, suppurative, schoolchildren in Hampshire schools **108**: 930
premalignant change, nasal and sinus polyps (1979-1988) **104**: 210
recurrent respiratory papillomatosis, Manchester 1974–1992 **108**: 226
rhinosporidiosis, Europe **106**: 440
Saudi children, hearing loss, and renal tubular acidosis **109**: 930
sensorineural hearing loss, sickle cell anaemia, UK **107**: 790
seroprevalence of *Chlamydia pneumoniae* infections in otolaryngeal diseases **106**: 208
Sichuan, China, prevalence and aetiology of hearing loss **107**: 990
Singapore, stapedectomy, otosclerosis **109**: 225
thyroid masses, Japan **110**: 657
tympanic membrane pathology, 1955 cohort **109**: 281
West Midlands region of England, ENT **107**: 313
Epidermoid cyst
following ear surgery **105**: 227
Epidermoid tumour
cerebellopontine angle, diagnosis by MRI **108**: 438
Epidural application
ionomeric cement implants **112**: 344
Epiglottis
amelanotic melanoma, metastatic **105**: 776
cartilaginous metaplasia **104**: 903
double, in Weyer's acrofacial dysostosis **112**: 976
nasotracheal intubation **106**: 1072
and obstructive sleep apnoea syndrome **112**: 940
ossification **106**: 180
positive airway pressure therapy, sleep apnoea **113**: 1022
solitary plasmacytoma **112**: 174
surgery **109**: 871
cricohyoepiglottopexy **113**: 532
Epiglottitis
acute, adult **105**: 839
AIDS, oral fluconazole **109**: 337
and bilateral thoracic empyema **105**: 858
Epinephrine, nebulised
adrenaline, expulsion of intra-nasal foreign bodies in children **110**: 559
Epiphora
maxillary antrum, dentigerous cyst **111**: 641
Epistaxis
anatomical and clinical correlates **104**: 308
antrochoanal polyp **104**: 643
associated with hereditary haemorrhagic telangiectasia, epithelial sheets, tissue culture **107**: 510
audit, district general hospitals **108**: 38
balloon catheters **107**: 197
airway obstruction **107**: 140
Foley's **107**: 142, **107**: 1032, **108**: 399
basisphenoid fracture in child **113**: 561
bismuth tribromophenate vs calcium sodium alginate packing **106**: 1067
blood coagulation tests **113**: 1086
carotid artery aneurysm **109**: 865
carotid artery ligation, claudication on mastication **112**: 73
conservative management **104**: 868
delayed massive, traumatic intracavernous carotid artery pseudoaneurysm **112**: 396
electro- vs chemical cautery **104**: 617
endoscopy **110**: 432
fibreoptic nasolaryngoscopy **105**: 17
following nasal tamponade **110**: 265
following sphenoid sinus exploration **108**: 171
hereditary haemorrhagic telangiectasia
argon laser **111**: 34
Young's procedure **108**: 754
internal carotid artery aneurysm **109**: 650
ligation of sphenopalatine artery (ELSA) **110**: 27
management **111**: 361, **112**: 331
microscope and hot wire cautery **108**: 845
nasal endoscopy **105**: 428
position, fixation of Foley catheter **107**: 1032
and proptosis, osteosarcoma of ethmoid **110**: 676
renal-derived **107**: 144
severe intractable **111**: 1192
combined internal maxillary and anterior ethmoidal artery occlusion **106**: 507
complications **113**: 252
maxillary choriocarcinoma **106**: 917
nasal cavity testicular teratoma **112**: 1078
treatment **110**: 543
vertebro–carotid artery anastomosis **108**: 247
von Willebrand's disease, and Wilms' tumour **108**: 1081
and warfarin, case controlled study **107**: 195
waxes **110**: 267
Young's procedure **105**: 847
Epithelial atypia and squamous metaplasia
in nasal polyps **112**: 755
Epithelial odontogenic ghost cell tumour
maxilla **108**: 269

Epithelial–myoepithelial carcinoma
nasal cavity **110**: 397
parotid gland, ear canal stenosis **110**: 493
Epstein–Barr virus infection
absence of LMP1, salivary gland neoplasms **113**: 906
BHRF1, nasopharyngeal carcinoma **111**: 1147
bilateral peritonsillar abscess obstructing airway **112**: 1186
immunoglobulins and mucosal immunity **110**: 339
retropharyngeal haematoma **110**: 1075
and T-cell lymphoma **107**: 468
Erbium: YAG laser
vs carbon dioxide laser, laryngeal surgery **107**: 908
Erythema multiforme
aminoglycosides, Stevens–Johnson syndrome **113**: 1002
Erythromycin
and ventilating tubes, otitis media with effusion **104**: 200
Ethmoid sinuses
chronic sinusitis **112**: 845
combined transfacial and neurosurgical approach **112**: 446
craniopharyngioma **112**: 403
endoscopic surgery **113**: 754
extension of masses **109**: 258
involvement in multibacillary leprosy **112**: 1038
malignant tumours **112**: 283, **112**: 446, **112**: 682
mucoceles **106**: 23
neuralgia-like symptoms, foreign body **109**: 646
Ethmoidal artery occlusion
intractable epistaxis **106**: 507
Ethmoidal surgery
risk factors, difference in height of right and left ethmoidal roofs **108**: 261
Ethmoidal transorbital foreign body 108: 441
Ethmoidal tumours
adenocarcinoma, metastatic **109**: 759
brachytherapy **107**: 115
metastasis of endometrial carcinoma causing mucocele of maxillary antrum **112**: 283
scleroma, endoscopic diagnosis and treatment **106**: 807
teratocarcinosarcoma **112**: 682
Ethmoiditis
inner canthus fistula **106**: 1076
neonate, periorbital abscess **107**: 1043
Ethnic aspects of deafness 104: 675
European symposium
cochlear implants **106**: 1109
Eustachian tube
barotitis, acoustic impedance tests **110**: 625
function
nasal packing **105**: 539
sudden hearing loss, and healthy subjects **106**: 322
tympanic membrane perforation **105**: 716
and Valsava's manoeuvre **113**: 480
ventilation scintigraphy Xe-133 gas **113**: 509
in otitis media **108**: 95
electron microscopic study **107**: 651
patency, middle ear inflation **104**: 134
patulous, radiology **104**: 291
submucosal glands, in normal and pathological temporal bones **107**: 1099
teratoma, terminology **113**: 271
valve section **109**: 486
Evidence-based medicine 111: 415
Evoked potentials
auditory, *see* Brain stem
Evolutionary theory
paranasal sinuses **106**: 214
thyroid development from fourth branchial pouch **108**: 71
Ewing's sarcoma
nasal fossa **104**: 570
retropharynx **108**: 363
Exophthalmos
following nasal tamponade **110**: 265
limited Churg–Strauss syndrome **110**: 578
and proptosis, osteosarcoma of ethmoid **110**: 676
Exostoses
external auditory canal **105**: 844
and osteomata, ear canal **108**: 106
surgery, surgical emphysema **108**: 490
Expectorated tissue
diagnosis of renal adenocarcinoma **108**: 1108
Experimental *see* Animal models
External ear *see* Ear, external
Eye colour
hearing loss, cisplatin ototoxicity **105**: 7, **109**: 926
Eye disease
orbital decompression **111**: 946
Eye protection
in ENT surgery **107**: 618
mastoid surgery **109**: 707
Eyelids
gold weights, facial palsy **105**: 471

Fabry's disease
labyrinth ossification **105**: 621
Facelift incision
modified, parotidectomy **108**: 574
Facial asymmetry
caused by maxillary antral mucocele **107**: 451
Facial destruction
granuloma **105**: 1120
Facial motor nerve
removal of vestibular schwannomas, role of magnetic resonance **109**: 394
Facial nerve
acoustic neurinoma/neuroma surgery **107**: 1119
complications to cochlear implant **110**: 881
EM pathological features, palsy of varying aetiology **104**: 294
haemangioma **111**: 858
monitoring, skull base surgery **111**: 715
primary intratemporal tumours **104**: 765
salivary gland neoplasms **113**: 938
schwannoma surgery through translabyrinthine approach **112**: 441
surgery
fibrin tissue adhesive **110**: 922
monitoring, skull base surgery **108**: 557
vascular cross-compression by VIIIth cranial nerves **106**: 436
Facial nerve injury
experimental studies **112**: 243
Facial nerve monitoring
intraoperative **108**: 551
Facial nerve palsies
acute suppurative parotitis **110**: 91
after glomus tumour embolization **107**: 963
bilateral **105**: 625
chickenpox **108**: 676
deafness and nasal obstruction in craniometaphyseal dysplasia **110**: 328
decompression of first segment of facial nerve, CT **109**: 935
delayed, following stapedectomy **104**: 611
eyelids, management **105**: 471
following glomus jugulare tumour embolization **113**: 268
hemifacial spasm **110**: 1081
herpes zoster oticus **110**: 918
human herpesvirus-6 and 7, and CMV **112**: 617
hypoglossal nerve surgery **110**: 922
lymphoepithelial cyst, parotid gland **110**: 799
magnetic resonance imaging **109**: 777
malignant otitis externa following mastoidectomy **113**: 1095
mastoid surgery **111**: 113
middle-ear surgery and varicella-zoster virus **113**: 914
neuroblastoma **110**: 151
parotid gland lipoma **110**: 93
pathological features of facial nerve, electron microscopy **104**: 294
photography **109**: 748
post-traumatic bilateral **107**: 730
pregnancy, lower motor neurone **108**: 587
Ramsay Hunt syndrome, herpesvirus **113**: 670
schwannoma **110**: 632
sequelae **112**: 429
suppurative otitis media, immunocompromised patient **109**: 755
surgery, CT scan prediction **109**: 935
teratoma, newborn **110**: 875
tuberculosis, and CT **109**: 1013
Wegener's granulomatosis **110**: 459
see also Bell's

Facial nerve schwannoma
child **110**: 1169
immunohistochemistry **110**: 632
mastoiditis **108**: 1008
Facial pain
foreign bodies **110**: 796
xylocaine test, prognostic aid for surgery in Sluder's neuralgia **109**: 193
Factitious disorders 110: 981
Factor V
Leiden mutation, internal jugular vein thrombosis **112**: 383
Fanconi's anaemia
and post-cricoid carcinoma **105**: 125
Farmer's ear
sensorineural hearing loss due to *Chlamydia psittaci* infection **111**: 855
Fasciitis
cranial, post-auricular mass **109**: 255
see also Necrotizing fasciitis
Fast neutron therapy
head and neck masses **106**: 144
Fat grafts
intracordal autologous, CT of glottis **112**: 971
myringoplasty **111**: 517
children **111**: 106
obliteration of mastoid cavities for cochlear implants **113**: 881
for unilateral recurrent laryngeal nerve paralysis **112**: 1082
Feingold syndrome
hearing loss **113**: 919
Fetal endolymphatic sac 105: 711
human, and mouse embryo, carbonic anhydrase isoenzymes **106**: 98
Fetal warfarin syndrome
airway problems **106**: 1098
Fibreoptic nasolaryngoscopy
and bronchoscopy, paediatrics **111**: 349
epistaxis **105**: 17
Fibrin glue
repair of dural defects, craniofacial resections **106**: 356
Fibrin tissue adhesive
facial nerve surgery **110**: 922
Fibroma
chondromyxoid **113**: 380
ethmoid and frontal sinuses **109**: 258
deep soft tissues of neck **112**: 503
juvenile angiofibroma **113**: 127
larynx **112**: 286
solitary
nasopharynx **105**: 213
parapharyngeal **108**: 344
sublingual gland **108**: 998
upper respiratory tract **107**: 252
see also Angiofibroma
Fibromatosis
auditory meatus **111**: 145
cemento-ossifying, petromastoid region **111**: 152
desmoid-type, parotid gland **111**: 669
head and neck **106**: 459
immunohistochemistry **113**: 486
infantile **113**: 246
myofibroblastic tonsillar tumour **111**: 880
nasal dorsum **106**: 821
parapharyngeal space **108**: 1102
thoraco-cervical **111**: 385
Fibromyxoma
ossifying, head and neck, clinicopathological and immunohistochemical study **107**: 75
Fibrosarcoma
antrochoanal, radiation injury **106**: 547
nasal cavity and paranasal sinuses **108**: 947
vocal folds, complication of radiotherapy **108**: 993
Fibrous annulus
myringoplasty **106**: 116
Fibrous dysplasia
craniofacial **105**: 662
ear canal **110**: 417
paranasal sinuses **112**: 964
temporal bone **113**: 772
Fifth *see* Trigeminal nerve
Fine needle aspiration cytology
chordoma of clivus, immunocytochemistry **108**: 426
diagnosis of tuberculous cervical lymphadenopathy **104**: 24
head and neck masses, child **106**: 755
nasal diseases **113**: 983
salivary gland lesions, head and neck clinic **107**: 1025
submandibular gland neoplasms **109**: 853
tuberculosis of thyroid gland **109**: 36
and ultrasound, parathyroid adenoma **107**: 543
Fistula
arteriovenous, and pulsatile tinnitus, occipital artery ligation **104**: 421
branchial **109**: 999, **110**: 391
excision **109**: 999
carotico–cavernous **113**: 744
following septorhinoplasty **113**: 844
chylous, nutritional support **105**: 1052
cochlear, tympanic cavity **105**: 656
ear canal and temporomandibular joint, complication of otitis externa **106**: 994
following laryngectomy, irradiation treatment **107**: 1136
foreign bodies, nasal septum **113**: 1020
inner canthus, associated with ethmoiditis **106**: 1076
management, tracheo-innominate artery fistula, using interposition pedicle flap **109**: 161
MRSA, tracheocarotid artery **113**: 689
nasal septal button insertion **113**: 823
nasal septal perforation repair **113**: 721, **113**: 728
oroantral, transantral ligation of internal maxillary artery for epistaxis **111**: 468
palatal defects **113**: 834
perilymph **105**: 270, **105**: 304, **111**: 1166
diagnostic tests **108**: 560
pharyngo-oesophageal, following surgery **109**: 1215
post-laryngectomy pharyngocutaneous **109**: 221
pyriform sinus **109**: 886
salivary megalith **109**: 767
sialo–oral, sialo–cutaneous **109**: 767
tracheoesophageal **113**: 469
creation, post laryngectomy **106**: 231
flexible endoscopy **109**: 1077
following intubation **104**: 26, **104**: 267
foreign body **110**: 685
Flaps
free forearm flap **111**: 48
head and neck surgery, scalp flap **107**: 324
Hong Kong Flap, mastoid surgery **108**: 825
jejunal free flap, invasive candidiasis **112**: 1090
jejunal patch, oral and oro-pharyngeal reconstruction **113**: 680
mastoid cavity reconstruction, pedicled musculo-fascial **106**: 124
microvascular free flaps, head and neck surgery **108**: 962
myocutaneous, and sternocleidomastoid muscle **104**: 315
myofascial, carotid arteries **109**: 1176
nasolabial, reconstruction of floor of mouth defects **107**: 320
palatal rotating, and buccal fat pad (BFP) **113**: 834
pectoralis major myocutaneous, advanced pyriform carcinoma **107**: 817
temporoparietal fascia, mastoid surgery **105**: 417
thymus pedicle flap, tracheo-innominate artery fistula **109**: 161
tracheal reconstruction, temporoparietal fascia flap, and nasal septal graft **106**: 741
Flexible nasopharyngoscopy for fish bone removal from the pharynx 106: 709
Flow cytometry
acinic cell carcinoma, major salivary glands **104**: 410
analysis, turbinates **110**: 124
analysis of DNA content in laryngeal cancer **104**: 485
head and neck carcinoma **110**: 243
Flow–volume loop analysis
partial laryngectomies by radiological method, airway obstruction **108**: 954
Fluid replacement
in children undergoing tonsillectomy **104**: 801
Fluorodeoxyglucose
FDG-PET, head and neck cancer **113**: 548
Fluoroscopy
bronchoscopic removal of foreign bodies **113**: 849

Foley catheter
epistaxis, fixation **107**: 142, **107**: 1032, **108**: 399
Follicular thyroid carcinoma
Japan **110**: 657
Food bolus impaction 111: 1158
Foramen magnum meningioma
hoarseness **104**: 715
Foreign bodies
adrenaline, expulsion of intra-nasal foreign bodies in children **110**: 559
arytenoid calcification **106**: 1089
aspiration **106**: 751
pulmonary tuberculosis **106**: 453
aural **111**: 749
bronchial compression detected by pulse oximetry **104**: 50
bronchial tree **113**: 851
bronchoscopic removal, fluoroscopy **113**: 849
button battery in nose **108**: 871
children
bronchoscopy **105**: 466
radiological diagnosis **104**: 778
dental plates, radiolucency **105**: 681
ear **111**: 749
ear canal, water used to visualize and remove **106**: 157
endobronchial tuberculous granuloma masquerading as foreign body **109**: 1192
ethmoid sinus, neuralgia-like symptoms **109**: 646
facial pain **110**: 796
flexible nasopharyngoscopy **106**: 709
frontal sinus **111**: 156
ingestion **105**: 146, **105**: 755
larynx **104**: 131, **110**: 679, **110**: 1164
management **109**: 965
maxillary sinus **104**: 718
migrating from pharynx to mediastinum **110**: 279
migration **109**: 990
MRI, aspirated peanut in bronchus **108**: 804
narcotic, throat **105**: 774
nasal, Fogarty biliary balloon catheter **108**: 758
nasal septum fistula **113**: 1020
nasendoscopy guided removal, from base of tongue and vallecula **109**: 534
oesophagus **105**: 46, **105**: 104, **105**: 591, **105**: 774, **111**: 583
bay leaf **107**: 153
complicated by lingual thyroid cyst **104**: 508
computed tomography **112**: 360
razor blade **104**: 435
respiratory symptoms in baby **106**: 556
oropharyngeal, radiographic assessment **109**: 452
osseointegrated screw **105**: 573
paranasal sinuses **109**: 1097
in parapharyngeal abscess, imaging and surgical exploration **113**: 683
pharyngeal perforation, 'pencil injury' **110**: 901
pharyngolaryngeal migration, impacted bullet in neck **106**: 1091
post-nasal space **111**: 775
pulmonary oedema **113**: 1119
safety pin (open) in larynx **108**: 254
sphenoethmoidal junction, endoscopic sinus surgery **106**: 998
superglue removal from ear canal **109**: 1219
throat
388 cases **105**: 104
migrating through the common carotid artery **110**: 793
thyroid, deglutition disorders **107**: 1057
thyroid gland and oesophagus **113**: 769
thyroid lobectomy, removal of fish bone **104**: 511
toluidine blue **113**: 909
tongue **105**: 849
tonsillitis **112**: 584
tracheoesophageal fistula **110**: 685
tracheostomy **110**: 1069, **111**: 652
broken introducer **107**: 463
equivalence **107**: 359
transethmoid transorbital **108**: 441
wooden orbital **107**: 735
Forestier's disease
ankylosing vertebral hyperostosis, cervical osteophytes **104**: 236
dysphagia, transpharyngeal approach **113**: 366
stridor **113**: 65
Formby, Myles Landseer
obituary **108**: 191
Fraser, James Graham
obituary **108**: 289
Fraser syndrome
ENT manifestations **106**: 1
Frey's syndrome
botulinum toxin **111**: 839
Frontal sinus
carcinoma, sinusitis **105**: 121
extension of masses **109**: 258
foreign bodies **111**: 156
intrusion of incisor teeth into contralateral frontal sinus following trauma **107**: 240
Lothrop procedure **111**: 637
melanoma **111**: 376
sinolith **112**: 570
surgery and MRI **109**: 1115
Frontal sinusitis
intracranial complication **104**: 645
Fronto–ethmoid mucocele
histopathology **105**: 921
Fronto–ethmoid osteoma 111: 372
Frozen section diagnosis
jugulo-tympanic paraganglioma **107**: 755
Fungal sinusitis
skull base osteitis **112**: 92
Fusariosis
maxillary sinus, immunocompetent hosts **106**: 733
Fusobacterium necrophorum
meningitis **105**: 119

G syndrome
Opitz oculo–genital–laryngeal (Opitz/BBB/G) syndrome **109**: 244
Galvanic body sway test
vs caloric test, vestibular schwannoma **113**: 118
Ganglia and ganglion neurons
arrangement and number in mammals **109**: 622
Ganglioneuroma
multiple, neck **106**: 277
parapharyngeal masses **110**: 87
Garnet Passe and Rodney Williams Memorial Foundation
lecture **110**: 717
Gastric neoplasms
adenocarcinoma, metastases to ethmoid **109**: 759
carcinoma, bilateral hearing loss **111**: 1142
surgery, node negative squamous cell carcinoma, postcricoid region **109**: 114
tonsillar metastases **110**: 291
Gastric pull-up
by eversion stripping of oesophagus **107**: 1021
hypopharyngeal carcinoma **113**: 241
Gastric tube transposition
cancer of hypopharynx and cervical oesophagus **108**: 33
laryngopharyngoesophagectomy **110**: 1072
Gastroesophageal reflux
in children **112**: 49
chronic posterior laryngitis **113**: 734
voice disorders **109**: 1195
Gastrointestinal tract
upper, endoscopy in globus syndrome **107**: 535
Gastroscopy
tracheoesophageal puncture **113**: 564
Gaucher's disease
infantile, with limited auditory brainstem response **112**: 1069
Gd MR imaging
comparison with CT and MR, adenoid cystic carcinoma **104**: 662
Gene amplification
Int-2 gene in head and neck squamous cell carcinoma **109**: 72
Gene therapy
in cystic fibrosis, maxillary sinuses **113**: 329
treatment of head and neck cancer **112**: 913
Genetic counselling
hearing loss in Waardenburg's syndrome **104**: 97
Genetic/familial conditions
aspects of deafness **104**: 675

bilateral acoustic neurofibromatosis **107**: 6
cartilage disorders, inherited degenerative, autosomal dominant **109**: 433
cerebrospinal fluid fistula, inner ear, meningitis **107**: 492
cholesteatoma **113**: 52, **113**: 841
congenital intranasal polyp, mesenchymal chondrosarcoma **106**: 1081
glossocervical fistula **108**: 519
laryngeal cleft, and tracheoesophageal fistula **113**: 469
laryngeal hypoplasia **113**: 1026
paraganglioma **105**: 376, **110**: 688
polyostotic bone disorders **105**: 80
round window absence **104**: 980
stapes suprastructure fixation **107**: 36, **113**: 798
vestibular schwannomas, gene for type 2 neurofibromatosis **109**: 830
Wegener's granulomatosis **105**: 123
see also Molecular genetics
Geniculate ganglion
neuralgia **113**: 945
Geniohyoid muscle haemangioma 111: 769
Gentamicin
and cochlear implantation, Ménière's disease **113**: 666
ototoxicity, continuous ambulatory peritoneal dialysis **107**: 681
systemic absorption **111**: 960
via peritoneal dialysis fluid, ototoxicity **105**: 222, **105**: 999
Germ cell tumours
head and neck **106**: 268
Ghost cell tumour
epithelial odontogenic, maxilla **108**: 269
Giant cell arteritis
and ulcerative colitis, associated with sensorineural deafness **104**: 889
Giant cell tumour
granuloma
concha bullosa **109**: 555
cricoid cartilage **109**: 1120
hyoid **113**: 566
malignant fibrous histiocytoma **105**: 1079
sphenoid sinus **105**: 855
temporal bone, presenting as vertigo **109**: 538
Gingival leiomyosarcoma 106: 46
Glasgow Benefit Plot
assessment of hearing results following surgery for otitis media **108**: 733
Glass ionomer cements
otological surgery **106**: 954
Glaucoma
acute angle closure glaucoma, drug-induced **113**: 140
Glial fibrillary acidic protein
pleomorphic adenoma **105**: 1057
Globus syndrome
flexible endoscopy of upper gastrointestinal tract **107**: 535
Glomus tumours
audiology **111**: 218
embolization, and facial palsy **107**: 963, **113**: 268
image processing, stereotaxic techniques **110**: 322
KTP laser assisted excision **112**: 956
MIBG scintigraphy **110**: 373
MRI **107**: 1067
multiple **106**: 538
Nd:YAG laser **107**: 236
of oropharynx **109**: 63
resection, literature review **108**: 776
scintigraphic evaluation **104**: 33, **110**: 373, **111**: 963
temporal bone carcinoma **111**: 963
Glomus tympanicum chemodectoma
radiology **108**: 607
Glossal abscess 110: 389
Glossopharyngeal neuralgia
surgery via pharyngeal approach **104**: 12
Glottectomy
functional results **111**: 833
Glottic
see also Supraglottic
Glottic bar
intubation **104**: 727
Glottic masses
carcinoma *in situ*, radiotherapy, clinical course vs response **107**: 1014
post-operative irradiation, and neck dissection **108**: 26
T_3 N_0 M_0 surgery and radiotherapy **107**: 912
Glottis
angiocentric T-cell lymphoma **113**: 263
cricohyoepiglottopexy, long-term results **113**: 532
CT after intracordal autologous fat injection **112**: 971
reconstruction by implant of homologous laryngeal cartilages **107**: 427
supraglottis and subglottis, lectin histochemistry, hamster **111**: 441
Glottitis
caused by *Streptococcus sanguis* **104**: 430
Glycerine
and ichthammol, antibacterials **110**: 319
Glycoconjugates
lectins, fetal endolymphatic sac **105**: 711
Glycogen-rich clear cell carcinoma
tongue **108**: 716
Glycoproteins
mucus, in larynges of victims of sudden infant death syndrome **109**: 403
Gogarty, Oliver St John 111: 15
Goitre
cervical and mediastinal, CT imaging **106**: 65
retropharyngeal mass **113**: 170
thyroid, management **109**: 892
Goode T-Tube
vs Armstrong tube, chronic otitis media with effusion **104**: 608
Gorlin–Goltz syndrome 111: 286
auditory canal, basal cell carcinoma **111**: 850
Gradenigo syndrome
middle ear infection and sixth nerve palsy **110**: 872
Grafts
homologous costal cartilage implants **106**: 511
reconstruction, with free forearm flap **111**: 48
temporalis fascia **111**: 707
and temporoparietal, sandwich **111**: 435
tragal cartilage
inferior turbinate mucoperiosteal sandwich, nasal septal perforations **106**: 893
nasal septal perforation **111**: 435
see also Bone grafts; Flaps
Graham Fraser lecture 111: 907
Grand mal epilepsy
cochlear implantation **112**: 567
Granular cell tumour
larynx **104**: 159, **112**: 83, **112**: 373
eight-year-old girl **107**: 940
Granuloma
cholesterol, petrous temporal bone **106**: 465
complications of stapedectomy **110**: 185
facial destruction **105**: 1120
giant cell
cricoid cartilage **109**: 1120
reparative, of concha bullosa **109**: 555
lethal midline **112**: 307
nasal mucosa, Kaposi's sarcoma **112**: 280
plasma cell
laryngeal pseudotumour **109**: 142
maxillary sinuses **108**: 357
supraglottis **109**: 895
post-surgical necrotizing palisading, nose **107**: 656
respiratory tract, masquerading as foreign body aspiration **109**: 1192
teflon injection, vocal folds **109**: 1184
Thorotrast **104**: 355
topical inhalant steroids **113**: 427
see also Wegener's granulomatosis
Granulomatous cutaneous T-cell lymphoma
neck **106**: 563
Granulomatous myringitis 112: 150
Graves' disease
recurrent frontal sinusitis, orbital decompression **110**: 670
Greenlandic Inuits
otitis media, study of past and present **110**: 1114
Grisel's syndrome
following otolaryngological diseases and procedures **109**: 1005

Grommets *see* Ventilation tubes
Groningen valve prosthesis
failure **106**: 521
Sheffield **106**: 154
Groote Schuur hospital
classification of orbital complications of sinusitis **111**: 719
Gunshot injuries
temporal bone **112**: 929

Haemangioma
capillary, parotid **111**: 588
cervical lymph node **104**: 513
facial nerve **111**: 858
fluctuating macroglossia **109**: 665
geniohyoid muscle **111**: 769
hypopharynx, with numerous phleboliths **104**: 262
intramuscular **112**: 1181, **112**: 1199
maxillary sinus **111**: 638
nasal **111**: 941
nasal bone **105**: 389
parotid, MRI **108**: 892
pharyngo-oesophageal **113**: 172
subglottic **112**: 765
venous, neck and mediastinum **105**: 386
Haemangiopericytoma
glomus tumour of oropharynx **109**: 63
middle ear **109**: 977, **113**: 911
nasal **105**: 593, **113**: 199
parotid gland **106**: 659
salivary gland **107**: 1159
temporal bone **104**: 998
Haemangiosarcoma
maxillary antrum **104**: 831
Haematemesis
and melaena, infectious mononucleosis **109**: 335
Haematological tests
prior to tonsillectomy **107**: 205
Haematoma
alar **113**: 1104
Epstein-Barr virus infection **110**: 1075
external ear **110**: 862
life-threatening cervico-mediastinal, after carotid sinus massage **105**: 381
parotid gland **110**: 590
retropharyngeal, Epstein-Barr virus infection **110**: 1075
traumatic, soft palate **105**: 1116
Haemodialysis
endolymphatic hydrops **104**: 641
Haemoglobin
estimation in paediatric ENT surgery **107**: 1146
Haemophilia
girl, adenoidectomy **105**: 957
pseudotumour **113**: 924
tonsillectomy **110**: 947
Haemophilus influenzae
and group A Streptococci, recurrent tonsillitis **105**: 439
Haemorrhage
bleeding from ear **107**: 137
idiopathic spontaneous tonsillar **107**: 44
upper jugular **104**: 976
upper respiratory tract, complication of amyloidosis of larynx **107**: 51
Haemorrhagic telangiectasia
argon laser for epistaxis **111**: 34
epithelial sheets, tissue culture **107**: 510
Young's procedure, epistaxis **108**: 754
Haemostasis
tonsillectomy **109**: 206
bismuth subgallate **109**: 203
ligatures vs diathermy **107**: 711
Hairy polyp
oropharynx **110**: 288
tonsil **110**: 101
Hamartoma
larynx, neonatal respiratory distress **111**: 166
leiomyomatous, posterior tongue **109**: 1190
oropharynx **110**: 480
tongue **107**: 363
tonsillar polyp **105**: 1089
Hamartoma-like mass
pigmented naevus and hyperplastic salivary gland **111**: 296
Hamartomatous polyp
benign, palatine tonsil **107**: 1074
Hamartomatous thymoma
ectopic **107**: 155
Hampshire schools
otitis media, epidemiology **108**: 930
Hand preference
jugular foramen dominance **111**: 290
Hashimoto's thyroiditis
and lymphoma **109**: 781
Head bandages
following otoplasty **108**: 410
pressure exerted **107**: 1110
Head dressings
middle ear surgery **107**: 17
Head injury
audiology **104**: 927
auditory evoked potentials **104**: 191
optic nerve, transethmoid decompression **105**: 205
post-traumatic cholesteatoma **105**: 367
temporal bone findings **104**: 986
tongue paralysis **109**: 770
Head and neck infections
herpes **113**: 573
HIV infection and AIDS **107**: 133
Head and neck masses 109: 883
13-cis-retinoic acid and interferon-α **110**: 857
abscess
Salmonella **111**: 489
Streptococcus bovis, undiagnosed colon cancer **111**: 666
thoracic malignancy **112**: 891
and ageing, prospective study **104**: 634
amplification of Int-2 gene **109**: 72
angiosarcoma **111**: 175
aortic aneurysm presenting as a recurrent neck swelling **109**: 163
audiometry **109**: 744
bronchogenic cyst **112**: 893
Castleman's disease **110**: 896
cervical lymph node metastatic patterns **110**: 937
chemotherapy, OK-432 **110**: 449
children, prognosis **104**: 544
in chronic lymphocytic leukaemia **110**: 694
cisplatin–albumin complex **106**: 832
combination chemotherapy vs surgery with/without radiotherapy, laryngeal preservation **107**: 211
combined therapy **106**: 412
cotinine, marker for smoking **105**: 1036
cutaneous melanoma, parotid metastases **104**: 350
day-case clinic **112**: 1061
electron microsopy **106**: 403
endoscopic ultrasound-guided brachytherapy **113**: 41
extension of naso-ethmoid schwannoma **105**: 578
fast neutron therapy **106**: 144
FDG-PET **113**: 548
fibroma, solitary **112**: 503
fibromatosis **106**: 459
fibrous histiocytoma **105**: 1079
fine needle aspiration cytology, child **106**: 755
ganglioneuroma **110**: 87
gene therapy **112**: 913
germ cell tumours **106**: 268
granulomatous cutaneous T-cell lymphoma **106**: 563
and heterotopia **113**: 299
immunosuppressive acidic protein and other parameters **105**: 939
intramuscular haemangioma **112**: 1199
intratemporal tumours, facial nerve **104**: 765
Kikuchi's disease (histiocytic necrotizing lymphadenitis) **112**: 898
laryngeal carcinoma, direct extension to skin **104**: 824
leucine aminopeptidase **108**: 660
lymphangioma **110**: 586
maxillary sinus carcinoma, T-classification and direction of tumour spread **106**: 804
metastases **107**: 1171, **110**: 353, **111**: 454

minimizing complications **113**: 101
myoepithelioma of parotid gland **109**: 995
myxoid liposarcoma **113**: 179
neuroendocrine tumours **104**: 504
non-Hodgkin's lymphoma **104**: 972, **110**: 161
oncogenic osteomalacia **112**: 389
oropharyngeal flora, radiotherapy effects **107**: 222
ossifying fibromyxoma **107**: 75
paediatrics **111**: 541
paraganglioma, multiple **107**: 538
photodynamic therapy **109**: 1072
primary radiotherapy **112**: 132
psychological morbidity **113**: 349
quality of life assessment **109**: 1029
radiation-induced **109**: 346
radiotherapy
mucocele of sphenoid sinus **105**: 959
uni- and multivariate analysis of indications **107**: 437
rhabdomyosarcoma, clinicopathological and DNA ploidy study **107**: 716
solitary fibrous tumour of infratemporal fossa **110**: 594
squamous cell carcinoma **104**: 631, **111**: 43, **111**: 531
CDDP-5FU combination therapy **107**: 924
cellular proliferation markers **108**: 859
neck abscess or cellulitis **110**: 893
postcricoid region **109**: 114
stage IV **106**: 234
staging, CT and US **113**: 152
technetium-99m(v) DMSA **104**: 783
thyroid scanning **109**: 674
trismus **107**: 1017
CT and PET **112**: 303
tumefactive fibroinflammatory lesions **104**: 797
see also named lesions; Neck
Head and neck surgery **104**: 529, **105**: 1121
blood transfusion policy, audit **104**: 28
cefotaxime prophylaxis, one-day *vs* seven-day therapy **107**: 30
glossopharyngeal neuralgia, via pharyngeal approach **104**: 12
Indermil **111**: 536
MRSA wound infection **111**: 874
PET **112**: 125
prophylactic antibiotics **106**: 409, **106**: 621
prophylaxis of venous thromboembolism **111**: 845
quality of life **106**: 238
scalp flap **107**: 324
trauma, and neoplasms **109**: 126
vertigo **104**: 849
Zenker's diverticulum **104**: 312
Hearing acquisition
bilingual, following cochlear implantation **110**: 776
speech recognition **105**: 249
Hearing aids
battery life **111**: 814
bone conduction subcutaneous (Xomed Audiant) **104**: 534
bone-anchored
Birmingham programme (1988–1995) *Supplement No. 21*, Vol. 110
Saethre–Chotzen syndrome **110**: 952
clinics **107**: 329
direct referral **105**: 825
evaluation of direct referral to audiology departments **108**: 120
otitis media with effusion **113**: 314
piezoelectric ceramic **110**: 1090
prescription for elderly patients, GP views **106**: 963
randomised studies, patient preference **105**: 405
sensorineural hearing loss **110**: 362
solar recharging system **108**: 768
subcutaneous implantable bone conduction (Xomed Audiant) **105**: 828
use by patients with closed mastoid cavity **105**: 174
see also Cochlear implants
Hearing conservation
acoustic neuroma, surgery via posterior fossa **104**: 463
benefit evaluation, middle ear surgery **107**: 4
Hearing loss
and aniridia, inherited **104**: 419
audiology clinic **105**: 534
auditory brainstem responses **111**: 223
bilateral
gastric carcinoma **111**: 1142
pure-tone audiometry **110**: 727
temporal bone abnormalities **111**: 117
bilateral conductive **104**: 560
lichen planus **112**: 365
bilateral sudden, and acute acquired toxoplasmosis **105**: 115
blood sugar levels in Ménière's disease **107**: 620
cerebellar masses **108**: 584
children, delay in detection **111**: 1018
Chlamydia psittaci infection **111**: 855
cholesteatoma, congenital **113**: 841
cisplatin in children **109**: 926
cochlear function, auditory nerve agenesis **113**: 1008
Coffin–Lowry syndrome, labyrinthine anomaly **108**: 147
conductive
diagnosis by tympanoscopy **112**: 154
multiple abnormalities **110**: 1057
with multiple abnormalities **110**: 1057
Pierre Robin syndrome **110**: 830
Saethre–Chotzen syndrome **110**: 952
congenital conductive, ossification of stapedius tendon **105**: 763
cranio-metaphyseal dysplasia **104**: 807
diabetics **107**: 179
and ear pathology, Nepal **107**: 395
electrocochleographic investigation of endolymphatic hydrops **108**: 125
epidemiology, Sichuan, China **107**: 990
ethnic aspects **104**: 675
Eustachian tube function **106**: 322
and familial salivary gland insensitivity to aldosterone **104**: 956
Feingold syndrome **113**: 919
functional **109**: 1085
in haemoglobin sickle cell disease **107**: 831
hepatitis C virus (HCV) infection **112**: 962
historical medicine **113**: 795
human herpesvirus-6 and 7 **112**: 617
hyperphosphatasia **113**: 158
Jewish children of Jerusalem **104**: 675
as lateralising indicator in surgical management of vertigo **105**: 618
localization and specificity of guinea pig inner ear antigenic epitopes **109**: 19
Lyme disease **111**: 562
MELAS syndrome **111**: 279
motorcyclists **109**: 599
noise-induced
mechanisms **112**: 1154
vs Ménière's disease, auditory thresholds **107**: 780
non-explosive blast injury **111**: 1137
pigmentary disturbances, Waardenburg syndrome Type II **109**: 96
post-irradiation **113**: 815
post-operative
low cerebrospinal fluid pressure **108**: 637
size of spinal needle, epidural anaesthesia **106**: 783
pre-auricular sinus, external ear anomaly and commissural lip pits syndrome **108**: 13
prevention, WHO role **111**: 699
radiotherapy for nasopharyngeal carcinoma **110**: 121
residual hearing, in anacusis **113**: 714
restoration in neurofibromatosis type-2 **109**: 385
sarcoidosis **109**: 1089
Saudi children
epidemiological study **108**: 294
renal tubular acidosis **109**: 930
sensorineural **109**: 930
aetiology, internal auditory meatus **113**: 1015
Arnold–Chiari malformation **110**: 1060
cochear implant in siderosis **110**: 1151
enlarged jugular fossa **109**: 350
epidemiology, sickle cell anaemia, UK **107**: 790
following bacterial meningitis **113**: 1011
following non-otologic surgery **112**: 769
and hormone replacement therapy **110**: 1148
Langerhans' cell histiocytosis **113**: 1098
and Marinesco-Sjögren syndrome **105**: 210
metastatic prostatic carcinoma **107**: 933
misdiagnosis of hearing loss due to ear canal collapse **110**: 561

Hearing loss (continued)
multiple sclerosis, audiometry, evoked response **110**: 252
neurobrucellosis **107**: 1034
oculopharyngeal myopathy **110**: 567
and pyoderma gangrenosum **108**: 671
relapsing polychondritis, as inner ear involvement **110**: 154
rheumatoid arthritis **109**: 713
secondary to otitis media, damage to stria vascularis by endotoxins **108**: 310
sudden deafness, diabetes mellitus **110**: 59
ulcerative colitis, and giant cell arteritis **104**: 889
in sickle cell disease **105**: 653
siderosis of CNS **111**: 60
and spiral ligament hyalinization, cochlear otosclerosis **104**: 952
stapes surgery **113**: 417
sudden, complication of non-otologic surgery **104**: 711
Susac's syndrome **111**: 1072
and typhus fever **107**: 275
ulcerative colitis **111**: 277
unilateral
acoustic neuroma **107**: 230
in chronic ear disease, surgery **106**: 793
osteoma of internal auditory canal **106**: 905
rhabdomyoma in child **109**: 1186
unilateral sensorineural, solitary plasmacytoma **113**: 164
verbal auditory agnosia with focal EEG abnormality **109**: 429
and Waardenburg's syndrome, genetic counselling **104**: 97
weapons noise exposure, investigating asymmetrical loss **109**: 291
white noise generators for tinnitus, retraining therapy **111**: 810
Hearing preservation
acoustic neuroma surgery **109**: 374
in acoustic schwannoma surgery **106**: 500
labyrinthectomy for resection of giant cholesteatoma with middle fossa extension **112**: 472
Hearing restoration
neurofibromatosis **109**: 385
Hearing tests
adenoids in school-aged children **109**: 196
Hearing thresholds
in insulin-dependent diabetic patients **108**: 837
Heart and heart-lung transplant recipients
lymphoproliferative oropharyngeal lesions **104**: 720
Helical CT
incudostapedial joint, 3-D reconstruction **113**: 707
Hemifacial spasm
carotid artery compression of the facial nerve **110**: 1081
Hepatitis C virus (HCV) infection
autoimmune–microvascular pathogenesis **112**: 962
Hepatocellular carcinoma
metastasis to sphenoid sinus **108**: 503
Herpesviruses
head and neck **113**: 573
herpes simplex infection, neonatal stridor **112**: 1192
HPV-6 and HPV-7, idiopathic facial nerve palsy or sudden deafness **112**: 617
hybridization **113**: 906
Ramsay Hunt syndrome **113**: 670
RNA and LMP1 EBV, salivary gland neoplasms **113**: 906
varicella, facial nerve palsies **108**: 676
varicella-zoster oticus, facial palsy **110**: 918, **113**: 914
Hibernoma
parotid region **107**: 257
High frequency jet ventilation 108: 23
High-resolution computed tomography in evaluation of cochlear patency in implant candidates
a comparison with surgical findings **108**: 743
Histamine H_1 receptor blockade
nasal airway resistance **109**: 841
Histiocytic necrotizing lymphadenitis
Kikuchi's disease of neck **112**: 898
Histiocytoma
benign
external auditory meatus **110**: 98
larynx **110**: 474
fibrous
larynx **112**: 1205
mouth **109**: 680
fibrous malignant **109**: 680
giant cell variant **105**: 1079
larynx **105**: 130
larynx **112**: 1205
Histiocytosis
dysphagia, hoarseness and stridor **107**: 1061
Rosai–Dorfman disease, nasal manifestations **113**: 275
sensorineural hearing loss **113**: 1098
sinus, with massive lymphadenopathy (Rosai–Dorfman disease), subglottic narrowing **106**: 61
Histology
subcutaneous tissue reaction to synthetic auditory ossicle (Apaceram) in rats **109**: 14
Histoplasmosis
oral cavity, oropharynx and larynx **107**: 58
Historical Articles
Adam Politzer's influence on otology **110**: 823
Annandale's case **109**: 369
Babington, Benjamin Guy, and his mirror **112**: 235
Birmingham Mummy **109**: 273
British Society for the History of ENT **110**: 297, **111**: 397, **111**: 1207, **113**: 282
Brown, Alfred Gardiner (1838-1882) **113**: 304
Byzantine texts (324–1453AD) **112**: 25
century of ENT radiology **110**: 5
Crown Prince Frederick of Prussia: Suez and syphilis **109**: 479
Draffin and his rods **106**: 1035
ear dysplasia after Mondini **108**: 461
Emperor who smoked a pipe **109**: 1
ENT in Ancient Egypt
Part I **106**: 677
Part II **106**: 773
Part III **106**: 863
epidemic typhus fever and hearing loss **107**: 275
Gogarty, Oliver St John **111**: 15
Gradenigo, Giuseppe **111**: 418
hearing loss **113**: 795
management of epistaxis **112**: 331
Ménière's disease **110**: 1107
Midlands Institute of Otology, and W.S. Adams **111**: 1122
Minoan era, otorhinolaryngological diseases **107**: 879
ORL-HNS and associated specialities, ENT in 20thC **113**: 1060
otosclerosis exostoses in ancient Europeans **107**: 489
percutaneous tracheotomy **110**: 723
St Cadoc, healing **104**: 1
tracheotomy, 1940–55 **113**: 624
traditional treatments of hearing problems in Brittany and Wales **107**: 391
Watson-Williams, Patrick **105**: 1
Yearsley, James **105**: 249
History of Royal National Throat, Nose and Ear Hospital 1874–1982, Suppl. 22, Vol. 112
HIV infection and AIDS
adenoidal hypertrophy **104**: 58
disproportion of minor T-cell subsets, Japanese patients with Wegener's granulomatosis **106**: 133
epiglottitis treated with oral fluconazole **109**: 337
head and neck manifestations **107**: 133
Kaposi's sarcoma, larynx **110**: 1034
laryngeal aspergillosis **112**: 488
leishmaniasis **108**: 1086, **108**: 1089
malignant otitis externa **110**: 770
mass in postnasal space **110**: 787
mycobacterium marches back **109**: 5
nasopharyngeal carcinoma **107**: 149
nasopharyngeal cyst simulating Kaposi's sarcoma **104**: 498
necrotizing external otitis, *Aspergillus fumigatus* **112**: 98
needle myringotomy **112**: 865
non-Hodgkin's lymphoma **112**: 77, **112**: 982
external auditory canal **109**: 751
otolaryngology **111**: 209
Pneumocystis carinii infection **113**: 555
pseudomonas subglottic stenosis **111**: 70
Sjögren-like syndrome **109**: 1113
stridor **109**: 1197
Hoarseness
in children, and gastroesophageal reflux **112**: 49

sole presenting symptom of foramen magnum meningioma **104**: 715
and stridor, histiocytosis **107**: 1061
systemic lupus erythematosus **110**: 478
Hodgkin's disease
cutaneous presentation **113**: 765
middle ear and mastoid **110**: 869
nasopharynx **112**: 103
secondary to recurrent adenoid cystic carcinoma, parotid gland **105**: 224
Holden's apparatus
tissue volume estimation **109**: 1181
Hong Kong
Conference Report **106**: 1105
otitis media, epidemiology **111**: 804
Hong Kong Flap
mastoid surgery **108**: 825
Hormone replacement therapy
sudden hearing loss **110**: 1148
Horner's syndrome
cervical sympathetic chain schwannoma **111**: 493
Human herpesviruses (HHV-6 and HHV-7)
idiopathic facial nerve palsy or sudden deafness **112**: 617
Human papillomavirus
and carcinoma of laryngopharynx **105**: 288
normal larynx **108**: 319
Hunter's syndrome
failure to control airway **112**: 380
Hurthle cell tumour
metastases causing airway obstruction **107**: 957
Hydatid cyst
echinococcosis **108**: 601
pterygopalatine-infratemporal fossa **110**: 978
Hydralazine-induced lupus
and vocal fold paralysis **112**: 875
Hydrocolloidal dressing
repair of tympanic membrane **109**: 1041
Hydrops
endolymphatic sac, electrocochleography **108**: 125
haemodialysis **104**: 641
Hydroxyapatites
subcutaneous tissue reaction (Apaceram), animal models **109**: 14, **111**: 702
5-Hydroxytryptamine (5-HT)
dysfunction, central hyperacusis **109**: 915
Hyoid bone
anterior cervical pain syndromes, treatment with triamcinolone acetonide **109**: 49
chondrosarcoma **106**: 273, **107**: 642
fractures **105**: 232
giant cell tumour **113**: 566
mass, presenting with cervical nodal metastasis **107**: 967
noise **109**: 1217
plasmacytoma **108**: 604
Hyoid syndrome
a pain in neck **108**: 855
Hyperacusis
5-hydroxytryptamine (5-HT) dysfunction **109**: 915
Williams syndrome **108**: 494
Hypercalcaemia
and diabetes insipidus, secondary to nasopharyngeal carcinoma **104**: 43
giant parathyroid adenoma, power Doppler **112**: 796
Hyperparathyroidism
adenoma **110**: 602
chronic renal failure, subtotal parathyroidectomy **105**: 562
Hyperphosphatasia
hearing loss **113**: 158
Hypersensitivity
submandibular salivary disease: proposed allergic aetiology **109**: 66
Hypnotherapy
tinnitus, counselling? **110**: 117
Hypochlorite disinfectants
carcinoma of external ear **113**: 1004
Hypoglossal nerve palsies
radiation-induced **105**: 44
surgery **110**: 922
Hypoglossal neurilemmoma 107: 953
extradural, extended posterolateral approach **112**: 1052
Hypoparathyroidism
after treatment of laryngopharyngeal carcinoma **112**: 1058
Hypopharyngeal defect closure
total laryngectomy **111**: 1060
Hypopharyngeal diverticula
autosuture GIA gun **107**: 723
simultaneous **107**: 49
stapling **104**: 553
Hypopharyngeal haemorrhage from carotid artery 109: 889
Hypopharyngeal masses
adenosquamous carcinoma **105**: 678
age and sex incidence, upper Egypt **109**: 737
angiocentric T-cell lymphoma **113**: 263
angiosarcoma **108**: 905
carcinoma
cyclin D1 expression **112**: 552
lymph node dissection **112**: 438
cavernous haemangioma **104**: 262
gastric pull-up operation **113**: 241
gastric tube transposition **108**: 33
inverted papilloma **104**: 432
lipoma, pre-operative diagnosis and transoral resection **108**: 174
liposarcoma **112**: 880
reconstructive surgery **113**: 145
review of literature **109**: 353
synovial cell sarcoma **106**: 285
Hypopharyngeal visualization
Valsalva manoeuvre **109**: 863
Hypophysectomy
transphenoidal **109**: 956
Hyposmia
intracranial tumour **113**: 750
intranasal steroids **110**: 132
Hypothyroidism
acquired, temporal bone findings **105**: 886

Ichthammol
antibacterial action **110**: 319
Idiopathic midline destructive disease (IMDD) 112: 307
Image cytometry
tongue and tonsil squamous cell carcinoma **110**: 237
Image processing
computer-assisted, wound healing of nasal and oesophageal mucosa **110**: 1017
otolaryngology, stereotaxic techniques **110**: 322
Immunoblotting
localization and specificity of guinea pig inner ear antigenic epitopes **109**: 19
Immunocompromised child
airway obstruction, candidiasis **106**: 168
Immunoglobulins
IgA
and chronic granular pharyngitis **107**: 532
and IgG-coated bacteria, chronically discharging ears **105**: 515
IgE decapeptide, nasal polyp fluid **110**: 225
IgG, planum semilunatum of guinea pig **106**: 93
mucosal immunity, infectious mononucleosis **110**: 339
for peritonsillar abscesses **112**: 634, **113**: 759
Immunohistochemistry
aspiration cytology of chordoma of clivus **108**: 426
expression activated by tactile stimulation on laryngeal vestibulum in cat's lower brain stem **109**: 39
facial nerve schwannoma **110**: 632
fibromatosis **113**: 486
infants, fine needle aspiration **113**: 581
Ki-67, application to salivary gland tumours **106**: 35
laryngeal neoplasms **110**: 440
mast cells in perennial allergic rhinitis **110**: 929
non-Hodgkin's lymphoma **105**: 445
papilloma virus, carcinoma of larynx **110**: 742
paraganglioma, parathyroid gland **110**: 196
pleomorphic adenoma **105**: 1057
differential diagnosis **105**: 1057
T-cell-rich histiocyte-rich B-cell lymphoma, parotid gland **110**: 811
Immunopathology
olfactory mucosa, following injury to olfactory bulb **104**: 959

Immunophenotypes
palatal tonsil lymphocytes, Cowden's disease **106**: 640
Immunosuppression
facial paralysis, suppurative otitis media **109**: 755
Immunosuppressive acidic protein
head and neck cancer **105**: 939
Implantation metastases
following percutaneous endoscopic gastrostomy **107**: 946
Implants
antimicrobial release, necrotising otitis externa **105**: 252
***In situ* hybridization**
nasopharyngeal masses **106**: 345
Incudostapedial joint
3-D reconstruction **113**: 707
Incus
lesions, tripod allograft in reconstruction **108**: 206
necrosis, chorda tympani nerve **106**: 252
repair **109**: 1048
transposition, tympanoplasty **106**: 607
Indermil (n-butyl cyanoacrylate)
otorhinolaryngology and head and neck surgery **111**: 536
India
epidemiology, variation in mastoid air cell system **104**: 603
Ineraid multichannel cochlear implant 107: 673
Infant pacifiers
bacterial colonization **111**: 614
Infants
melanotic neuroectodermal tumour **107**: 1045
sudden unexpected death
laryngeal morphology **105**: 646
mucus glycoproteins **109**: 403
temporal bone malakoplakia **105**: 568
see also Neonates
Infectious mononucleosis
bilateral peritonsillar abscess obstructing airway **112**: 1186
cervical abscess **104**: 358
complicated by lingual tonsillitis **104**: 651
haematemesis and melaena **109**: 335
Inflammation
severe chronic, mucous membranes, chromium exposure **108**: 591
Information leaflets
rhinitis clinic **105**: 282
Informed consent 110: 10
patient's attitudes **107**: 775
structured interview, assessment **106**: 420
Infra-red coagulation
bleeding mucosal telangiectasia **106**: 992
Infralabyrinthine approach
vestibular neurectomy **106**: 780
Infratemporal fossa
solitary fibrous tumour **110**: 594
Inner ear
diabetic microangiopathy **113**: 13
post-natal bone growth in dog **111**: 23
rheumatoid arthritis **109**: 713
see also Cochlear implantation
Inner ear tumours
schwannoma **111**: 877
vestibular tumours **111**: 709
Instrumentation
'Darling' elbow rest, endoscopic sinus surgery **110**: 360
nasopharynx **110**: 1055
Intensive care
post intubation laryngeal sequelae **109**: 313
Intensive care unit
post-intubation laryngeal sequelae **109**: 313
Inter-arytenoid glottic bar
following intubation **104**: 727
Interferon-a
laryngeal papillomatosis, Cuban programme **111**: 134
Internal carotid artery
pseudoaneurysm **105**: 588
spontaneous dissection **104**: 491
Internal jugular vein blowout complicating head and neck surgery 108: 423
Internet
otolaryngologists **112**: 854
Intestinal features
pharyngeal adenocarcinoma **104**: 900
Intra-osseous osteosarcoma
mandible **104**: 335
Intracordal fat injection
autologous, CT of glottis **112**: 971
treatment in recurrent laryngeal nerve paralysis **112**: 1082
Intracranial abscess
otogenic, risks **104**: 468
Intracranial aneurysm
superficial siderosis **109**: 549
Intracranial complications
ear and sinus surgery, role for cefotaxime **107**: 1005
frontal sinusitis, silent **104**: 645
Intracranial infection
complicated suppurative sinusitis **110**: 673
Intracranial neoplasms
naso-ethmoid schwannoma **105**: 578
Intralaryngeal ganglia
arrangement and number **109**: 622
Intralingual lipoma
spindle-cell variant **113**: 587
Intramuscular haemangioma 112: 1181, **112**: 1199
Intranasal adhesions
recurrence, Wegener's granulomatosis **104**: 426
Intranasal button battery causing septal perforation
a case report **108**: 589
Intranasal ipratropium bromide 104: 123
Intraoperative ultrasound
drainage of parotid abscess **112**: 1098
Intravenous hyperalimentation
pharyngitis **108**: 159
Intubation *see* Tracheal intubation
Intubation granuloma
topical inhalant steroids **113**: 427
Ionomeric cement
closure of petrous apex, temporal bone **108**: 202
otological surgery **106**: 954, **111**: 1130, **112**: 344
Iontophoresis
vs EMLA cream, tympanic membrane anaesthesia **104**: 195
Ipratropium bromide
intranasal, long-term safety **104**: 123
Iraq
otomycosis **104**: 387
Iris
colour, and ototoxicity of cis-platinum **105**: 7
pigmentation, hearing loss, cisplatin ototoxicity **109**: 926
Iron deficiency
paediatric inpatients **105**: 1021
Irrigation
maxillary sinus **110**: 763
temporal bone surgery **113**: 740
tympanic membrane rupture **109**: 1036
Isolated agenesis of mastoid antrum 108: 497
Isshiki type III thyroplasty
evaluation in mutational voice disorders **113**: 31

Japan
4th International Conference on cholesteatoma and mastoid surgery, Niigata, Japan **106**: 1107
Jejunal patch flaps
invasive candidiasis **112**: 1090
oral and oro-pharyngeal reconstruction **113**: 680
pharyngeal reconstruction **105**: 556
surgery, treatment of node negative squamous cell carcinoma, postcricoid region **109**: 114
Jewish population of Jerusalem
childhood deafness **104**: 675
Jobson, Patrick Hunter
obituary **112**: 1009
Jordan
nasopharyngeal carcinoma **105**: 432
epidemiology **113**: 422
Jugular bulb
high, in ear surgery, review of literature **108**: 772
lateral skull base surgery **111**: 333
position, influence of race **109**: 610

Jugular bulb vein
obstruction of approach to intracanalicular schwannoma **112**: 772
Jugular foramen
dominance, and hand preference **111**: 290
enlarged, sensorineural hearing loss **109**: 350
shape, and otological disorder **111**: 1027
surgery, dysphagia **110**: 144
Jugular haemorrhage 104: 976
Jugular vein
internal, ligation, in venous hum tinnitus **107**: 1037
malignant otitis externa following mastoidectomy **113**: 1095
nasopharyngeal carcinoma **110**: 987
phlebectasia **108**: 352, **113**: 858
Jugular vein ectasia
bilateral internal **108**: 263
Jugular vein thrombosis
aneurysm as hard neck mass **110**: 179
factor V Leiden mutation **112**: 383
salmonella neck abscess **105**: 966, **113**: 1122
spontaneous **112**: 888
Trousseau's syndrome **110**: 1166
Jugulo-tympanic paraganglioma
frozen section diagnosis **107**: 755
Juvenile papillomatosis
aggressive, involving total respiratory tract **112**: 1101
ribavirin **107**: 423

Kallman's syndrome 106: 530
Kaposi's sarcoma
laryngeal masses in patients with AIDS **110**: 1034
nasopharyngeal cyst simulating **104**: 498
pyogenic granuloma of nasal mucosa **112**: 280
Kawasaki disease 104: 37
acute ENT admission **104**: 581
tonsillar abscesses **111**: 73
Kenya
nose and maxillary sinus tumours, epidemiology **106**: 337
Keratitis, ichthyosis and deafness syndrome
cochlear implant extrusion **111**: 465
Keratoacanthoma
nasal vestibule **105**: 306
Keratosis
pachyonychia congenita syndrome **110**: 1145
Khat
and oral cancer **105**: 643
Ki67
progression from low-grade dysplasia to laryngeal carcinoma **112**: 455
Kikuchi–Fujimoto disease 108: 1001
vs tuberculosis **113**: 82
Kikuchi's disease
neck, histiocytic necrotizing lymphadenitis **112**: 898
necrotising lymphadenitis **105**: 496
Kimura's disease 111: 389
angiolymphoid hyperplasia **110**: 1084
review of literature **108**: 1005
Kramer vs Wilde
ideological debate **104**: 381
KTP-532 laser *see* Laser surgery

Labyrinth
acute failure **112**: 193
anomaly, sensorineural deafness, Coffin–Lowry syndrome **108**: 147
cochlear fistula **105**: 656
dysplasia, anacusis, residual hearing **113**: 714
middle ear effusion effect **105**: 987
ossification, pathology **105**: 621
schwannoma **105**: 659
semicircular canal, non-ampullary plugging **105**: 901
Labyrinthectomy
and cochlear implantation, Ménière's disease **113**: 666
Ménière's disease **110**: 216
promontory stimulation **105**: 729
relief of tinnitus **110**: 57
resection of giant cholesteatoma with middle fossa extension, hearing preservation **112**: 472
Labyrinthitis
suppuration, anaerobic bacteria **108**: 413
syphilitic **109**: 719
systemic *Candida albicans* infection in ageing mice **110**: 13
Lacrimal sac
non-Hodgkin's lymphoma, and pansinusitis **112**: 969
Landau–Kleffner syndrome
acquired aphasia without deafness **107**: 623
Langerhans' cell histiocytosis
sensorineural hearing loss **113**: 1098
Language development
recurrent acute otitis media during 0–3 years, follow-up from 0–7 years **107**: 407
Laparotomy
tracheoesophageal puncture **113**: 564
Lappish people
otalgia **104**: 109
Large vestibular aqueduct syndrome
and stapes fixation **108**: 989
Laryngeal
see also Larynx
Laryngeal amyloidosis 104: 147
with laryngocele **113**: 361
Laryngeal callus
neck masses **108**: 354
Laryngeal cartilages
arytenoidectomy **105**: 545
glottic reconstruction by implant **107**: 427
high tracheostomy **110**: 1003
radionecrosis, candidiasis **110**: 789
Laryngeal closure
level of false cord, treatment of aspiration **107**: 826
Laryngeal Crohn's disease 108: 596
Laryngeal cysts
management **104**: 1, **110**: 854
Laryngeal hypoplasia 113: 1026
Laryngeal imaging
CT and MRI following radiotherapy **107**: 565
Laryngeal infections
aspergillosis **108**: 883
AIDS patient **112**: 488
candidiasis **110**: 789
airway obstruction, immunocompromised child **106**: 168
cause of stridor in previously irradiated patient **112**: 575
herpes simplex, neonatal stridor **112**: 1192
leishmaniasis **108**: 249, **108**: 1086
opportunistic disease in HIV infection **108**: 1089
leprosy **106**: 518
mycobacterial, uvula **112**: 1183
tuberculosis **111**: 619
clinical and videostroboscopic evaluation **112**: 45
Laryngeal inflammation
mimicking laryngeal carcinoma **111**: 568
Laryngeal injury
neck trauma **111**: 1174
penetrating, Bosnia **109**: 144
results of repair and functional outcome **109**: 340
Laryngeal involvement
mitochondrial myopathy **108**: 685
Laryngeal malakoplakia 111: 978
Laryngeal mask airway
bronchoscopy, and laryngoscopy **106**: 722
ENT surgery **106**: 28
paediatrics **111**: 349
and rigid endoscope, congenital stridor **108**: 1076
vocal fold paralysis **110**: 383
Laryngeal masses 109: 530, **109**: 895
aerodigestive tract obstruction as a late complication of radiotherapy **109**: 68
AIDS **110**: 1034
benign fibrous histiocytoma **110**: 474
bilateral ventricular neurofibroma **110**: 385
carcinoid **104**: 264, **105**: 683
atypical **109**: 455
with scalp metastases **111**: 89
carcinoma
acute phase proteins **106**: 613
cutaneous metastases **111**: 654

Laryngeal masses (continued)
DNA flow cytometry **104**: 485
ex-papilloma **109**: 762
extension to skin of neck **104**: 824
hypoparathyroidism following **112**: 1058
ionizing and microwave radiation **104**: 704
with limited metastatic disease, neck dissection **112**: 1031
lymph node dissection **112**: 438
metastasis from rectal primary **112**: 199
metastasis to small intestine **111**: 575
neuroendocrine **105**: 1031
multiple skin metastases **108**: 272
p53, MDM-2, cyclin D1 and Ki67 **112**: 455
pancreatic neuroendocrine and arytenoid **105**: 373
primary recurrence **109**: 1063
laryngectomy **107**: 611
proliferating cell nuclear antigen **112**: 310
radiation therapy **104**: 699
radiotherapy and salvage surgery **106**: 147
revision of classification **106**: 197
second primary, in lung cancer **112**: 252
selective lateral neck dissection, clinically negative neck **112**: 921
trichinosis **106**: 171
true **106**: 58
ultrasonography **107**: 65
in younger patients **110**: 934
cervical lymph node management **113**: 619
chemotherapy **105**: 930
chondroradionecrosis **109**: 218
chondrosarcoma **106**: 450, **109**: 168
cricoid cartilage **109**: 1120
cutaneous lymphoma 948
diagnostic imaging, autofluorescence using helium–cadmium laser **109**: 108
expression of EGF, EGFR and PCNA **109**: 630
fibroma **112**: 286
fibrous histiocytoma **112**: 1205
foreign body **104**: 131, **110**: 679, **110**: 1164
tracheostomy **111**: 652
granular cell tumour **104**: 159, **107**: 940
granuloma **112**: 83, **112**: 373
low-dose radiotherapy and excision **112**: 491
human papillomavirus **105**: 288, **110**: 1031
and p53 oncoprotein **110**: 742
hypopharynx, adenosquamous carcinoma **105**: 678
induction chemotherapy and radiotherapy, protocol for stage III & IV **113**: 433
laryngeal preservation, platinum-based induction chemotherapy **105**: 930
laser therapy **109**: 111
leiomyosarcoma **108**: 359, **113**: 167
emergency laryngectomy **105**: 134
lipoma, review of literature **109**: 353
lymphangioma in infants **110**: 969
malignant fibrous histiocytoma **105**: 130
malignant melanoma **113**: 932
malignant mesenchymoma **104**: 440
metastasis from colon adenocarcinoma **104**: 730
metastasis from ovarian carcinoma **104**: 48
mucoid adenocarcinoma **105**: 315
myxoma **108**: 811, **111**: 271
neurilemmoma, thyrotomy **113**: 346
neuroendocrine **108**: 272, **112**: 827
neurofibroma, paediatrics **110**: 1065
non-Hodgkin's lymphoma **111**: 571
non-irradiated, non-smoking patient **109**: 762
oncocytic cysts **109**: 1226
oncocytoma **104**: 346
papillary cystadenomatosis **106**: 656
papillomatosis **110**: 75
benign, clinical features of malignant transformation **108**: 642
development in paranasal sinuses **109**: 238
florid, following remission of 30 years **107**: 636
tracheobronchial involvement **108**: 164
paraganglioma **110**: 519
child **113**: 62
clinico-pathological classification **106**: 635
pharyngeal reconstruction, jejunal grafts **105**: 556
phenotype and prognosis **112**: 710
plasmacytoma, extramedullary **107**: 1049
pseudolymphoma **105**: 137
pseudotumour **109**: 142
recurrence analysis **109**: 1063
rhabdomyoma **109**: 147
rhabdomyosarcoma **112**: 670
saccular cyst **109**: 653
schwannoma **110**: 294
asphyxiation **111**: 1171
sebaceous differentiation **109**: 784
smooth muscle tumours **109**: 77
squamous cell carcinoma **110**: 440
cyclin D1 protein expression **111**: 622
DNA **113**: 538
and MALT-type lymphoma **108**: 995
pyriform fossa, pedunculated polypoidal mass **109**: 157
radiotherapy, anaemia **113**: 829
staging **105**: 456
vascular leiomyoma **108**: 593
see also Laryngeal surgery
Laryngeal morphology
sudden unexpected death in infants **105**: 646
Laryngeal myoclonus
cause of dysphagia and dysarthria **107**: 746
Laryngeal nerve
invasion by adenoid cystic carcinoma, vocal fold paralysis **113**: 260
monitoring, disposable electrode **112**: 561
neurorrhaphy **110**: 748
nonrecurrent, importance of pre-operative recognition **108**: 417
papillomatosis and laryngeal carcinoma, with human papilloma virus (HPV) type-18 **110**: 75
Laryngeal nerve palsy
recovery of function after intracordal fat injection **112**: 1082
secondary to benign thyroid disease **108**: 878
secondary to massive venous thrombosis **107**: 54
thyroid adenoma cause **105**: 141
Trousseau's syndrome **110**: 1166
Laryngeal occlusion *see* Airway obstruction
Laryngeal papillomatosis
carbon dioxide laser, children **106**: 715
Laryngeal paralysis
organophosphorus poisoning **112**: 81
Laryngeal preservation
combination chemotherapy vs surgery with/without radiotherapy **107**: 211
severe chondroradionecrosis, transposition of pectoralis major muscle **107**: 748
Laryngeal relapsing polychondritis
ephedrine **106**: 63
Laryngeal rheumatoid nodules 112: 573
Laryngeal sensory nerve fibres
CGRP-immunoreactive cells, nodose ganglion of cat **107**: 916
Laryngeal stenosis
endoscopic balloon dilatation **109**: 876
Laryngeal stricture
simultaneous with oesophageal stricture, dilatation with two T-tubes **108**: 42
Laryngeal stridor
in myasthenia gravis **106**: 633
Laryngeal surgery
endoscopic, prospective study **105**: 356
granuloma **112**: 491
laser and conventional **110**: 1138
laser microlaryngeal **105**: 946
laser surgery, HPV **110**: 1031
primary **105**: 353, **105**: 459
supero-lateral thyrotomy **106**: 416
superoxide dismutase, and adenosine deaminase **108**: 849
Laryngeal tracheal thyroid 104: 733
Laryngeal trauma 106: 372, **107**: 920
clinical analysis **108**: 221
effects on phonation **113**: 58
Laryngeal vestibulum
cat lower brainstem **109**: 39

Laryngectomy
amylase activity in tracheobronchial secretions **109**: 637, **109**: 640
blood transfusion **105**: 293
cervical spine osteomyelitis **106**: 1096
chondrosarcoma **109**: 168
complications, pharyngocutaneous fistula **109**: 221
diverticula **107**: 46
emergency **105**: 134, **105**: 463
extended partial, cartilage reconstruction **110**: 739
hypopharyngeal defect closure **111**: 1060
Jepson whistle **109**: 137
laryngeal carcinoma primary recurrence **107**: 611
partial, voice restoration **109**: 410
patient's view **105**: 934
post-laryngectomy
neopharyngeal diverticula **108**: 479
pharyngocutaneous fistula **109**: 221
Provox valve **109**: 1068
psychological morbidity **113**: 349
pyriform sinus mucosa for reconstruction **106**: 900
radiation injury, causing fistula **107**: 1136
radiotherapy, complications **107**: 130
report and analysis **111**: 730
secondary tracheo-oesophageal fistula creation **106**: 231
stomal recurrence, risk factors **107**: 527
supraglottic **107**: 813
and swimming **109**: 481
tracheo-oesophageal voice prostheses **110**: 37
use of inhalers **113**: 762
vertical partial **104**: 879
T_2 and T_3 laryngeal carcinomas **106**: 349
Laryngitis
chronic posterior, pantoprazole **113**: 734
Laryngo–tracheo–bronchopathia chondro-osteoplastica **106**: 845
Laryngocele
anatomical variant **113**: 675
CT scanning **108**: 266
and laryngeal amyloidosis **113**: 361
traumatic **112**: 482
Laryngomalacia 105: 1040
Laryngopharyngectomy
with pectoralis major myocutaneous flap, advanced pyriform carcinoma **107**: 817
Laryngopharyngoesophagectomy
with gastric transposition **110**: 1072
reconstruction with free forearm flap **111**: 48
Laryngoplasty
candidial invsion **110**: 240
indwelling tracheo-oesophageal voice prostheses **110**: 343
valve survival **110**: 37
Laryngopyocele
spontaneous regression **108**: 60
Laryngoscopy
and bronchoscopy, aided by laryngeal mask airway **106**: 722
difficult, extraction and re-implantation of teeth **108**: 44
endotracheal intubation **112**: 786
radiological investigations, pre-endoscopic assessment of children with stridor **109**: 844
transurethral rigid endoscopes, multidirectional observation **112**: 464
vocal folds, pre-operative checks **113**: 642
see also Endoscopy
Laryngospasm
pulmonary oedema **111**: 482
Laryngotracheal separation
intractable salivary aspiration, cricoidectomy with fibrin glue support **110**: 72
trauma **111**: 1079
Larynx
artificial **109**: 1068
Jepson whistle **109**: 137
pneumatic, Hong Kong **108**: 852
gastro-oesophageal reflux causing dysphonia **109**: 1195
growth in infancy **104**: 622
injuries and wounds **110**: 435
intralaryngeal gang[illegible] ganglionic neurons **109**: 622
mucus glycoproteins in victims of sudden infant death syndrome **109**: 403
penetrating injury, two case reports, Bosnia **109**: 144
thermal damage, microwave cooking **108**: 509
Larynx holder
laryngomicrosurgery **111**: 56
Laser surgery
argon, in epistaxis secondary to hereditary haemorrhagic telangiectasia **111**: 34
argon plasma coagulation, papillomatosis **111**: 381
carbon dioxide laser
aural papillomatosis **112**: 565
handheld safety improvements **108**: 233
and KTP-532 laser cordectomy, vocal fold paralysis **113**: 637
laryngeal carcinoma **109**: 111
laryngeal papillomatosis, children **106**: 715
with Montgomery T-tube, management of extensive subglottic stenosis **106**: 829
palatoplasty, resection of palatal tumours **104**: 20
palatoplasty for snoring **110**: 754
papillomatosis **112**: 565
repair of facial nerve, animal model **108**: 466
rhinophyma **110**: 841
stomaplasty for tracheostomal stenosis **112**: 467
tracheostomal stenosis **112**: 467
turbinectomy **111**: 931
vs conventional phonosurgery **113**: 140
cordectomy, bilateral vocal fold paralysis **113**: 637
erbium:YAG laser vs carbon dioxide laser, laryngeal surgery **107**: 908
helium:cadmium, diagnostic imaging **109**: 108
holmium:YAG
correction of choanal atresia **110**: 429
dacryocystorhinostomy **111**: 1056
laryngeal lymphangioma, in infants **110**: 969
laryngeal papillomatosis **112**: 565
development of papillomata in paranasal sinuses **109**: 238
microlaryngeal **105**: 946
myotomy, pharyngeal diverticula **111**: 627
nasal mucotomy **109**: 296
papilloma virus, laryngeal masses **110**: 1031
potassium-titanyl-phosphate (KTP) **111**: 659
chronic otitis externa **111**: 1126
cordectomy, bilateral vocal fold paralysis **113**: 637
glomus tympanicum **112**: 956
tonsillectomy, day-case procedure **109**: 515
pulsed dye laser, submandibular gland salivary calculus **110**: 942
sleep apnoea syndrome **113**: 1022
stapedotomy, osteosclerosis **113**: 413
tongue, lymphangioma **105**: 924
tracheal stenosis **110**: 973
turbinectomy **113**: 529
uvulopalatoplasty **110**: 232, **112**: 639
vs conventional phonosurgery **113**: 140
Laser-Doppler blood flowmetry
nasal mucosa **110**: 124
Lateral sinus thrombosis 104: 949
CT scanning and MRI **105**: 693
with extracranial head and neck abscesses **108**: 779
management **107**: 803
Lateral venous sinus
papilloedema **110**: 878
Latex-induced allergic rhinitis 109: 1094
Latin verse 105: 1125
Lead toxicity
complication of indoor pistol shooting **110**: 663
Lectin
histochemistry, animal models **111**: 141
Lectin receptors
in normal nasal mucosa, nasal polyp, inverted papilloma and papillary adenocarcinoma **107**: 600
Leeches 111: 980
in macroglossia **109**: 442
Leiomyoma
acute airway obstruction **104**: 341
atypical choanal **105**: 1065
nasal septum **104**: 891, **110**: 65

Leiomyoma (continued)
paranasal sinuses **107**: 740
smooth muscle tumours of larynx **109**: 77
vascular, larynx **108**: 593
Leiomyosarcoma
of auricle **112**: 166
emergency laryngectomy **105**: 134
larynx **108**: 359, **113**: 167
maxilla, post-irradiation **105**: 1068
parotid gland **110**: 401
primary gingival **106**: 46
primary intranodal, post radiation **109**: 80
smooth muscle tumours of larynx **109**: 77
tongue **108**: 617
Leiomyotomous hamartoma
tongue neoplasms **109**: 1190
Leishmaniasis
laryngeal **108**: 1086
opportunistic disease in HIV infection **108**: 1089
treatment with surgery **108**: 249
Lemierre syndrome
tonsillitis complication **109**: 657
Leprosy
larynx **106**: 518
and tuberculosis **107**: 845
multibacillary, ethmoid sinus involvement **112**: 1038
Leucine aminopeptidase
in head and neck cancer **108**: 660
Leukaemia
chronic lymphocytic, squamous cell carcinoma **110**: 694
lymphoblastic acute, cholesteatoma in same temporal bone **112**: 867
lymphoblastic lymphoma/leukaemia, perichondritis of pinna **112**: 592
T-cell leukaemia–lymphoma in Waldeyer's ring **107**: 960
Leukaemic cell infiltration
of nose **106**: 261
Levocabastine
perennial allergic rhinitis **111**: 935
Lhermitte–Duclos disease
tinnitus **113**: 464
Lichen planus
bilateral conductive deafness **112**: 365
Ligmaject system
local anaesthesia **104**: 606
Lignocaine (lidocaine)
intratympanic instillation via ventilation tubes, for tinnitus **106**: 603
Lingual thyroid
after previous thyroglossal cyst excision **108**: 341
magnetic resonance imaging **105**: 493
tongue-splitting incision, transoral excision **109**: 520
Lingual thyroid cyst
complicating foreign body, oesophagus **104**: 508
Lingual tuberculosis 112: 86
Linkage analysis
and tracking of susceptibility genes **112**: 323
Lip
carcinoma **105**: 640
Lipoma
cerebellopontine angle **107**: 553
hypopharynx, diagnosis and resection **108**: 174
left tonsillar fossa **108**: 507
middle ear **111**: 1162
nasopharyngeal neoplasms **110**: 275
MRI and X-ray CT **110**: 269
parotid gland, facial palsy **110**: 93
peritonsillar space **108**: 693
pharynx **113**: 935
pleomorphic, parotid gland **112**: 202
polypoid, palatine tonsil **107**: 556
salivary gland, deep lobe **109**: 772
tongue **110**: 189
tonsillar mass **109**: 662
Lipomatosis
minor salivary glands **112**: 895
Liposarcoma
hypopharyngeal **112**: 880
myxoid **113**: 179
retropharyngeal **106**: 469
temporal bone, radiotherapy **110**: 779
Litigation
otolaryngology **104**: 162
Liver extracts
for ageusia **110**: 598
Liver metastases
carcinoma arising within a pleomorphic adenoma of parotid gland **104**: 152
Local anaesthesia *see* Anaesthesia, local
Long-term results
revision endolymphatic sac surgery **104**: 613
Lothrop procedure
chronic frontal sinus disease **111**: 637
Lower motor neurone facial paralysis
pregnancy **108**: 587
Luc's abscess
middle ear infection **111**: 461
Lung cancer
second primary laryngeal carcinoma **112**: 252
Lupus
hydralazine-induced, and vocal fold paralysis **112**: 875
Lyme disease
hearing loss **111**: 562
Lymph nodes
assessment, palpation vs ultrasound, malignant cervical lymph nodes **107**: 821
biopsy, diagnosis of acquired toxoplasmosis **110**: 348
cystic metastases, from occult thyroid carcinoma **106**: 932
dissection, laryngeal and hypopharyngeal cancer **112**: 438
hyperplasia **110**: 896
metastases treated by radiotherapy, echography **113**: 993
metastatic squamous carcinomas, upper aerodigestive tract **110**: 937
mycobacterial infection, paediatrics **110**: 48
negative, non-conventional squamous carcinoma of larynx **113**: 619
parotid gland, metastatic neoplasms **110**: 148
post radiation primary intranodal leiomyosarcoma **109**: 80
see also Cervical lymph nodes
Lymphadenitis
Kikuchi's necrotising **105**: 496
mycobacterial cervical **108**: 514
Mycobacterium avium-intracellulare in siblings: case report and review **109**: 70
toxoplasmosis, parotid gland **105**: 860
tubercle bacilli in cervical lymph node **105**: 558
Lymphadenopathy
mycobacterial infection **107**: 614
mycobacterium marches back **109**: 5
Lymphadenopathy (Rosai–Dorfman disease)
sinus histiocytosis **106**: 61
Lymphangioma
parotid gland **110**: 586
post-cricoid **105**: 220
tongue **105**: 924
Lymphoblastic lymphoma/leukaemia
perichondritis of pinna **112**: 592
Lymphogranuloma venereum
tonsil **104**: 331
Lymphoma
angiocentric, involving posterior tongue, hypopharynx and supraglottis **113**: 263
associated with Epstein–Barr virus infection **107**: 468
B-cell
extensive cutaneous involvement **112**: 186
non-Hodgkin's, paranasal sinuses **108**: 263
parotid gland **110**: 811
bilateral cerebellopontine angle lesions **107**: 937
Burkitt's, tonsil **104**: 991
cavernous sinus syndrome, primary paranasal sinus non-Hodgkin's lymphoma **112**: 777
cervical, midline presentation **104**: 737
cutaneous neoplasms **113**: 948
and Hashimoto's thyroiditis **109**: 781
in HIV, causing stridor **109**: 1197
IMDD **112**: 307

mantle cell lymphoma, blastic variant **112**: 991
non-Hodgkin's
external auditory canal, HIV-positive patient **109**: 751
Hashimoto's thyroiditis **109**: 781
HIV infection and AIDS **112**: 77, **112**: 982
involving tonsil **105**: 445
lacrimal sac, pansinusitis **112**: 969
paranasal sinuses **108**: 263
primary laryngeal **112**: 712
primary malignant, cerebellopontine angle **112**: 476
and rhabdomyosarcoma, causing acute bilateral blindness in childhood **108**: 873
small lymphocytic, palate, involvement of parotid and submandibular glands bilaterally **105**: 584
T cell-rich, parotid gland **110**: 811
T-cell
associated with Epstein–Barr virus infection **107**: 468
granulomatous cutaneous, neck **106**: 563
tonsillar squamous cell carcinoma **111**: 580
see also Burkitt's lymphoma
Lymphoproliferative oropharyngeal lesions
heart and heart-lung transplant recipients **104**: 720

MacBeth, Ronald Graeme
obituary **107**: 101
Macroglossia *see* Tongue
Maffucci's syndrome
and Ollier's disease **113**: 861
Magnetic resonance imaging
aspirated peanut, bronchus **108**: 804
and CT scanning, following radiotherapy of larynx **107**: 565
epidermoid tumour, cerebellopontine angle **108**: 438
evaluation of encephalocele **112**: 790
facial motor function after removal of vestibular schwannomas **109**: 394
false positive
otoneurological pathology **107**: 465
small intracanalicular vestibular schwannomas **108**: 986
fast spin echo MRI **108**: 383
frontal sinus surgery **109**: 1115
Gd imaging, comparison with CT and MR, adenoid cystic carcinoma **104**: 662
glomus jugulare tumour **107**: 1067
initial screen for vestibular schwannoma, unilateral tinnitus **113**: 818
inner ear deformity, endolymphatic sac **111**: 754
intracochlear acoustic schwannoma **108**: 1111
juvenile angiofibroma **113**: 127
large vestibular aqueduct (endolymphatic sac) **110**: 1103
lateral sinus thrombosis **105**: 693
lingual thyroid **105**: 493
maxillary sinuses, gene therapy in cystic fibrosis **113**: 329
nasal neoplasms **110**: 269
necrotizing external otitis **112**: 98
osteomyelitis, temporomandibular joint, malignant otitis externa **113**: 451
paranasal sinuses **105**: 278, **110**: 649
percutaneous dilatational tracheostomy **111**: 953
Ramsay Hunt syndrome
diagnosis and treatment **109**: 777
mimicking acoustic neuroma **109**: 1013
sarcoidosis **109**: 1089
screening protocol for vestibular schwannoma **110**: 1129
subtraction MRI for tumours of skull base and sinuses **105**: 628
vestibular schwannoma **111**: 877
vocal fold paralysis **110**: 884
and X-ray CT, neurofibroma, diffuse **110**: 182
Malakoplakia
chronic inflammatory mass, neck **106**: 173
laryngeal **111**: 978
temporal bone, infant **105**: 568
Malaysians
Pindborg tumour **110**: 757
Male puberty
vocal fold length and its relationship to fundamental frequency of voice **112**: 451
Malignant external otitis *see* Otitis externa
Malleomyringoplasty
silicone prosthesis **106**: 205
MALT-type lymphoma
and squamous cell carcinoma, larynx **108**: 995
Mammals
ganglia and ganglion neurons, arrangement and number **109**: 622
Mandible
intra-osseous osteosarcoma **104**: 335
involvement in oral cancer **104**: 968
osteoradionecrosis, hemimandibulectomy **104**: 305
reconstruction, bone graft **108**: 969
Mandibulotomy
oral and oropharyngeal tumours **107**: 316
Manomometry
screening procedure, in voice rehabilitation **106**: 353
Mantle cell lymphoma
blastic variant in Waldeyer's tonsillar ring **112**: 991
Maori children
epidemiology, of otitis media **105**: 257
Marfan syndrome
meatoplasty **110**: 456
Marijuana smoking
tongue carcinoma in young patients **104**: 896
Marinesco-Sjögren syndrome
sensorineural deafness **105**: 210
Masseter muscle
metastatic neoplasms **110**: 172
primitive neuroectodermal tumour **110**: 1179
Masson's tumour
maxillary sinus **112**: 500
Mast cells
aural polyps **109**: 491
inferior turbinate, perennial allergic rhinitis **105**: 736
perennial allergic rhinitis **110**: 929
proteins, compared with otitis media effusion proteins **109**: 1146
quantitation, nasal polyps, sinus mucosa, and nasal turbinate mucosa **107**: 418
ultrastructure **105**: 1006, **111**: 340
adenoids of children with/without secretory otitis media **108**: 1058
Mastication
claudication, following bilateral external carotid artery ligation for posterior epistaxis **112**: 73
Mastoid
osteoblastoma **109**: 565
Mastoid air cell system
size variation, India **104**: 603
Mastoid antrum
(mega antrum) **106**: 164
Mastoid cavities
acoustic properties, animal models **106**: 597
reconstruction, pedicled musculo-fascial flap **106**: 124
Mastoid process syndromes
thyroid cartilage **111**: 1190
Mastoid surgery
canal wall, failure **109**: 583
cholesteatoma **106**: 393
chronic suppurative otitis media, postauricular cerebellar encephalocele **104**: 982
for cochlear implants **113**: 881
complications **109**: 710
epithelial migration, open cavities **109**: 286
eye protection **109**: 707
facial nerve palsy **111**: 113
and Hong Kong Flap **108**: 825
microsuction, audit **109**: 971
Red Cross War Memorial Children's Hospital 1986-1988 **105**: 409
squamous cell carcinoma **105**: 38
tuberculoma **109**: 232
Xeroform or BIPP packs **105**: 916
see also Mastoidectomy
Mastoid temporocele
CT findings and management **113**: 661
Mastoidectomy
canine *Pasteurella multocida* meningitis **105**: 571
chronic suppurative otitis media **110**: 315
complications **110**: 10
histopathology, temporal bone **107**: 569
otitic intracranial complications **107**: 1113

Mastoidectomy (continued)
revision, chronic otitis media without cholesteatoma, exenteration of rest cells **113**: 710
with vascularised temporoparietal fascia flap **105**: 417
vestibular neurectomy **110**: 836
see also Mastoid surgery
Mastoiditis
actinomycosis **111**: 1069
antibiotics **113**: 1081
aspergillosis in HIV infection **111**: 560
bilateral acute, lateral sinus thrombosis **106**: 535
grafting with autologous epithelial layers generated by *in vivo* culture of buccal epithelium **105**: 413
latent **105**: 767
middle ear lipoma **111**: 1162
simulating facial nerve schwannoma, MRI **108**: 1008
sixth nerve palsy **110**: 872
tuberculous **105**: 907, **111**: 752
Maxilla
osteomyelitis, neonates **107**: 627
Maxillary artery occlusion
intractable epistaxis **106**: 507
Maxillary neoplasms 109: 1019
ameloblastoma, calcifying and keratinising **105**: 971
carcinoma **104**: 557
bilateral **107**: 42
pre-operative or radical radiotherapy **106**: 1063
T-classification and direction of tumour spread, pain **106**: 804
cavernous haemangioma **112**: 872
cholesterol granuloma **112**: 65
chondrosarcoma **106**: 53
dentigerous cyst **111**: 641
epithelial odontogenic ghost cell tumour **108**: 269
false aneurysms **106**: 1103
foreign bodies **104**: 718
haemangioma **111**: 638
haemangiosarcoma **104**: 831
infancy, fine needle aspiration **113**: 581
leiomyosarcoma, post-irradiation **105**: 1068
melanoma and mucoepidermoid carcinoma **105**: 370
melanotic neuroectodermal tumour of infancy **112**: 61
meningioma, and tuberous sclerosis **105**: 481
mesenchymal chondrosarcoma **108**: 785
myxoid chondrosarcoma **105**: 676
non-Hodgkin's lymphoma, AIDS **112**: 982
optic nerve, bilateral salivary gland neoplasms **105**: 584
ossifying pleomorphic adenoma **106**: 50
papillary endothelial hyperplasia (Masson's tumour) **112**: 500
paraganglioma **104**: 248
plasma cell granuloma **108**: 357
pseudotumour **104**: 244
teeth **111**: 820
verrucous squamous carcinoma **105**: 696, **112**: 399
Maxillary sinuses
acquired involution **108**: 74
air cyst *(pneumosinus dilatans)* **105**: 673
aneurysmal bone cyst **104**: 501
antral lavage using inferior meatal cannula anaesthesia **110**: 763
barotrauma, fifth cranial nerve involvement **105**: 217
Caldwell-Luc procedure, post-operative complications **110**: 228
endoscopically normal, bacteriology **113**: 825
endoscopy **110**: 926
enophthalmus, surgery **109**: 868
epidemiology of masses, Kenya **106**: 337
fistulae, palatal defects **113**: 834
fusariosis, in immunocompetent hosts **106**: 733
MRI and gene therapy in cystic fibrosis **113**: 329
mucocele **113**: 1106
with facial asymmetry **107**: 451
mucociliary clearance **113**: 865
and paranasal sinuses, cysts **110**: 1157
radiographs, children **105**: 541
surgery, experimental study in rabbits **110**: 644
tumours, nucleolar organizer regions **111**: 38
see also Sinusitis
Maxillary sinusitis
children with otitis media with effusion **108**: 842
chronic sinusitis **112**: 845
dental osseointegrated implants **104**: 333
Maxillofacial abnormalities
sleep apnoea syndrome **105**: 94
MDM-2
progression from low-grade dysplasia to laryngeal carcinoma **112**: 455
Meatoplasty
conchal flap meatoplasty **107**: 1029
Marfan syndrome **110**: 456
Medial canal fibrosis 112: 145
Medial olivocochlear efferent system (MOES)
primates, interdependence and micromechanics of cochlea **107**: 883
Mediastinal goitres
CT imaging **106**: 65
Mediastinitis
peritonsillar abscess **110**: 175
Mediastinum
parathyroid cyst **104**: 56
venous haemangioma **105**: 386
Medical education
audit, overseas postgraduate training programme in ENT **108**: 1072
graduate, stapedectomy: Singapore problem **109**: 225
specialist training, attitudes, present and recent trainees **108**: 291
Medical examiners
variability **111**: 8
Medicolegal assessments 109: 1085
audiometry **105**: 518
bone conduction errors at high frequencies **107**: 305
dissection supply **112**: 1138
Medulla oblongata
vocal fold paralysis **110**: 884
Melanoma
amelanotic, metastatic to epiglottis **105**: 776
external ear **107**: 798
frontal sinuses **111**: 376
larynx **112**: 711
radiotherapy **113**: 932
and mucoepidermoid carcinoma, maxillary antrum **105**: 370
palatine tonsil **110**: 163
parotid metastases **104**: 350
pharynx **108**: 275
primary mucosal malignant, middle ear **105**: 1061
tonsil **113**: 1036
tonsil and nasopharynx **109**: 236
Melanotic neuroectodermal tumour
of infancy **107**: 1045
fine needle aspiration **113**: 581
maxilla **112**: 61
squamous and occipital bone **107**: 843
MELAS syndrome
hearing loss **111**: 279
Melioidosis
parapharyngeal space **105**: 582
Melnick–Needles syndrome
and sleep apnoea, emergency tracheostomy **107**: 647
Ménière's disease 110: 836, **110**: 1107
aminoglycosides **113**: 916
chemical labyrinthectomy and cochlear implantation **113**: 666
endolymphatic sac drainage **105**: 1109
endolymphatic sac surgery **110**: 1008
genetic form **109**: 499
labyrinthectomy **110**: 216
vestibular neurectomy **105**: 1002
histological and clinical study of results **110**: 211
vs noise-induced hearing loss, criteria in objective assessment of auditory threshold **107**: 780
Meningioma
auditory canal, extension into vestibule **113**: 1101
cerebellopontine angle **111**: 1022
external auditory meatus **111**: 148
foramen magnum, hoarseness **104**: 715
maxillary antrum, and tuberous sclerosis **105**: 481
metastatic, neck **105**: 229
palatine tonsil, primary ectopic **111**: 179
preponderance in females, gene for type 2 neurofibromatosis **109**: 830

Meningitis
bacterial
hearing loss **113**: 1011
otitis media **111**: 913
canine *Pasteurella multocida* **105**: 571
congenital fistula of stape footplate **107**: 931
evaluation of hearing loss **111**: 223
Fusobacterium necrophorum **105**: 119
inner ear, congenital cerebrospinal fluid fistula **107**: 492
recurrent
caused by severe cochlear dysplasia **107**: 726
heterotopic brain tissue **104**: 328
Meningocele
neck mass in neurofibromatosis type-1 **106**: 463
sphenoid sinus, Le Fort I osteotomy approach **112**: 779
Menstrual cycle
nasal mucosal congestion **111**: 337
Merkel cell carcinoma
metastatic to tonsil **106**: 1100
pinna **111**: 1195
Mesenchymoma
larynx **104**: 440
retropharyngeal space **107**: 1165
Meta-analysis
otitis media surgery **105**: 812
Metal foreign bodies 110: 793
Metaplasia
cartilaginous, epiglottis **104**: 903
Metastases
adenocarcinoma
temporal bone **108**: 710
to ethmoid **109**: 759
to larynx **104**: 730
to palatine tonsil **108**: 178
amelanotic melanoma, to epiglottis **105**: 776
bilateral parotid, carcinoid tumours **105**: 489
breast carcinoma, to external auditory canal **108**: 808
bronchial carcinoma, to tongue **108**: 1099
cervical node, features of branchial cysts **108**: 1068
choriocarcinoma, maxilla, severe intractable epistaxis **106**: 917
clear cell renal carcinoma, to cerebellopontine angle **110**: 370
colon carcinoma, to palatine tonsil **108**: 449
CT demonstration, anaerobic orbital abscess **105**: 1086
cutaneous melanoma, to parotid **104**: 350
dural, vocal fold paralysis **110**: 884
gastric adenocarcinoma, to tonsil **110**: 291
glomus tumour, MIBG scintigraphy **110**: 373
head and neck cancer **107**: 1171, **111**: 454
hepatocellular carcinoma, to sphenoid sinus **108**: 503
Hurthle cell tumour, airway obstruction **107**: 957
hyoid bone mass presenting with cervical nodal metastasis **107**: 967
implantation, following percutaneous endoscopic gastrostomy **107**: 946
laryngeal carcinoid, to scalp **111**: 89
laryngeal carcinoma **111**: 575, **111**: 654
'lateral aberrant thyroid' **106**: 376
lymph nodes **110**: 148
malignant oncocytoma of submandibular gland **112**: 106
masseter muscle **110**: 172
melanoma, tonsil and nasopharnyx **109**: 236
meningioma in neck **105**: 229
Merkel-cell carcinoma, to tonsil **106**: 1100
minimizing complications **113**: 101
multiple, from malignant pleomorphic adenoma of parotid gland **106**: 652
nasopharyngeal carcinoma **105**: 772
to thyroid **108**: 886
neuroendocrine carcinoma, to skin **108**: 272
osteosarcoma of ethmoid, recurrent epistaxis and proptosis **110**: 676
ovarian carcinoma, to larynx **104**: 48
papillary thyroid carcinoma as branchioma **110**: 490
paranasal sinuses **109**: 986
pleomorphic adenoma **104**: 45
to parotid gland **104**: 152
primary bronchial carcinoid, bilateral parotid **105**: 489
primary rectal carcinoma to thyroid gland **110**: 192
prostatic carcinoma
sensorineural hearing loss **107**: 933
to nose and paranasal sinuses **107**: 629
to tonsil **108**: 178
pulmonary carcinoma, to larynx **108**: 898
rectal primary, to larynx **112**: 199
renal cell carcinoma **111**: 379, **111**: 1066
presenting as ear bleeding **110**: 370
to paranasal sinuses **109**: 986
to parotid **104**: 352
to tongue **106**: 282
retropharyngeal haematoma causing acute airway obstruction **113**: 258
salivary adenocarcinoma, to orbit and skin **109**: 1222
seminoma of sphenoid sinus **105**: 1075
sinonasal carcinoma, to lymph nodes **109**: 304
squamous cell carcinoma
massive, tonsil **105**: 50
maxillary antrum, to heart and skin **108**: 896
staging, chest and abdomen **113**: 152
to lymph nodes **110**: 937
thyroid carcinoma **109**: 1109
follicular, to sinuses **108**: 1010
occult, to lymph nodes **106**: 932
to paranasal sinuses **111**: 647
to temporal bone **109**: 1200
tonsil and nasopharynx **109**: 236
tonsillar melanoma **113**: 1036
treated by radiotherapy, echography **113**: 993
ultrasound-guided biopsy **113**: 988
unknown primary **110**: 353
to parapharyngeal region **109**: 1204
Methaemoglobinaemia
BIPP-induced **105**: 78
Metronidazole
ototoxicity **113**: 355
Mexico
epidemiology of hearing impairment in diabetic Mexican Americans **112**: 835
Mianserin hydrochloride
toxicity **105**: 475
MIBG scintigraphy
metastatic glomus tumour **110**: 373
Microangiopathy
NIDD, inner ear **113**: 13
Microbiology *see* Bacteriology
Microcystic adnexal carcinoma 111: 674
Microlaryngeal surgery 112: 351
ventilatory monitoring, jet insufflation anaesthesia **106**: 42
Microlaryngoscopy
endotracheal intubation **112**: 786
Microscopy
operating, temporal bone laboratory **111**: 958
tonsillar abscesses **111**: 392
Microsurgical techniques
thyroid surgery **112**: 556
Microwave radiation
cooking, direct thermal damage to pharynx and larynx **108**: 509
recurrent laryngeal carcinoma **104**: 704
Middle ear
arterial anomalies associated with stapes ankylosis **108**: 237
auditory ossicle, Apaceram treatment, rats **109**: 14, **111**: 702
bacteriology **110**: 847, **110**: 950, **113**: 24
blast injuries **105**: 890
cleft palate, ventilation and outcome, parental perception **113**: 1068
deep oval window **105**: 721, **105**: 725
incus
lesions, tripod allograft in reconstruction **108**: 206
necrosis, chorda tympani nerve **106**: 252
transposition, tympanoplasty **106**: 607
infection and sixth nerve palsy **110**: 872
mechanics, normal, diseased and reconstructed ears **112**: 715
myoclonus **108**: 380
otic capsule, pathology **104**: 83
pregnancy **113**: 318
sensory nerve supply **109**: 1141

Middle ear (continued)
see also Myringotomy; Otitis media; Stapedectomy; Temporal bone
Middle ear cleft
brain herniation, tegmental dehiscence **105**: 477
Middle ear epithelium
surface morphology, chronic ear disease **108**: 1024
Middle ear inflation
diagnostic indicator of Eustachian tube patency **104**: 134
Middle ear masses 109: 977
actinomycosis **112**: 800
aggressive papillary **105**: 950
branchio–oto–renal syndrome, cholesteatoma **113**: 841
choristoma of salivary gland **106**: 630
dermoid cysts **107**: 335
extramedullary plasmacytoma **108**: 868
haemangioperiocytoma **113**: 911
Hodgkin's disease **110**: 869
invasive choroid plexus tumour, Von Hippel–Lindau disease **106**: 429
lipoma **107**: 1151
mastoiditis **111**: 1162
medullary carcinoma metastatic to temporal bone **109**: 1200
mucoepidermoid carcinoma **110**: 249
osteoma **104**: 803
papillary adenocarcinoma **104**: 915
polyps, mast cells **109**: 491
primary mucosal malignant melanoma **105**: 1061
squamous cell carcinoma **105**: 38
synovial sarcoma **107**: 1071
teratoma, newborn **110**: 875
transitional papilloma **106**: 628
Middle ear pressures
nasopharyngeal carcinoma **109**: 390
Middle ear surgery
bismuth-iodoform-paraffin paste, causing allergic reactions **112**: 335
clinical trials of biological dressings **112**: 140
complications **113**: 803
drill-generated noise levels **105**: 732
head dressings **107**: 17
hearing benefit evaluation **107**: 4
iatrogenic epidermoid cyst **105**: 227
incudostapedial joint, 3-D reconstruction with hCT **113**: 707
incus, repair **109**: 1048
intracranial complications, role for cefotaxime **107**: 1005
ionomeric cement **111**: 1130
'only hearing ear' **106**: 793
ossiculoplasty **105**: 529
stapes surgery **111**: 233
to sigmoid sinus **110**: 984
tympanic neurectomy **109**: 1155
tympanosclerosis **104**: 685
ventilation
cost-benefit analysis **110**: 527
otitis media, teaching materials **112**: 642
Pierre Robin syndrome **110**: 830
steroid/antibiotic prophylaxis **110**: 531
tympanectomy **109**: 1151
see also Ventilation tubes
Midfacial degloving
nasal neoplasms, paranasal sinuses **113**: 885
sinonasal surgery **106**: 1059
Midlands Institute of Otology 111: 1122
Midline destructive disease 112: 307
Midline presentation
cervical lymphomata **104**: 737
sublingual dermoid cyst **104**: 578
Milk nasendoscopy
assessment of dysphagia **106**: 525
Minoan era
otorhinolaryngological diseases **107**: 879
Mitochondrial cytopathy
cochlear implantation **113**: 353
Mitochondrial myopathy
laryngeal involvement **108**: 685
Mixed tumour
salivary gland, external nose **108**: 76, **110**: 376
Molecular genetics
allergy **112**: 1126
ENT surgeon in next millennium **112**: 4
head and neck cancer **112**: 607
inherited deafness
future applications **112**: 523
recent advances **112**: 432
linkage analysis, and tracking of susceptibility genes **112**: 323
principles **112**: 128
techniques **112**: 230
tumours of ear and temporal bone **112**: 1011
vestibular schwannoma **109**: 381
Montgomery safe T-tube plug
inhalation **106**: 1004
Mouthwash
surgery of oral cavity and oropharynx **108**: 973
Mucoceles 110: 1157
ethmoid and sphenoid sinuses **106**: 23
fronto-ethmoidal, histopathology **105**: 921
management of paranasal sinus mucoceles by endoscopy **112**: 36
maxillary antrum
endometrial carcinoma metastasis **112**: 283
with facial asymmetry **107**: 451
maxillary sinuses **113**: 1106
mimicking Warthin's tumour recurrence **112**: 1092
paranasal sinuses **112**: 36, **112**: 840
sphenoid sinus, radiotherapy to head and neck **105**: 959
Mucociliary clearance
and airflow, in normal subjects **107**: 603
long-term antibiotic therapy, ciliary beat frequency in chronic rhinosinusitis **109**: 24
maxillary sinuses **113**: 865
tympanoplasty **107**: 895
Mucocutaneous allergic vasculitis
anti-neutrophil cytoplasmic antibodies **113**: 477
Mucoepidermoid carcinoma
larynx **112**: 712
maxillary antrum **105**: 370
middle ear **110**: 249
Mucoid adenocarcinoma
larynx **105**: 315
Mucormycosis
ketoacidotic diabetic patient **107**: 233
liposomal amphotericin **105**: 575
rhinocerebral **106**: 48
antifungal therapy **112**: 367
sphenoid sinus **110**: 471
Mucosal immunity
EBV infection **110**: 339
Mucous membranes
animal models **110**: 644
plasmacytosis, upper aerodigestive tract **111**: 293
severe chronic inflammation, work-related exposure to hexavalent chromium **108**: 591
Mucus
glycoproteins, in larynges of victims of sudden infant death syndrome **109**: 403
Mucus, circulation
between accessory ostium and natural ostium, maxillary sinus **113**: 865
Multiple glomus tumours 106: 538
Multiple myeloma
with external ear canal mass **112**: 469
Multiple sclerosis
auditory pathway lesion, electrocochleographic findings **110**: 252
Multiple submucosal out-fractures
inferior turbinates **104**: 239
Multiple system atrophy
vocal fold palsy **112**: 177
Munchausen syndrome 110: 981
Munchausen syndrome by proxy 107: 151
unmasked by nasal signs **108**: 336
Mutational voice disorders
Isshiki type III thyroplasty, acoustic evaluation **113**: 31
Myasthenia gravis
bilateral abductor paralysis of vocal folds **113**: 678
laryngeal stridor **106**: 633
postoperative ventilatory failure **112**: 1194

presenting during general anaesthesia for oesophagoscopy **108**: 599
stridor **113**: 1114
vocal fold paralysis **106**: 737
Mycobacterial infection 109: 5
cervical lymphadenitis **108**: 514, **109**: 70
cervical lymphadenopathy **107**: 614
paediatrics **110**: 48
parotid gland **107**: 561
uvula **112**: 1183
***Mycobacterium avium-intracellulare* infection**
cervical lymphadenitis **109**: 70
in siblings, case report and review **109**: 70
Mycotic aneurysm
external carotid artery **112**: 793
Myiasis
nasal, endoscopy **108**: 1083
Myoclonus
palatal, affected by neck position **109**: 61
Myocutaneous flaps
and sternocleidomastoid muscle **104**: 315
Myoepithelioma
deglutition **113**: 569
nasal cavity **110**: 397
and nucleolar organizer regions (NORS) **106**: 616
parotid gland **109**: 995
Myofibroblastic tumour
tonsil **111**: 880
Myofibromatosis
nasal cavity **110**: 574
pinna **113**: 155
Myositis
sternocleidomastoid muscle **112**: 687, **113**: 856
Myxoedema
acquired, temporal bone **105**: 886
Reinke's oedema **105**: 291
Myxoid chondrosarcoma
external auditory meatus **113**: 742
maxillary sinus **105**: 676
Myxoid liposarcoma
parapharyngeal **113**: 179
Myxoma
external auditory meatus **105**: 364
larynx, review of literature **108**: 811
paranasal sinuses **108**: 679
retropharyngeal masses **108**: 690

Naevus
and hyperplastic salivary gland, hamartoma-like mass **111**: 296
Nasal
see also Paranasal
Nasal airflow
inspiration and expiration **104**: 473
and mucociliary transport, in normal subjects **107**: 603
sensitivity in normal subjects **108**: 1045
Nasal airway resistance
histamine H_1 receptor blockade **109**: 841
peak inspiratory flow, plateau effect **109**: 399
pressure measurement, transducer probe vs open catheter **109**: 414
Nasal anomalies
developmental **104**: 394
Nasal augmentation *see* Rhinoplasty
Nasal cavity
cavernous haemangioma **106**: 264
and ethmoid, teratocarcinosarcoma **112**: 682
olfactory mucosa **112**: 11
osteoblastoma **107**: 737, **111**: 865
testicular teratoma, severe intractable epistaxis **112**: 1078
Nasal corticosteroids
long-term results **106**: 810
Nasal CPAP
Robin sequence treatment **109**: 328
Nasal deformities
thrombosis following manipulation of fractured nasal bones **110**: 69
Nasal destruction
rapid, nose and face **105**: 1120
Nasal displacement
measurement by photography **106**: 211
Nasal dorsum
fibromatosis **106**: 821
Nasal drops
instillation positions **113**: 326
Nasal endoscopy
epistaxis, fracture of basisphenoid **113**: 561
local anaesthesia **111**: 616
posterior epistaxis **105**: 428
velopharyngeal function **111**: 739
Nasal foreign bodies
children **110**: 559
Nasal fossa
Ewing's sarcoma **104**: 570
Nasal infections
brush cytology **113**: 983
leishmaniasis **107**: 834
Nasal injury 105: 215
Nasal masses 104: 696, **109**: 677
adenocarcinoma, paranasal sinus **110**: 805
basaloid-squamous carcinoma **106**: 370
carcinoma, nasal vestibule **104**: 9
cartilaginous tumour **105**: 670
chondroblastoma **110**: 696
epithelial–myoepithelial carcinoma **110**: 397
frontal and ethmoidal sinuses **109**: 258
granuloma **105**: 123, **105**: 1120
haemangioma **105**: 389, **111**: 941
haemangiopericytoma **105**: 593, **113**: 199
haemophilic pseudotumour **113**: 924
heterotopic pleomorphic adenoma **110**: 376
lipomas
MRI and X-ray CT **110**: 269
paediatrics **110**: 269
midfacial degloving **113**: 885
multiple, and of paranasal sinuses **104**: 696
myofibromatosis **110**: 574
oncocytic mixed nasal tumour **107**: 732
oncocytoma **111**: 671
and paranasal sinuses, cysts **110**: 1157
plasmacytoma **105**: 41
pyogenic granuloma **111**: 941
schwannoma, benign **106**: 1011
solitary fibrous tumour **110**: 468
syringoma **111**: 862
T-cell lymphoma associated with Epstein–Barr virus infection **107**: 468
verruciform xanthoma **113**: 79
see also Nasopharyngeal masses; Paranasal *and other named* sinuses
Nasal muco-ciliary clearance in snuff users 107: 24
Nasal mucosa
beta adrenoceptors **105**: 632
blood flow, cocaine with/without adrenaline **105**: 918
computer-assisted image processing, endoscopy **110**: 1017
congestion, menstrual cycle **111**: 337
Kaposi's sarcoma (pyogenic granuloma) **112**: 280
lectin receptors **107**: 600
silver nitrate cautery **110**: 609
Nasal myiasis
endoscopy **108**: 1083
Nasal nerve
division, treatment for post-traumatic neuralgia **106**: 915
Nasal obstruction 110: 221
complication of nasotracheal intubation **108**: 991
craniometaphyseal/craniodiaphyseal dysplasia **110**: 328
endoscopy **106**: 977
sickle cell disease **105**: 851
Nasal packing
nasal surgery **107**: 902, **108**: 564
nocturnal oxygen desaturation **105**: 109
resection of turbinates **107**: 906
Nasal papilloma
endoscopy **112**: 758
Nasal polyps
antrochoanal
in a child **110**: 272

Nasal polyps (continued)
treatment with intranasal steroids **109**: 553
beconase nasal spray on olfactory function post-surgery **109**: 941
cetirizine **112**: 1042
epithelial atypia and squamous metaplasia **112**: 755
extranodal Rosai–Dorfman disease **113**: 275
identical twins **106**: 1084
IgE decapeptide and substance P **110**: 225
lectin receptors **107**: 600
massive pneumocephalus and cerebrospinal fluid rhinorrhoea, biopsy **112**: 657
mast cell quantitation **107**: 418
mast cell ultrastructure **111**: 340
mesenchymal chondrosarcoma, rare congenital **106**: 1081
premalignant change **104**: 210
prevalence **110**: 736
spheno-choanal, radiological diagnosis **107**: 159
steroids, acoustic rhinometry **105**: 178
strangulation **107**: 342
suction polypectomy forceps **107**: 35
surgery, antral washout as routine **106**: 695
see also Polyps; *other locations*
Nasal preparation
nasal packing vs spraying **106**: 39
Nasal sarcoidosis 113: 893
Nasal secretions
airway obstruction with stridor **109**: 331
Nasal septum
abscess **112**: 776
and auricular cartilage, extended partial laryngectomy **110**: 739
cryoglobulinaemia **110**: 668
deformity, and palatal symmetry, neonates **105**: 424
deviation, endoscopic approach **112**: 934
graft, temporoparietal fascia flap, tracheal reconstruction **106**: 741
haematoma, Nigeria **106**: 396
leiomyoma **104**: 891, **110**: 65
pleomorphic adenoma **113**: 483
septoplasty
and compensatory inferior turbinate hypertrophy, acoustic rhinometry **107**: 413
day-case procedure **110**: 129
septorhinoplasty
carotico–cavernous fistula **113**: 844
two-point fixation **113**: 405
spindle cell carcinoma **110**: 284
submucous resection, as outpatient procedure **105**: 544
surgery
audit **109**: 320
day-case **109**: 614
out-patient procedure **111**: 1034
vasoconstrictor and saline use **105**: 638
verrucous squamous carcinoma **112**: 172
Xomed one piece septal button **106**: 358
Nasal septum perforation
bone and temporal fascia graft **112**: 1167
and fistula **113**: 1020
repair
one-stage rhinoplasty **113**: 728
septal button insertion **113**: 823
utilizing extraction–reposition technique, quadrangular cartilage **113**: 721
see also Septorhinoplasty
tragal cartilage graft **111**: 435
tragal cartilage inferior turbinate mucoperiosteal sandwich graft technique **106**: 893
Nasal sinuses
metastases, from prostatic carcinoma **107**: 629
Nasal splints
prostheses **113**: 358, **113**: 725
and Wegener's granulomatosis **104**: 426
Nasal spray
single use disposable, development **107**: 20
Nasal stenosis
burns **104**: 497
Nasal surgery
altered dental sensation **107**: 1011
laser mucotomy **109**: 296
nasal packing **107**: 902, **108**: 564
post-operative nasal medication **109**: 618
xylocaine test as a prognostic aid for surgery in Sluder's neuralgia **109**: 193
Nasal teeth 106: 366
Nasal tip
angioleiomyoma **107**: 448
Nasal tuberculosis 109: 324
Nasal turbinate mucosa
and sinus mucosa, nasal polyps, mast cell quantitation **107**: 418
Nasal vestibule
closure in atrophic rhinitis, new non-surgical technique **112**: 543
solitary keratoacanthoma **105**: 306
squamous cell carcinoma **106**: 332
Nasoantral window assessment
acoustic rhinometry **108**: 567
Nasoendoscopy
guided removal of foreign bodies from base of tongue and vallecula **109**: 534
milk, assessment of dysphagia **106**: 525
snoring **109**: 1163
Nasogastric feeding tube
endoscopic placement **112**: 644, **113**: 839
Nasolabial cyst 113: 747
Nasolabial flap
reconstruction of floor of mouth defects **107**: 320
Nasolacrimal duct obstruction
prophylaxis using silicone stent, sinus surgery **105**: 299
Nasolaryngoscopy
epistaxis **105**: 17
Nasopharyngeal airway
adenoids **113**: 899
Nasopharyngeal atresia
dyskeratosis **106**: 996
Nasopharyngeal branchial cyst 107: 453
resection via endonasal approach **109**: 139
Nasopharyngeal cyst
tuberculosis, diagnostic aspiration using nasoendoscope **108**: 505
Nasopharyngeal infections
Corynebacterium ulcerans diphtheria **106**: 824
eustachian tube and otitis media **108**: 95
microbial flora, children after tonsillectomy and adenoidectomy **108**: 763
tuberculosis **106**: 1079
Nasopharyngeal masses
angiofibroma **110**: 962
pre-operative embolization **107**: 514
biopsy in adult unilateral glue ear **110**: 62
brachytherapy **107**: 115
carcinoma **111**: 724
actinomycosis **111**: 163
antiangiogenic therapy with AGM-1470 (TNP-470) **112**: 849
combined therapy **107**: 201
diabetes insipidus, and hypercalcaemia **104**: 43
epidemiology, Jordan **113**: 422
Epstein–Barr virus BHRF1 **111**: 1147
HIV-positive patient **107**: 149
and human papillomavirus **105**: 288
Jordan **105**: 432
leukemoid reaction **111**: 66
middle ear pressures **109**: 390
neuroendocrine **105**: 1031
papillary **105**: 853
radiotherapy and auditory brain stem evoked responses **106**: 887
secondaries at porta hepatis, with obstructive jaundice **104**: 41
SEM **105**: 349
spinal metastases **105**: 772
status after radiotherapy **106**: 1055
chondrolipoma **112**: 75
choroid metastasis **112**: 667
cyst, simulating Kaposi's sarcoma, HIV infection **104**: 498
delayed diagnosis **113**: 633
detection by *in situ* hybridization **106**: 345
following radiotherapy **110**: 19, **110**: 121, **110**: 496
from pituitary **113**: 1109
Hodgkin's lymphoma **112**: 103
lipoma **110**: 275

metastasis to thyroid **108**: 886
otological findings **113**: 558
radiation effects **113**: 222, **113**: 815
retropharyngeal abscess **113**: 70
solitary fibrous tumour **105**: 213
temporal bone neoplasms post irradiation **113**: 222
tomography **110**: 19
trigeminal and mandibular nerves **110**: 394
vagus and accessory nerves **110**: 987
see also Nasal masses; Paranasal *and other named* sinuses
Nasopharyngeal tuberculosis 113: 928
Nasopharyngoscopy
foreign bodies **106**: 709
Nasopharynx
cephalometric analysis **105**: 71
oncocytic metaplasia, secretory otitis media **104**: 39
rhinoscopy instrumentation **110**: 1055
Nasopharynx dimensions
children, association with recurrent acute otitis media **108**: 299
Nasotracheal intubation
nasal obstruction **108**: 991
Nd:YAG laser
glomus tympanicum tumour **107**: 236
Nebulizers
foreign bodies **110**: 679, **110**: 1164
Nebulizers and inhalers
tracheal stomas or tracheostomy tubes **113**: 762
Neck
clunking **109**: 1217
necrotizing fasciitis **106**: 1008
normal and pathological anatomy **113**: 501
and vertebral artery, penetrating injuries **106**: 925
see also Head and neck
Neck dissection
aberrant central venous catheter **105**: 491
audit **105**: 760
bilateral neck dissection, complication, blindness **104**: 154
functional results **112**: 1176
J incision **112**: 55
laryngeal cancer
and hypopharyngeal cancer **112**: 438
with limited metastatic disease **112**: 1031
minimizing complications **113**: 101
non-conventional squamous carcinoma of larynx **113**: 619
nutritional support, patients with chylous fistula **105**: 1052
and post-operative irradiation, advanced glottic cancers **108**: 26
transverse sinus thrombosis, and venous infarction of brain **112**: 88
Neck masses
abscesses **108**: 138
associated with jugular vein thrombosis **105**: 966
actinomycosis **107**: 1169
chronic inflammatory mass, malakoplakia **106**: 173
cystic neck lesions, ultrasound **107**: 245
ectopic salivary gland **109**: 669
heterotopic pleomorphic adenoma **109**: 445
jugular vein, phlebectasia **113**: 858
laryngeal callus **108**: 354
leaking aortic aneurysm presenting as a recurrent neck swelling **109**: 163
multiple, extranotochordal chordoma **107**: 942
multiple ganglioneuroma **106**: 277
nerve sheath tumours, accessory nerve **113**: 942
parapharyngeal lipoma **113**: 935
parathyroid cysts **113**: 73
post radiation primary intranodal leiomyosarcoma **109**: 80
Salmonella typhimurium, thrombosis of jugular veins **113**: 1122
see also Head and neck masses
Neck muscles
myositis ossificans **113**: 856
Neck pathology
complicating pharyngeal pouch surgery **107**: 1163
Neck spaces
infections **106**: 455
Necrobacillosis
cervical abscess **106**: 374
pharyngotonsillitis **108**: 1097
Necrotizing
see also Radiation injury
Necrotizing external otitis
Aspergillus fumigatus, in AIDS **112**: 98
Necrotizing fasciitis
after peritonsillar abscess **113**: 759
cervical, and radiotherapy **112**: 298
craniofacial, secondary to sinusitis **112**: 371
neck **106**: 1008
peritonsillar abscess **110**: 887
tonsillitis **108**: 435
Necrotizing lymphadenitis
Kikuchi's disease of neck **112**: 898
Necrotizing palisading granuloma
nasal **107**: 656
Necrotizing sialometaplasia 106: 569
Needle biopsy 107: 543
Nelson's syndrome
ectopic pituitary adenoma **111**: 565
Nematodes
anisakiasis of tonsils **110**: 387
Neonatal stridor
herpes simplex infection of larynx **112**: 1192
Neonates
formal reintubation, subglottic stenosis **108**: 474
giant enterocystoma of tongue **104**: 814
maxilla, osteomyelitis **107**: 627
palatal symmetry, and nasal septum deformity **105**: 424
periorbital abscess and ethmoiditis **107**: 1043
respiratory distress, hamartoma of larynx **111**: 166
subglottic cyst **105**: 222
upper airway obstruction caused by chlamydial rhinitis **109**: 58
vallecular cysts, and failure to thrive **106**: 448
see also Infants
Nepal
Britain Nepal Otology Service (BRINOS) **105**: 1113
epidemiology, hearing loss and ear pathology **107**: 395
Nerve regeneration 113: 967
Nerve sheath tumours *see* Schwannoma
Neuralgia
geniculate ganglion **113**: 945
Neurectomy
bilateral transnasal vidian, chronic rhinitis **108**: 569
posterior fossa **105**: 1002
for tinnitus **105**: 1099, **105**: 1101, **105**: 1102, **105**: 1106
tympanic, parotid sialectasis management **109**: 1155
vestibular infralabyrinthine approach **106**: 780
Neurilemmoma
extradural hypoglossal, extended posterolateral approach **112**: 1052
laryngeal, thyrotomy **113**: 346
paranasal sinuses **113**: 585
submaxillary hypoglossal **107**: 953
tonsil **113**: 585
vagus nerve **110**: 485
Neurinoma/neuroma
trigeminal, with trismus **113**: 1112
see also Acoustic neurinoma
Neuro-axonal recruitment
selective compression **104**: 185
Neuroblastoma 112: 446, **112**: 628
facial nerve paralysis **110**: 151
olfactory nerve, radiotherapy **110**: 1012
somatostatin receptor imaging **110**: 1161
Neurobrucellosis
sensorineural hearing loss **107**: 1034
Neuroectodermal tumour
infancy
FNA **113**: 581
maxilla **112**: 61
melanotic **107**: 1045
masseter muscle **110**: 1179
melanotic, squamous and occipital bone **107**: 843
Neuroendocrine carcinoma
and arytenoid carcinoma **105**: 373
larynx **105**: 1031, **112**: 710
multiple skin metastases **108**: 272
post-aural skin region **106**: 258
Neuroendocrine tumours
head and neck **104**: 504
larynx, diagnosis and treatment **112**: 827

Neurofibromatosis
acoustic neuroma patient **110**: 570
bilateral acoustic, genetic and audiological study of patients and families **107**: 6
cervical vagus nerve **106**: 643
diffuse, MRI and X-ray CT **110**: 182
larynx **110**: 385
paediatrics **110**: 1065
obstruction of external auditory meatus **111**: 145
salivary gland neoplasms **113**: 938
schwannoma **110**: 634, **113**: 1034
submandibular gland **110**: 1173
supraglottic larynx, childhood **108**: 156
type-1, meningocele **106**: 463
type-2
absence of gender effect on vestibular schwannomas **109**: 830
cochlear implantation **113**: 458
auditory rehabilitation **113**: 161
hearing restoration **109**: 385
supraregional care **107**: 401
Neurological pathology
acute tonsillitis **111**: 274
false-positive MRI **107**: 465
Neuro-otological surgery
ionameric bone cement **106**: 949
Neurorrhaphy
recurrent laryngeal nerve, dogs **110**: 748
Neurosurgery
hearing loss, low cerebrospinal fluid pressure **108**: 637
Neutropenia
fatal cyclical, tonsillitis and bilateral cervical abscesses **105**: 487
secondary to virus-associated haemophagocytic syndrome, pseudomonal supraglottitis **106**: 739
Nigeria
Nasal septal haematoma **106**: 396
Nijmegan study
cochlear implantation **111**: 1008
Nitro-blue tetrazolium
bronchoalveolar lavage **109**: 859
Nodose ganglion
cat, CGRP-immunoreactive cells **107**: 916
Noise exposure
asymmetrical hearing loss **109**: 291
ear surgery, drill-generated noise levels **105**: 732
hearing loss **112**: 1154
mechanisms **112**: 1154
motorcyclists **109**: 599
non-explosive blast injury **111**: 1137
hyoid bone **109**: 1217
speech test procedure **106**: 105
Noise studies
decibel measurement **107**: 985
Non-accidental injury
pharyngeal trauma **109**: 1168
Non-Hodgkin's lymphoma
head and neck **104**: 972
in HIV-positive patient **109**: 751, **112**: 77, **112**: 982
involving tonsil **105**: 445
lacrimal sac, pansinusitis **112**: 969
larynx **111**: 571
primary paranasal sinus, cavernous sinus syndrome **112**: 777
temporal soft tissue swelling **110**: 161
Non-steroidal anti-inflammatory drugs
secondary tonsillectomy haemorrhage **113**: 28
Non-tuberculous mycobacterial infections
salivary gland masses in children, management **109**: 525
Nosal masses
epidemiology, Kenya **106**: 337
Nose
leukaemic cell infiltration **106**: 261
Nottingham System
self care tracheostomy **106**: 723
Nucleolar organizer regions
maxillary sinus tumours **111**: 38
and myoepitheliomas, DNA content and clinical course **106**: 616
Wegener's granulomatosis **111**: 825
Nutritional support
neck dissection **105**: 1052

Oat cell carcinoma 107: 559
Obliterative otosclerosis 105: 899, **113**: 512
Obstructive jaundice
with nasopharyngeal carcinoma secondaries at porta hepatis **104**: 41
Obstructive sleep apnoea syndrome *see* Sleep apnoea
Occipital artery ligation
arteriovenous fistula and pulsatile tinnitus **104**: 421
Occipital bone
fractures, acute bilateral vestibulo-cochlear dysfunction **108**: 54
melanotic neuroectodermal tumour of infancy **107**: 843
Occupational diseases
rhinitis **109**: 1094
pathogenesis **109**: 104
Octreotide
receptor imaging of olfactory neuroblastoma **110**: 1161
Oculo–genital–laryngeal (Opitz/G) syndrome 109: 244
Oculomotor nerve palsy
sphenoid sinus mucocele **111**: 471
Oculopharyngeal myopathy
with sensorineural hearing loss **110**: 567
Odontogenic ghost cell tumour
maxilla **108**: 269
Odontogenic tumours
Pindborg tumour in Malaysians **110**: 757
Odours
stimulation in humans **110**: 652
Oesophageal cancer
gastric tube transposition, hypopharynx and cervical oesophagus **108**: 33
Oesophageal dilatation
presenting as stridor **106**: 751
Oesophageal fistula
pharyngo-oesophageal post surgery **109**: 1215
Oesophageal foreign bodies 107: 153
metal detection of razor blade **104**: 435
Oesophageal graft
colonic interposition, adenocarcinoma **108**: 80
Oesophageal haemangioma
positive cough impulse **113**: 172
Oesophageal heterotopic gastric mucosa 112: 979
Oesophageal intramural pseudodiverticulosis 104: 911
Oesophageal obstruction
abdominal shotgun wound **111**: 177
caustic injuries, stents **110**: 1041
children, balloon dilatation **110**: 683
stenosis, paediatrics **110**: 683
stricture repair **111**: 772
see also Foreign bodies
Oesophageal perforation
pregnancy-induced vomiting **107**: 1059
Oesophageal stricture
simultaneous with laryngeal stricture, dilatation with two T-tubes **108**: 42
Oestrogen receptors
acoustic neuroma **104**: 865
Oestrogens
diet-modified metabolism **109**: 873
replacement therapy, sudden hearing loss **110**: 1148
OK-432
chemotherapy, head and neck neoplasms **110**: 449
Olfactory function
beconase nasal spray post-surgery **109**: 941
brain neoplasms, hyposmia **113**: 750
odour stimulation in humans **110**: 652
Olfactory mucosa
injury to olfactory bulb **104**: 959
nasal cavity **112**: 11
Olfactory nerve
neuroblastoma radiotherapy **110**: 1012, **110**: 1161
Olivocochlear efferent system
medial (MOES), primates, interdependence and micromechanics of cochlea **107**: 883
Ollier's disease 105: 148
and Maffucci's syndrome **113**: 861

Oncocytes
larynx, multiple oncocytic cysts **109**: 1226
Oncocytic differentiation
salivary gland masses **109**: 569
Oncocytic metaplasia
nasopharynx, secretory otitis media **104**: 39
Oncocytoma
immunohistochemistry and ultrastructure **107**: 69
larynx **104**: 346
nasal cavity **111**: 671
submandibular gland **112**: 106
thyroid **105**: 143
Oncogenic osteomalacia
head and neck tumours **112**: 389
Oncology in Focus
acute labyrinthine failure **112**: 193
non-Hodgkin's lymphoma, HIV infection and AIDS **112**: 982
radiation injury, head and neck cancer **109**: 346
squamous cell carcinoma, amplification of Int-2 gene, head and neck neoplasms **109**: 72
Operating microscope
alternative in temporal bone laboratory **111**: 958
Opitz oculo–genital–laryngeal (Opitz/BBB/G) syndrome 109: 244
Optic nerve
head injury, fracture line **105**: 203
maxillary sinus, bilateral salivary gland neoplasms **105**: 584
transethmoid decompression, head injury **105**: 205
Optic neuritis
with malignant otitis externa **112**: 274
Oral epulis
difficult intubation and fatal respiratory arrest **106**: 444
Oral masses 109: 787
angiomatous malformation of floor of mouth **109**: 665
carcinoma
prognosis, host factors **106**: 399
surgery **106**: 127
and khat **105**: 643
lipoma, spindle-cell variant **113**: 587
malignant fibrous histiocytoma **109**: 680
mandible involvement **104**: 968
mandibulotomy **107**: 316
nasolabial flap, reconstruction of floor of mouth defects **107**: 320
premalignant lesions, photodynamic therapy **107**: 1140
squamous cell carcinoma, prognostic factors **113**: 446
see also Specific locations
Oral mucocutaneous allergic vasculitis
propylthiouracil **113**: 477
Oral reconstruction
floor of mouth
advancement cheiloplasty **108**: 486
nasolabial flap **107**: 320
free jejunal patch flaps **113**: 680
Oral surgery
antiseptic mouthwash **108**: 973
Oral ulcer
ANCA, mucocutaneous allergic vasculitis, propylthiouracil cause **113**: 477
Orbit
see also Foreign bodies
Orbital abscess
CT demonstration **105**: 1086
ethmoiditis in neonate **107**: 1043
Orbital complications
sinusitis **111**: 719
Orbital decompression
dysthyroid eye disease **111**: 946
in Graves' disease **110**: 670
Orbital fractures
blow-out fracture of floor, coronal CT scan **107**: 161
exophthalmos following nasal tamponade **110**: 265
Orbital protrusion
during endoscopic sinus surgery **113**: 754
Orbital sinusitis
management of complications **109**: 300
Orf
of pinna **105**: 947
Organophosphorus poisoning
laryngeal paralysis **112**: 81
ORL-HNS and associated specialities
ENT in 20thC **113**: 1060
Ornidazole
surgery, head and neck masses **106**: 409
Oroantral fistula
closure, and palatal defects, pedicled buccal fat pad (BFP) and palatal rotating flaps **113**: 834
transantral ligation of internal maxillary artery for epistaxis **111**: 468
Oronasal transfer of nasogastric tube
following endoscopic placement **112**: 644
Oropharyngeal disorders
actinomycosis of vallecula **109**: 154
anterior cervical pain syndromes: hyoid, thyroid and cricoid cartilage syndromes, treatment with triamcinolone acetonide **109**: 49
Oropharyngeal flora
children after tonsillectomy and adenoidectomy **108**: 763
patients with head and neck cancer, radiotherapy effects **107**: 222
Oropharyngeal masses
carcinoma
and human papillomavirus **105**: 288
major surgery **106**: 127
recurrence after radiotherapy **105**: 24
clinicopathological and immunohistochemical study **109**: 459
foreign bodies, radiographic assessment **109**: 452
giant hamartoma **110**: 480
glomus tumour **109**: 63
goitre **113**: 170
haemangioma, positive cough impulse **113**: 172
hairy polyp **110**: 288
mandibulotomy **107**: 316
pleomorphic adenoma of soft palate **109**: 240
polypoidal carcinosarcoma **109**: 459
recurrence, salvage brachytherapy and salvage surgery following radiotherapy **109**: 45
schwannoma **109**: 883, **110**: 170
sebaceous gland carcinoma **110**: 500
surgery **112**: 355
Oropharyngeal reconstruction 113: 680
Oropharyngeal trauma
penetrating injuries **106**: 813
routine ear, nose and throat procedures **108**: 403
Oropharyngeal wall
tuberculosis **113**: 1029
Oropharynx
cytomegalovirus **105**: 739
Ortner's syndrome 112: 377
secondary to cardiothoracic disease **111**: 869
Osseointegrated implants
management of childhood ear abnormalities, Birmingham **107**: 502
maxillary sinusitis **104**: 333
one-stage procedure **109**: 593
screw avulsion **105**: 573
Ossicle selection
cholesteatomatous ear disease **111**: 807
Ossicles
'stored' autologous, histology **106**: 17
Ossicular erosion
chronic suppurative otitis media **107**: 12
Ossicular replacement prosthesis 109: 1048
Ossiculoplasty 105: 529
autografts, and synthetic prosthetic materials, comparison of results **106**: 692, **106**: 688
bone grafts
audit **107**: 695
graft mass and hearing change at different frequencies **107**: 690
surgical techniques and hearing results **107**: 686
styloid process **108**: 111
Ossification
cochlear implantation **113**: 811
epiglottis **106**: 180
fibroma, paranasal sinuses **112**: 964
fibromyxoma, head and neck, clinicopathological and immunohistochemical study **107**: 75
myositis ossificans **113**: 856

Ossification (continued)
pleomorphic adenoma, maxillary antrum **106**: 50
stylohyoid ligament, fracture **113**: 854
thyroglossal cyst, embryological significance **108**: 168
Osteitis
external auditory meatus **111**: 269
Osteoblastoma
nasal cavity **107**: 737, **111**: 865
temporal bone **109**: 565
Osteoblasts
suppression **110**: 328
Osteochondroma
temporomandibular joint **107**: 742
tongue **104**: 138
Osteogenic sarcoma
tongue **113**: 376
Osteoma
external auditory canal **105**: 844
external auditory meatus, presenting as aural polyp **107**: 935
internal auditory canal **110**: 158
unilateral hearing loss **106**: 905
middle ear **104**: 803
paranasal sinuses, bone remodelling **107**: 633
Osteomalacia
head and neck tumours **112**: 389
Osteomyelitis
cervical spine, following laryngectomy **106**: 1096
complication of tracheo-oesophageal puncture **107**: 242
maxilla, neonates **107**: 627
skull base, interpreted as malignancy **113**: 775
temporomandibular joint, malignant otitis externa **113**: 451
Osteopetrosis
vestibular disease **110**: 462
Osteoradionecrosis
mandible, hemimandibulectomy **104**: 305
Osteosarcoma
ethmoid, recurrent epistaxis and proptosis **110**: 676
mandible **104**: 335
nasal cavity and paranasal sinuses **108**: 947
sphenoid bone **109**: 1101
Osteosclerosis
laser stapedotomy **113**: 413
Osteotomy
Le Fort I, encephalocele, sphenoid sinus **112**: 779
Ostia
mucus circulation **113**: 865
Otalgia
carotid artery aneurysm **109**: 865
drug-induced **110**: 466
tympanic neurectomy **104**: 114
Otic capsule
pathology **104**: 83
Otitic hydrocephalus 111: 757
Otitis externa
acute, causes **107**: 898
alternative to regular dressings **109**: 101
audit of management in an ENT casualty clinic **109**: 130
Bing–Neel syndrome, Waldenstrom's macroglobulinaemia **108**: 492
carcinoma, temporal bone **106**: 908
ear canal and temporomandibular joint fistula **106**: 994
ear syringing **104**: 709
EMLA cream **104**: 887
following mastoidectomy **113**: 1095
in HIV and AIDS **110**: 770
hypersensitivity to corticosteroids **107**: 597
implantable antimicrobial release **105**: 252
infant **104**: 488
laser treatment **111**: 1126
management policy **106**: 5
necrotizing
Aspergillus fumigatus, in AIDS **112**: 98
surgical management **108**: 101
occupational in chicken catchers **111**: 366
with optic neuritis **112**: 274
osteomyelitis interpreted as malignancy **113**: 775
radiation injury **104**: 458
temporomandibular joint osteomyelitis **113**: 451
topical preparations **105**: 842
see also Ear, external
Otitis media
actinomycosis **112**: 800
Aspergillus fumigatus, CT and MRI, in AIDS **112**: 98
bacterial meningitis **111**: 913
bacteriology **105**: 341
cochlear implantation **111**: 228
colonization of infant pacifiers **111**: 614
epidemiology
Greenlandic Inuits **110**: 1114
Hong Kong **111**: 804
and eustachian tube **108**: 95
electron microscopic study **107**: 651
Fusobacterium necrophorum meningitis **105**: 119
Luc's abscess **111**: 461
previous mastoidectomy **110**: 836
recurrent acute
association with nasopharynx dimensions in children **108**: 299
during 0–3 years, language development follow-up **107**: 407
respiratory tract viruses **105**: 337
retraction pockets **105**: 525
sixth nerve palsy **110**: 872
tubercular **111**: 58
Otitis media, suppurative
abnormal tympanograms, schoolchildren in Hampshire schools **108**: 930
ABR threshold after suction aspiration **109**: 726
alternative to regular dressings **109**: 101
Armstrong tube, vs Goode T-Tube **104**: 608
assessment using Glasgow Benefit Plot **108**: 733
bacterial attachment *in vivo* to epithelial cells, nasopharynx **106**: 111
bacterial findings, quantitative analysis **104**: 749
bacteriology **110**: 315, **110**: 950
biopsy **110**: 62
capsaicin **113**: 114
cellular mechanism of ossicular erosion **107**: 12
Chlamydia pneumoniae **106**: 490
cleft palate **106**: 788
clinical presentation, changes **112**: 1034
CT scanning **105**: 990
daily tympanometry **104**: 937
drug therapy **109**: 811, **110**: 309
dysequilibrium **104**: 682
early complications of surgery **113**: 803
erythromycin and ventilating tubes **104**: 200
extracranial and intracranial complications **107**: 999
facial nerve palsy, immunocompromised patient **109**: 755
grommet insertion, children **112**: 732
hearing aids **113**: 314
hearing disability
approach **110**: 121
surgical management **107**: 284
hearing loss, endotoxin origin **108**: 310
lateral cephalometric analysis **105**: 71
marine halophilic *Vibrio* sp. **109**: 1082
maxillary sinusitis, children **108**: 842
oncocytic metaplasia of nasopharynx **104**: 39
orthodontic perspective **106**: 7
pneumatic otoscopy, tympanometry and pure tone audiometry, as predictors **106**: 600
prevalence and natural history, Maori children **105**: 257
prognostic sign for recurrence **106**: 974
proteins, compared with mast cell proteins **109**: 1146
pure tone audiometry, and speech audiometry **107**: 787
secondary to mastoid surgery, cerebellar encephalocele **104**: 982
serum antibodies against respiratory tract viruses **105**: 337
subtotal petrosectomy and external canal overclosure **108**: 197
topical aminoglycosides **113**: 10
trimmed Shah permavent tube **108**: 303
tubotympanic CSOM, ear swabs **104**: 460
tympanic membrane atelectasis **109**: 495
tympanosclerosis and hearing loss **113**: 1076
tympanostomy **113**: 207

unusual prevalence of complications, young adults **106**: 874
ventilation **109**: 1151, **110**: 531
mini grommets **109**: 922
parental perception of outcome **113**: 1068
teaching materials **112**: 642
tubes **105**: 161, **105**: 614, **105**: 896
vestibular labyrinth **105**: 987
Welch Allyn Audioscope and Microtymp acuracy **106**: 600
without cholesteatoma, exenteration of rest cells, radical revision mastoidectomy **113**: 710
see also Tympanoplasty
Oto-mastoiditis
actinomycosis **111**: 1069
Otogenic intracranial abscess
risks **104**: 468
Otogenic pneumocephalus 112: 1179
Otolaryngology
in Byzantium (AD 324-1453) **110**: 913
children, routine admissions **110**: 557
clinical trials, reference standards **112**: 460
evidence-based medicine **111**: 415
image processing, stereotaxic techniques **110**: 322
litigation **104**: 162
Minoan era **107**: 879
on-line resources **112**: 854
peer review, audit of ENT day-case surgery **112**: 161
reference standards **112**: 460
surgeon in millennium, molecular genetics **112**: 4
X-ray helical computed tomography **110**: 604
Otological manifestations
Wegener's granulomatosis **108**: 144
Otology
Adam Politzer's influence **110**: 723
Otomycosis
North Iraq **104**: 387
Otoplasty
cartilage-sparing **111**: 424
deep conchal bowl **110**: 864
ear complications **112**: 531
head bandaging **108**: 410
Otorhinolaryngological subdural empyema 104: 118
Otorrhoea
grommets, ventilation tubes, and swimming **107**: 190
Otosclerosis
and auditory exostoses, ancient Europeans **107**: 489
cochlear implantation **111**: 262
genetics **111**: 109
labyrinthine ossification **105**: 621
obliterative **105**: 899
obliterative surgery **113**: 512
spiral ligament hyalinization, and hearing loss **104**: 952
stapedectomy **112**: 158
Singapore **109**: 225
stapes surgery **113**: 417
laser stapedotomy **113**: 413
obliterative **113**: 512
statistical analysis, hearing loss **104**: 952
tympanocochlear scintigraphy (TCS) **109**: 1051
water fluoridation **111**: 20
Otoscopy
clinical and histological correlation **106**: 307
Ototoxicity
aminoglycosides, active mucosal chronic suppurative otitis media **113**: 10
carboplatin, animal model **107**: 585
cisplatin in children, skin and eye pigmentation **109**: 926
gentamicin **105**: 222, **105**: 999
continuous ambulatory peritoneal dialysis **107**: 681
mianserin hydrochloride **105**: 475
platinum **105**: 7
Oval window
deep **105**: 721, **105**: 725
Ovarian carcinoma
metastasis to larynx **104**: 48
Oximetry
children with croup **105**: 295
Oxygen desaturation
nocturnal, nasal packing **105**: 109
P53, MDM-2, cyclin D1 and Ki67
progression from low-grade dysplasia to laryngeal carcinoma **112**: 455
P53
nucleolar organizer regions, maxillary sinus tumours **111**: 38
P53 oncoprotein
and human papilloma virus **110**: 742
Pachyonychia congenita syndrome
keratosis **110**: 1145
Pain
anterior cervical pain syndromes, hyoid, thyroid and cricoid cartilage syndromes, treatment with triamcinolone acetonide **109**: 49
maxillary sinus carcinoma, T-classification and direction of tumour spread **106**: 804
post-tonsillectomy **109**: 209
selective diathermy haemostasis **110**: 446, **110**: 1038
steroids **107**: 605, **110**: 1038
Palatal defects
and nasal septum deformity, neonates **105**: 424
and oroantral communication closure **113**: 834
rotating flaps, and buccal fat pad (BFP) **113**: 834
Palatal masses
adenocarcinoma **105**: 309
adenomatoid hyperplasia **110**: 167
ameloblastoma **104**: 252
carcinoma **106**: 130
flow cytometric and clinicopathological analysis **107**: 858
haemangioma, child **112**: 677
and optic nerve, maxillary sinus, and bilateral salivary gland neoplasms **105**: 584
resection with CO_2 laser **104**: 20
small lymphocytic lymphoma, involvement of parotid and submandibular glands bilaterally **105**: 584
traumatic haematoma **105**: 1116
Palatal muscles
myoclonus affected by neck position **109**: 61
Palatal myoclonus
cause of dysphagia and dysarthria **107**: 746
Clostridium botulinum toxin **107**: 208
Palatal tonsil lymphocytes
Cowden's disease **106**: 640
Palate
amalgam tattoo, energy dispersive x-ray analysis **106**: 834
isolated bilateral paralysis **106**: 839
palatal sign, radiography **105**: 968
soft, surgery **109**: 849
Palatine tonsillar metastasis
from colon carcinoma **108**: 449
Palatoplasty
snoring and sleep apnoea **111**: 1151
Pallister–Killian syndrome 108: 669
Pancreatic neuroendocrine carcinoma
and arytenoid carcinoma **105**: 373
Pancreatitis, acute
primary hyperparathyroid adenoma **110**: 602
Pantoprazole
chronic posterior laryngitis **113**: 734
Papillary masses
adenocarcinoma
lectin receptors **107**: 600
middle ear **104**: 915
nasopharynx **105**: 853
carcinoma
occult **109**: 1109
tall cell variant, ectopic thyroid tissue in trachea **113**: 183
thyroglossal duct cyst **109**: 1124
thyroglossal duct remnant, with normal thyroid gland **107**: 1174
cystadenomatosis, larynx **106**: 656
endothelial hyperplasia (Masson's tumour), maxillary sinus **112**: 500
middle ear **105**: 950
Papillary thyroid carcinoma 110: 704
as branchioma **110**: 490
Japan **110**: 657
Papilloedema
complication of mastoidectomy **110**: 878

Papilloma
hypopharyngeal inverted **104**: 432
intraductal, parotid duct cyst **110**: 277
inverted, lectin receptors **107**: 600
laryngeal neoplasms in non-irradiated, non-smoking patient **109**: 762
transitional, middle ear **106**: 628
Papillomatosis
argon plasma coagulation **111**: 381
carbon dioxide laser **112**: 565
Cuban programme **111**: 134
juvenile aggressive, involving total respiratory tract **112**: 1101
juvenile respiratory, ribavirin **107**: 423
laryngeal
development in paranasal sinuses **109**: 238
florid, following remission of 30 years **107**: 636
and laryngeal carcinoma **110**: 75
nose and paranasal sinuses, endoscopy **112**: 758
recurrent **111**: 381
Manchester 1974–1992 **108**: 226
respiratory, ribavirin **107**: 423
sleep apnoea syndrome **111**: 976
and squamous cell carcinoma prophylaxis, sex hormone metabolism **109**: 873
upper aerodigestive tract **111**: 215
Papillomavirus
diet-modified sex hormone metabolism **109**: 873
laryngeal neoplasms, laser surgery **110**: 1031
and p53 oncoprotein, verrucous carcinoma of larynx **110**: 742
type 18, recurrent laryngeal nerve papillomatosis and laryngeal carcinoma **110**: 75
Paraffinoma
rhinoplasty nasal packing **110**: 785
Paraganglioma 113: 978
external auditory canal **107**: 228
familial multicentric **105**: 376
jugulo-tympanic, frozen section diagnosis **107**: 755
laryngeal **110**: 519
child **113**: 62
clinico-pathological classification **106**: 635
maxillary sinus **104**: 248
multiple, management **107**: 538
parathyroid gland **110**: 196
vagus nerve **110**: 688
Paranasal sinus imaging
CT scanning **105**: 20, **105**: 181
magnetic resonance **105**: 278
subtraction MRI **105**: 628
tomography for chronic rhinosinusitis **110**: 641
Paranasal sinus masses
adenocarcinoma **110**: 805
B-cell non-Hodgkin's lymphoma **108**: 263
chondrosarcoma, osteosarcoma, fibrosarcoma **108**: 947
ethmoid schwannoma **105**: 578
frontal carcinoma **105**: 121
haemangiopericytoma **113**: 199
laryngeal papillomatosis, development of papillomata **109**: 238
leiomyoma **107**: 740
maxillary antrum **105**: 370, **105**: 696
metastases **109**: 986
from prostatic carcinoma **107**: 629
from thyroid carcinoma **111**: 647
mucoepidermoid carcinoma, maxillary antrum **105**: 370
myxoma **108**: 679
neoplasms, lymph node and distant metastases **109**: 304
neurilemmoma **113**: 585
non-Hodgkin's lymphoma **112**: 777
ossifying fibroma **112**: 964
osteoma, bone remodelling **107**: 633
papilloma **112**: 758
radiotherapy, for nasopharyngeal carcinoma, CT scanning **110**: 19
sarcoma **105**: 186
schwannoma **107**: 146
small lymphocytic lmphoma **105**: 584
Paranasal sinus surgery 110: 272
electrocoagulation **110**: 261
endoscopic sinus surgery **104**: 477, **112**: 986
endoscopic surgery
with CT **104**: 477, **112**: 986
deviated nasal septum **112**: 934
mucoceles **112**: 36
oro-nasal transfer of nasogastric tube **112**: 644
resection of inverted papilloma **112**: 758
uncinectomy **112**: 547
visual pathways **112**: 622
functional endoscopic (FESS) **110**: 31, **110**: 261
midfacial degloving in nasal neoplasms **113**: 885
modification to brow incision for access to anterior skull base **109**: 134
Paranasal sinuses 104: 690
aquatic evolutionary theory **106**: 214
aspergillosis **107**: 773, **111**: 1168
disease complications **109**: 1061
endoscopic anatomy **113**: 122
enlargement in Sturge–Weber syndrome **113**: 177
fibrous dysplasia **112**: 964
foreign bodies **109**: 1097
inflammatory changes **110**: 649
mucocele **113**: 1106
endoscopy **112**: 36, **112**: 840
multiple abnormalities, patients with nasopharyngeal carcinoma **110**: 23
multiple primary malignancies **104**: 696
and nasal cavity, cysts **110**: 1157
rhinocerebral mucormycosis **112**: 367
transorbital penetrating injury **112**: 1202
Parapharyngeal lipoma 113: 935
Parapharyngeal masses
abscess **105**: 1025
associated with second pharyngeal pouch **107**: 456
elective tonsillectomy **111**: 578
external auditory meatus foreign body **111**: 1086
fibrous dysplasia and cholesteatoma, temporal bone **108**: 51
foreign bodies, imaging and surgical exploration **113**: 683
and torticollis **104**: 829
carotid sinus syndrome **107**: 955
chondrosarcoma **105**: 484
chordoma **106**: 549
lipoma **106**: 279
neurofibromas **106**: 243
occult thyroid carcinoma **109**: 1204
pseudolymphoma **105**: 137
schwannoma **105**: 384, **112**: 883
von Recklinghausen's disease **107**: 848
soft tissue chondroma **112**: 294
solitary fibrous tumour **108**: 344
tumour presenting as recurrent uvular oedema **107**: 640
Parapharyngeal myxoid liposarcoma 113: 179
Parapharyngeal space
cysts **108**: 795
emphysema, temporal bone trauma **112**: 301
fibromatosis **108**: 1102
melioidosis, diabetic **105**: 582
retrostyloid, third branchial cleft cyst **105**: 790
transpalatal approach **111**: 159
Parathyroid adenoma 111: 459
extracapsular haemorrhage **111**: 585
power Doppler, hypercalcaemic crisis **112**: 796
ultrasound combined with fine-needle aspiration cytology **107**: 543
Parathyroid cyst
mediastinum **104**: 56
neck mass **113**: 73
Parathyroidectomy
for secondary hyperparathyroidism in chronic renal failure **105**: 562
Parenchymal pulmonary endometriosis 105: 235
Parotid duct
carcinoma **105**: 780
bilateral chronic sialadenitis **113**: 686
cyst, intraductal papilloma **110**: 277
Parotid duct stone
removal by dormia basket **108**: 699
Parotid gland *see* Salivary gland
Parotidectomy
great auricular nerve **111**: 556

Parotitis
diffuse tuberculous **106**: 1094
and facial paralysis **110**: 91
pneumoparotitis, adolescent **106**: 558
tuberculous, role of surgery **110**: 96, **110**: 976
Pasteurella multocida
canine, meningitis following mastoidectomy **105**: 571
Pathology in Focus
acinic cell neoplasms, undifferentiated spindle transformation **108**: 902
acoustic schwannoma, traumatic origin **104**: 270
actinomycosis, middle ear **112**: 800
adenocarcinoma
larynx, metastasis from rectal primary **112**: 199
metastases to orbit and skin **109**: 1222
metastases to tonsil **110**: 291
oesophageal colonic interposition graft **108**: 80
paranasal sinus, intestinal type **110**: 805
submandibular gland, positive serum and tissue immunohistochemical staining for both CEA and CA-125 **108**: 719
tongue **110**: 700
adenoid cystic carcinoma
histological changes **106**: 1016
maxilla **110**: 503
adenoidal hypertrophy, HIV infection **104**: 58
adenoma, minor salivary glands **111**: 985
ameloblastoma, maxilla **105**: 971, **109**: 1019
amyloidoma, giant, tonsillar **110**: 613
angiolymphoid hyperplasia
with eosinophilia **109**: 262
with eosinophilia of parapharyngeal space **112**: 802
angiosarcoma, hypopharynx **108**: 905
B-cell lymphoma, parotid gland **110**: 811
basal cell adenocarcinoma, salivary gland, review of literature **107**: 862
basal cell adenoma, and pleomorphic, coexisting, parotid gland **111**: 182
bilateral acinic cell tumours **105**: 796
breast carcinoma metastases, external auditory canal **108**: 808
candidiasis, invasive, tonsil **111**: 1199
carcinoid tumour, laryngeal, atypical **109**: 455
carcinomatous ex-pleomorphic adenomas **109**: 677
cervical lymphomata, midline presentation **104**: 737
chondroblastoma, nose **110**: 696
chondromyxoid fibroma, ethmoid and frontal sinuses **109**: 258
chondrosarcoma, larynx **109**: 168
clear cell carcinoma, in pleomorphic adenoma of submandibular gland **108**: 529
cystadenoma, parotid gland **111**: 883
cystic lymphangioma, parotid gland **106**: 566
eccrine cylindroma, ear canal **108**: 706
epithelial odontogenic ghost cell tumour, maxilla **108**: 269
epithelial–myoepithelial carcinoma
nasal cavity **110**: 397
parotid gland, ear canal stenosis **110**: 493
ethmoid sinus, primary craniopharyngioma **112**: 403
Eustachian tube, in otitis media, EM study **107**: 651
Ewing's sarcoma, retropharynx **108**: 363
fibrous histiocytoma, larynx **112**: 1205
fine needle aspiration cytology, head and neck masses, child **106**: 755
frozen section diagnosis, jugulo-tympanic paraganglioma **107**: 755
glycogen-rich clear cell carcinoma, tongue **108**: 716
granular cell tumour, larynx **104**: 159
granuloma
complications of stapedectomy **110**: 185
plasma cell, supraglottic larynx **109**: 895
granulomatous cutaneous T-cell lymphoma, neck **106**: 563
haemangiopericytoma
nasal **105**: 593
parotid gland **106**: 659
temporal bone **104**: 998
hairy polyps **110**: 101, **110**: 288
hamartoma, tongue **107**: 363
hamartomatous polyp
benign, palatine tonsil **107**: 1074
tonsillar **105**: 1089
hamartomatous thymoma, ectopic **107**: 155
heterotopia of tonsil **110**: 611
hibernoma, parotid region **107**: 257
histiocytoma, benign, external auditory meatus **110**: 98
Hodgkin's lymphoma, nasopharynx **112**: 103
Horner's syndrome **111**: 493
hyoid bone mass, presenting with cervical nodal metastasis **107**: 967
inflammatory pseudotumour, trachea **108**: 613
Kikuchi's disease of neck, histiocytic necrotizing lymphadenitis **112**: 898
Kikuchi's necrotising lymphadenitis **105**: 496
laryngeal carcinoid, atypical, metastatic to scalp **111**: 89
leiomyosarcoma
larynx **108**: 359
parotid gland **110**: 401
post radiation primary intranodal **109**: 80
smooth muscle tumours of larynx **109**: 77
tongue **108**: 617
lipoma
larynx, review of literature **109**: 353
tongue **110**: 189
lipomatosis, minor salivary glands **112**: 895
lymph nodes, cystic metastases, from occult thyroid carcinoma **106**: 932
lymphoblastic lymphoma/leukaemia, perichondritis of pinna **112**: 592
malignant fibrous histiocytoma of mouth **109**: 680
malignant mesenchymoma, larynx **104**: 440
mantle cell lymphoma, blastic variant in Waldeyer's tonsillar ring **112**: 991
melanoma of pharynx **108**: 275
meningioma, palatine tonsil, primary ectopic **111**: 179
Merkel cell carcinoma
metastatic to tonsil **106**: 1100
pinna **111**: 1195
metastatic adenocarcinoma, temporal bone **108**: 710
midline destructive disease **112**: 307
minor salivary gland, true malignant mixed tumour **108**: 76
myofibroblastic tumour, tonsil **111**: 880
myositis, sternocleidomastoid muscle **112**: 687
myxoma, larynx, review of literature **108**: 811
nasal schwannoma, benign **106**: 1011
nasal T-cell lymphoma, Epstein–Barr virus infection **107**: 468
nasopharyngeal neoplasms, following radiotherapy **110**: 496
necrotizing palisading granuloma, nasal **107**: 656
necrotizing sialometaphasia **106**: 569
neuroectodermal tumour, masseter muscle **110**: 1179
neuroendocrine carcinoma, larynx, multiple skin metastases **108**: 272
Ollier's disease **105**: 148
oncocytic papillary cystadenomatosis **109**: 1226
larynx **106**: 656
oncocytoma
immunohistochemistry and ultrastructure **107**: 69
submandibular gland, metastasizing **112**: 106
oral neoplasms, sialadenoma papilliferum **109**: 787
ossification of epiglottis **106**: 180
ossifying fibromyxoma, immunohistochemistry **107**: 75
osteoblastoma, temporal bone **109**: 565
palatal masses, flow cytometric and clinicopathological analysis **107**: 858
palatinetonsil metastasis from colon carcinoma **108**: 449
papillary adenocarcinoma, middle ear **104**: 915
papillary carcinoma, thyroglossal duct remnant, with normal thyroid gland **107**: 1174
papillary endothelial hyperplasia **112**: 500
papillary thyroid carcinoma **110**: 704
papillomatosis, juvenile aggressive, involving total respiratory tract **112**: 1101
paraganglioma, parathyroid gland **110**: 196
parapharyngeal abscess, and torticollis **104**: 829
parotid gland, true malignant mixed tumour **104**: 360
peritonsillar abscesses, microscopy and bacterial culturing **111**: 392
plasma cell granuloma, maxillary sinuses **108**: 357
pleomorphic adenoma of parotid gland, with cystic degeneration **108**: 446
pleomorphic lipoma, parotid gland **112**: 202

Pathology in Focus (continued)
polycystic disease, salivary gland **109**: 165
polypoidal carcinosarcoma, oropharyngeal **109**: 459
post-irradiation carcinosarcoma of parotid gland **108**: 443
proliferating cell nuclear antigen (PCNA), laryngeal carcinoma **112**: 310
prostatic adenocarcinoma, metastatic to palatine tonsil **108**: 178
pseudosarcoma of larynx, value of ploidy analysis **108**: 525
pulmonary carcinoma, metastatic to larynx **108**: 898
radiation injury to large arteries **111**: 988
renal cell carcinoma, metastasis to tongue **106**: 282
retropharyngeal liposarcoma **106**: 469
rhabdomyoma of larynx, rare cause of stridor **108**: 713
rhinosporidiosis **106**: 468
Rosai–Dorfman disease **111**: 1091
salivary gland masses, oncocytic differentiation **109**: 569
schwannoma
ear canal **109**: 1016
larynx **110**: 294
as parotid pleomorphic adenoma **111**: 1088
sebaceous gland neoplasms, oral squamous cell carcinoma **110**: 500
silver nitrate cautery, nasal mucosa **110**: 609
sino-nasal metastases, from follicular thyroid carcinoma **108**: 1010
solitary fibroma
neck **112**: 503
upper respiratory tract **107**: 252
spindle cell carcinoma
nasal septum **110**: 284
parotid gland **109**: 683
squamous cell carcinoma
maxillary antrum, metastatic to heart and skin **108**: 896
sebaceous differentiation **109**: 784
tonsil, metastases **105**: 50
synovial cell sarcoma of hypopharynx **106**: 285
temporal bone
chondroblastoma **108**: 1115
histopathology, open mastoidectomy cavities **107**: 569
temporomandibular joint, tumours and pseudotumorous lesions **111**: 776
teratocarcinosarcoma, nasal cavity and ethmoid **112**: 682
terminal duct adenocarcinoma, parotid gland **109**: 466
thyroglossal cyst
inflamed **109**: 899
papillary carcinoma **109**: 1124
thyroid neoplasms
adenolipoma **110**: 1088
metastasis from rectal carcinoma **110**: 192
tuberculosis, parotid gland **112**: 588
undifferentiated carcinoma, with lymphoid stroma, parotid **107**: 1177
verrucous carcinoma, maxillary antrum **105**: 696, **112**: 399
PCNA
laryngeal masses **109**: 630, **112**: 310
Peak nasal inspiratory flow
plateau effect **109**: 399
Pectoralis major muscle
surgical flaps **109**: 1176
transposition, laryngeal preservation in severe chondroradionecrosis **107**: 748
Peer review *see* Audit
Penetrating injuries
digital subtraction angiography **108**: 522
neck and vertebral artery **106**: 925
oropharynx **106**: 813
Penicillamine
changes in elastic tissue of upper respiratory tract **107**: 62
Penicillin V
penetration into tonsillar surface fluid, in healthy individuals and in patients with acute tonsillitis **107**: 309
Per-Lee tubes
evaluation **104**: 112
Percutaneous endoscopic gastrostomy
implantation metastases **107**: 946
Perichondritis of pinna
lymphoblastic lymphoma/leukaemia **112**: 592
Perilymph fistula 105: 270, **111**: 1166
bilateral **105**: 304
diagnostic tests **108**: 560
Periorbital abscess
ethmoiditis in neonate **107**: 1043
Peritoneal dialysis
gentamicin administration **105**: 999, **107**: 681
Peritonsillar *see* Tonsillar/peritonsillar
Petromastoid
cemento-ossifying fibroma **111**: 152
cholesteatoma, congenital **113**: 52
fractures **104**: 438
bilateral transverse, cochlear implant **104**: 997
see also Temporal bone
Petrous internal carotid artery
aneurysm **113**: 55
Phagocytosis
bronchoalveolar lavage **109**: 859
Pharyngeal
see also Nasopharyngeal; Oropharyngeal
Pharyngeal diverticula *see* Pharyngeal pouches
Pharyngeal masses
adenocarcinoma, intestinal features **104**: 900
carcinoma
and human papillomavirus **105**: 288
and hypoparathyroidism **112**: 1058
characteristics **109**: 120
goitre **113**: 170
haemangioma, positive cough impulse **113**: 172
haematoma, Epstein-Barr virus infection **110**: 1075
lipoma, cartilaginous metaplasia (chondrolipoma) **111**: 656
melanoma **108**: 275
synovial sarcoma **109**: 1207
wall, schwannomas **109**: 883
Pharyngeal myotomy
alaryngeal voice rehabilitation, complications **107**: 430
cervical osteomyelitis causing cord compression **108**: 511
laser **111**: 627
Pharyngeal perforation
secondary to 'pencil injury' **110**: 901
Pharyngeal pouches 106: 1002
carcinoma **104**: 821
endoscopic stapling **113**: 237
post-operative barium swallow radiography **113**: 233
following anterior cervical fusion **112**: 1085
inversion, complications **104**: 344
laser myotomy **111**: 627
lateral **105**: 793
recurrent, endoscopic stapling diverticulotomy **112**: 954
surgery, extra-pharyngeal neck pathology **107**: 1163
Pharyngeal trauma
in children **109**: 1168
non-accidental **109**: 1168
thermal damage, microwave cooking **108**: 509
Pharyngectomy 113: 145
node negative squamous cell carcinoma, postcricoid region **109**: 114
pharyngolaryngectomy, *see also* Oropharynx
pharyngolaryngoesophagectomy **110**: 1072
Pharyngitis
complication of intravenous hyperalimentation **108**: 159
Pharyngocele
encountered and misdiagnosed **109**: 247
Pharyngocutaneous fistula
post-laryngectomy, prophylactic antibiotics **104**: 225
Pharyngoesophageal fistula, following surgery 109: 1215
Pharyngoplasty
jejunal grafts **105**: 556
and obstructive sleep apnoea **105**: 195
squamous cell carcinoma **104**: 827
Pharyngostomy
feeding **105**: 451
Pharyngotonsillitis
necrobacillosis **108**: 1097
Phenotype
prognosis of laryngeal malignancies **112**: 710
Phlebectasia
bilateral internal jugular **106**: 753
left anterior jugular vein **113**: 858

Phleboliths
hypopharyngeal haemangioma **104**: 262
Phonation
laryngeal trauma **113**: 58
Phonosurgery
vs CO_2 laser surgery **113**: 140
Photochemotherapy
head and neck masses **109**: 1072
Photodynamic therapy
premalignant lesions, 'field cancerization' of oral cavity **107**: 1140
Photography
facial paralysis **109**: 748
measurement of nasal displacement **106**: 211
multidirectional endoscopy **112**: 464
teaching aids **109**: 741
Phrenic nerve
injury after neck dissection, respiratory failure **110**: 281
Pierre Robin syndrome
effect of age on hearing level **110**: 830
upper airway obstruction **111**: 1155
Pigmentation disorders
and hearing loss in Waardenburg syndrome with reference to WS Type II **109**: 96
Pilomatrixoma
external auditory meatus **107**: 333
Pindborg tumour
in Malaysians **110**: 757
Piperacillin
surgery, head and neck masses **106**: 409
Pituitary masses
adenoma, ectopic causing Nelson's syndrome **111**: 565
adenomectomy, antidiuretic hormone secretion **104**: 894
extension into nasopharynx **113**: 1109
surgery **111**: 511
trans-sphenoidal, rigid endoscopes **108**: 19
Plasma cell granuloma
maxillary sinuses **108**: 357
Plasmacytoma
epiglottis **112**: 174
extramedullary
laryngeal **107**: 1049
middle ear, differential diagnosis and management **108**: 868
nasal **105**: 41
salivary **105**: 687
hyoid **108**: 604
parotid gland **112**: 179
skull base, with unilateral sensorineural hearing loss **113**: 164
Plasmacytosis
upper aerodigestive tract **111**: 293
Plastic surgery
ear complications **112**: 531
Platform posturography
sensory interaction testing **107**: 496
Pleomorphic adenoma *see* Adenoma
Plexiform neurofibroma
cervical vagus nerve **106**: 643
Ploidies
tongue and tonsil squamous cell carcinoma **110**: 237
Plummer–Vinson syndrome 113: 475
Pneumatic artificial larynx 108: 852
Pneumatization
cranial, frequent Valsalva's manoeuvre **113**: 480
uncinate process **107**: 361
Pneumocele
maxillary sinus *(pneumosinus dilatans)* **105**: 673
Pneumocephalus
and CSF rhinorrhoea, biopsy-associated in papilloma **112**: 657
otogenic **112**: 1179
***Pneumocystis carinii* infection**
presenting as aural mass **113**: 555
Pneumonitis
caused by low density barium sulphate aspiration **107**: 347
Pneumoparotitis 106: 178
bilateral, in adolescent **106**: 558
subcutaneous emphysema and pleomorphic adenoma **107**: 349
Pneumopericardium
blunt tracheal trauma **111**: 387
Pneumoperitoneum
tension, after adenotonsillectomy **109**: 440
Pneumothorax
bilateral, post emergency tracheotomy, review of literature **108**: 69
Politzer, Adam
influence on otology **110**: 823
Polyarteritis nodosa
bilateral sudden onset cochleo-vestibular failure **104**: 562
Polychondritis
relapsing
bilateral vocal fold palsy **105**: 961
biopsy **113**: 663
ubation *see* Tracheal intubation *see* Relapsing polychondritis
Polycystic disease
salivary gland **109**: 165
Polymerase chain reaction
diagnosis of parotid gland tuberculosis **112**: 494
Polyostosis
bone disorders **105**: 80
Polypectomy
instruments **107**: 35
Polypoid lipoma
palatine tonsil **107**: 556
Polypoidal carcinosarcoma
oropharyngeal **109**: 459
Polysomnography
tracheostomy decannulation, child **113**: 442
uvulopalatopharyngoplasty **109**: 212
Polytetrafluoroethylene
vocal folds, endoscopic teflon injection **109**: 1184
Pope wick
myringoplasty ear canal dressing **106**: 327
Population studies
acoustic neurinoma **113**: 818
cerebello-pontine angle lesions, ENT clinic **113**: 518
Porta hepatis
nasopharyngeal carcinoma metastases, as obstructive jaundice **104**: 41
Positive airway pressure therapy
sleep apnoea syndrome **113**: 888
epiglottis changes **113**: 1022
see also Ventilation
Positron emission tomography
and computed tomography, in assessment of trismus associated with head and neck malignancy **112**: 303
fluorodeoxyglucose, head and neck masses **113**: 548
otolaryngology, head and neck surgery **112**: 125
Postauricular cerebellar encephalocele
secondary to chronic suppurative otitis media, and mastoid surgery **104**: 982
Postcricoid masses
carcinoma, in Fanconi's anaemia **105**: 125
lymphangioma **105**: 220
Posterior crus
stapedectomy **107**: 795
Posterior fossa
endoscopy **112**: 227
vestibular neurectomy **104**: 463, **105**: 1002
Postnasal space
angiofibroma **105**: 547
foreign bodies **111**: 775
Postoperative care and complications
tonsillectomy **113**: 1089
tracheostomy **113**: 999, **113**: 1116
Potassium-titanyl-phosphate laser *see* Laser surgery
Pott's puffy tumour
reviewed **104**: 574
Power Doppler imaging
giant parathyroid adenoma, hypercalcaemic crisis **112**: 796
Pregnancy
lower motor neurone facial paralysis **108**: 587
obstructive sleep apnoea **112**: 1189
recurrence of Bell's palsy **104**: 713
and sensation of ear problems **113**: 318
vomiting resulting in oesophageal perforation **107**: 1059
Prenatal testing
Treacher Collins syndrome **112**: 705

Primary intratemporal tumours
facial nerve, diagnosis and treatment **104**: 765
Prion biology
vCJD test, tonsillar biopsy **113**: 1064
Progesterone receptors
acoustic neuroma **104**: 865
Prognostic factors
carcinoma of larynx, DNA ploidy, S-fractions and tumour localization **113**: 538
p53 expression and histopathological parameters, carcinoma of tongue **113**: 446
and phenotype, laryngeal malignancies **112**: 710
Proliferating cell nuclear antigen (PCNA)
laryngeal carcinoma **112**: 310, **109**: 630
Promontory stimulation
following labyrinthectomy **105**: 729
Propylthiouracil
ANCA-associated mucocutaneous allergic vasculitis **113**: 477
Prostatic carcinoma metastases
nose and paranasal sinuses **107**: 629
palatine tonsil **108**: 178
sensorineural hearing loss **107**: 933
Prostheses
malleomyringoplasty **106**: 205
nasal septal button insertion **113**: 823
nasal septal perforation repair **113**: 721
nasal splints **113**: 358, **113**: 725
see also Speech rehabilitation; Tracheostomy tubes
Protein electrophoresis
diagnosis of cerebrospinal fluid rhinorrhoea **106**: 504
Proto-oncogene proteins
c-Fos, expression activated by tactile stimulation on laryngeal vestibulum, cat lower brainstem **109**: 39
Proton pump inhibitors
chronic posterior laryngitis **113**: 734
Provox valve
speech rehabilitation **108**: 666, **109**: 1068, **113**: 847
Pseudallescheria boydii
sphenoid sinusitis **107**: 344
Pseudoaneurysm
of carotid artery **109**: 889
carotid artery, delayed massive epistaxis **112**: 396
internal carotid artery, tonsillitis **105**: 588
subclavian artery **112**: 1095
Pseudocyst
auricle **104**: 31, **110**: 767
and auricular cartilage, histological examination **106**: 103
management **106**: 159
bilateral auricular **107**: 39
Pseudodiverticulosis
oesophageal intramural **104**: 911
Pseudolymphoma
parapharyngeal space **105**: 137
Pseudomonas aeruginosa
ear infections, typing related to outcome of treatment **104**: 678
II lectin reaction, cystic fibrosis **111**: 760
otitis externa, malignant, in HIV and AIDS **110**: 770
subglottic stenosis, AIDS **111**: 70
supraglottitis, neutropenia secondary to virus-associated haemophagocytic syndrome **106**: 739
Pseudotumour
haemophilia **113**: 924
inflammatory, trachea **108**: 613
laryngeal **109**: 142
maxillary antrum **104**: 244
sarcoma, value of ploidy analysis **108**: 525
Psychological assessment
multi-channel cochlea implant patients **107**: 298
Psychological morbidity
following laryngectomy **113**: 349
Pterygopalatine fossa
abscess
and chemotherapy **112**: 296
chemotherapy-associated **112**: 296
hydatid cyst **110**: 978
Pulmonary masses
carcinoid tumour, tonsillar metastasis **112**: 581
carcinoma, metastatic to larynx **108**: 898
endometriosis **105**: 235
oedema
foreign body aspiration **113**: 1119
laryngospasm **111**: 482
tuberculosis, presenting as suspected foreign body aspiration **106**: 453
Pulse oximetry
bronchial compression detected during foreign body removal **104**: 50
children with croup **105**: 295
Pyocele
middle turbinate **108**: 783
Pyoderma gangrenosum
and progressive sensorineural deafness **108**: 671
saddle nose deformity **112**: 870
Pyogenic granuloma
nasal **111**: 941
Pyopneumothorax
rare sequela of retropharyngeal abscess **107**: 460
Pyriform fossa/sinus
carcinoma, pectoralis major myocutaneous flap, laryngopharyngectomy **107**: 817
fistula **109**: 886
mucosa, for reconstruction after vertical partial laryngectomy **106**: 900
squamous cell carcinoma **109**: 157
tuberculosis **112**: 782

Quality audit
tonsillectomy **113**: 135
Quality issues
parental satisfaction, paediatric day-case ENT surgery **113**: 1072
Quality of life
head and neck cancer **106**: 238, **109**: 1029
Quelprud's nodule
post-auricular cartilaginous nodule **104**: 860
Quinsy
fifteen-month-old child **107**: 354
prospective study **106**: 986

Radiation injury
aerodigestive tract obstruction **109**: 68
antrochoanal fibrosarcoma **106**: 547
auditory brain stem evoked responses, after radiotherapy for nasopharyngeal carcinoma **106**: 887
and candidiasis **110**: 789
carcinosarcoma of parotid gland **108**: 443
chondroradionecrosis
diagnostic dilemma **109**: 218
larynx **109**: 218, **111**: 763
transposition of pectoralis major muscle **107**: 748
fistula, following laryngectomy **107**: 1136
head and neck cancer **109**: 346, **110**: 243
hypoglossal nerve palsies **105**: 44
large arteries **111**: 988
leiomyosarcoma
maxilla **105**: 1068
primary intranodal **109**: 80
liposarcoma of temporal bone **110**: 779
mandible, hemimandibulectomy **104**: 305
mucocele, sphenoid sinus **105**: 959
nasopharyngeal carcinoma **110**: 121, **110**: 496
temporal bone **113**: 222
necrosis of auditory canal, reconstructive surgery **112**: 1142
nerve palsies **105**: 44
olfactory neuroblastoma **110**: 1012
otitis externa **104**: 458
papilloedema, complication of mastoidectomy **110**: 878
post-irradiation hearing loss **113**: 815
primary spontaneous CSF rhinorrhoea **105**: 274
recurrent laryngeal carcinoma **104**: 704
temporal bone, cerebellopontine angle lesion **104**: 423
temporal bone necrosis **107**: 183
tumours of pharynx **104**: 129
xerostomia, artificial salivavs pilocarpine **108**: 663
Radiological staging
chest and abdomen, squamous cell carcinoma of head and neck **113**: 152

laryngeal masses **105**: 456
temporal bone, squamous cell carcinoma **105**: 38, **105**: 346
Radiology
aspirated foreign bodies in children **104**: 778
barium swallow, endoscopic stapling, pharyngeal pouches **113**: 233
cerebrospinal rhinorrhoea **105**: 274
cochlear implants **105**: 85
diagnosis of inflammatory sinonasal disease **109**: 27
maxillary sinus **105**: 541
primary atrophic rhinitis **106**: 702
stridor, children **109**: 844
Radiology in Focus
adenoid cystic carcinoma **104**: 662
aneurysm, false, maxillary sinus **106**: 1103
aneurysm of petrous internal carotid artery **112**: 196
Aspergillus necrotizing external otitis, in AIDS **112**: 98
B-cell non-Hodgkin's lymphoma, paranasal sinuses **108**: 263
ballooned trachea as a consequence of intubation **106**: 561
blow-out fracture of orbit floor **107**: 161
bronchogenic cyst **112**: 893
callus, laryngeal, presenting as neck lump **108**: 35
cholesterol cyst and cholesterol granuloma, petrous bone **106**: 465
cochlear implant, in bilateral transverse fracture of the petrous bone **104**: 997
CT scanning
3-D helical **110**: 604
endoscopic sinus surgery **112**: 986
laryngoceles **108**: 266
orbital abscess **105**: 1086
cystic hygroma, parotid gland **107**: 855
cystic neck lesions **107**: 245
diffuse erosion of skull base, cerebrospinal fluid rhinorrhoea **112**: 679
digital subtraction angiography, penetrating neck injury **108**: 522
encephalocele, complication of intranasal sinus surgery, MRI **112**: 790
epidermoid tumour, cerebellopontine angle, diagnosis by MRI **108**: 438
epistaxis
delayed massive, traumatic intracavernous carotid artery pseudoaneurysm **112**: 396
following sphenoid sinus exploration **108**: 171
intractable **111**: 1192
ethmoidal surgery, difference in height of right and left ethmoidal roofs **108**: 261
facial nerve palsies, after glomus tumour embolization **107**: 963
false-positive MRI, otoneurological pathology **107**: 465
foreign body in post-nasal space **111**: 775
frontal sinus surgery and MRI **109**: 1115
giant cell reparative granuloma, cricoid cartilage **109**: 1120
glomus tumours, MRI **107**: 1067
glomus tympanicum chemodectoma **108**: 607
haemangioma, parotid, MRI **108**: 892
haemangiosarcoma, maxillary antrum **104**: 831
Hashimoto's thyroiditis **109**: 781
intra-operative ultrasound-guided drainage of parotid abscess **112**: 1098
jugular fossa, enlarged, sensorineural hearing loss **109**: 350
Kimura's disease **111**: 389
laryngeal imaging, CT, MRI, following radiotherapy **107**: 565
lateral sinus thrombosis **105**: 693
lingual thyroid **105**: 493
lipoma, hypopharynx, diagnosis and resection **108**: 174
mastoiditis, simulating facial nerve schwannoma, MRI **108**: 1008
maxillary antrum, acquired involution **108**: 74
MRI in intracochlear acoustic schwannoma **108**: 1111
mycotic aneurysm, external carotid artery **112**: 793
oesophagus
foreign bodies **105**: 591
intramural pseudodiverticulosis **104**: 911
oropharyngeal foreign bodies, assessment **109**: 452
parapharyngeal abscess, external auditory meatus foreign body **111**: 1086
parapharyngeal emphysema, temporal bone trauma **112**: 301
peritonsillar abscess **109**: 449
pharyngeal diverticulum, lateral **105**: 793
pharyngeal perforation, secondary to 'pencil injury' **110**: 901
pneumatization, uncinate process **107**: 361
pneumoparotitis **106**: 178
bilateral, in adolescent **106**: 558
polypoidal carcinosarcoma, oropharyngeal **109**: 459
power Doppler, parathyroid adenoma causing hypercalcaemic crisis **112**: 796
Ramsay Hunt syndrome
mimicking acoustic neuroma on MRA **109**: 1013
MRI **109**: 777
retropharyngeal cold abscess, with respiratory distress **104**: 157
rhinoscleroma, palatal sign **105**: 968
sigmoid sinus, course **110**: 984
Sjögren's syndrome, severe form **108**: 806
spheno-choanal polyp **107**: 159
sphenoid sinusitis, presenting as parotid swelling **111**: 982
synovial sarcoma, middle ear **107**: 1071
temporal bone fractures **104**: 438
transethmoid transorbital foreign body **108**: 441
transorbital penetrating injury of paranasal sinuses **112**: 1202
trigeminal neuralgia, nasopharyngeal carcinoma **110**: 394
trismus, associated with head and neck malignancy, CT and PET **112**: 303
tuberculosis, facial paralysis, and CT **109**: 1013
tuberculous otitis media, temporal bone scanning **108**: 702
ultrasound, laryngeal cancers **107**: 65
ultrasound in peritonsillar abscess **108**: 610
vagus and accessory nerves, nasopharyngeal neoplasms **110**: 987
venous haemangioma, neck and mediastinum **105**: 386
vestibular schwannomas, MRI **111**: 877
Radionuclide imaging
head and neck neoplasms **109**: 674
obstructive sleep apnoea, complication of uvulopalatopharyngoplasty **109**: 212
otosclerosis **109**: 1051
Radiosurgery
schwannoma **110**: 366
Radiotherapy
aesthesioneuroblastoma **112**: 446, **112**: 628
all laryngeal cancer **107**: 434
and complications of laryngectomy **107**: 130
effect on oropharyngeal flora in patients with head and neck cancer **107**: 222
fractionation regimes and salvage surgery, carcinoma of laryngopharynx, British Institute of Radiology study **106**: 147
glottic carcinoma *in situ* **107**: 1014
head and neck cancer **105**: 959
head and neck masses **109**: 345, **109**: 744, **111**: 1006
'juvenile' angiofibroma **104**: 725
laryngeal cancer **104**: 699
laryngeal preservation **113**: 433
laryngeal squamous cell carcinoma, anaemia **113**: 829
low-dose, for refractory laryngeal granuloma **112**: 491
magnetic resonance and CT scanning, laryngeal imaging **107**: 565
maxillary antrum masses **106**: 1063
nasopharyngeal carcinoma **106**: 1055
auditory brain stem evoked responses **106**: 887
paranasal sinuses, nasopharyngeal carcinoma **110**: 19
primary mucosal malignant melanoma of the larynx **113**: 932
recurrent nasopharyngeal and naso-ethmoidal tumours **107**: 115
salvage surgery, carcinoma of laryngopharynx **106**: 147
and surgery, T_3 N_0 M_0 glottic tumours **107**: 912
surgical complications, carcinoma of tongue **106**: 712
treatment of node negative squamous cell carcinoma, post-cricoid region **109**: 114
uni- and multivariate analysis of indications, and loco-regional cure, advanced head and neck cancer **107**: 437
verrucous carcinoma of head and neck **112**: 132
vocal folds, fibrosarcoma **108**: 993
see also Radiation injury
Ramsay Hunt syndrome
audiology **104**: 104
herpesvirus **113**: 670
magnetic resonance imaging **109**: 777
mimicking acoustic neuroma on MRA **109**: 1013
Ranula
following bilateral submandibular duct transposition **105**: 667
plunging, mouth floor **110**: 554

Rats
subcutaneous tissue reaction to synthetic auditory ossicle (Apaceram) **109**: 14
Reading, Philip Vernon
obituary **112**: 1122
Receiver–stimulator
CI-24M cochlear implant, infants **113**: 212
Reconstructive surgery
auditory canal **112**: 1142
closure of nasal septum perforation **112**: 1167
for cochlear implants **113**: 881
with free forearm flap **111**: 48
free jejunal patch flaps **105**: 556, **113**: 680
for laryngectomy **106**: 900
New York **113**: 591
pedicled buccal fat pad (BFP) and palatal rotating flaps, closure of oroantral communication and palatal defects **113**: 834
pharynx, squamous cell carcinoma **104**: 827
resection of hypopharyngeal carcinoma **113**: 145
viscoaugmentation, for leakage around Provox 2 voice rehabilitation system **113**: 847
see also Flaps; Grafts; Laryngoplasty; Pharyngoplasty; *other named procedures*
Rectal carcinoma
metastatic to thyroid gland **110**: 192
Recurrent laryngeal nerve *see* Laryngeal nerve
Reference standards
randomized controlled trials in otolaryngology **112**: 460
Reinke's oedema
and smoking cessation **104**: 626
and thyroid function **105**: 291
Relapsing polychondritis 106: 911
bilateral vocal fold palsy **105**: 961
biopsy **113**: 663
ephedrine **106**: 63
tracheal stenosis and inner ear involvement **106**: 841
Renal adenocarcinoma
expectorated tissue diagnosis **108**: 1108
Renal cell carcinoma metastases
as aural polyp **111**: 1066
presenting as ear bleeding **110**: 370
to paranasal sinuses **109**: 986
to parotid gland **104**: 352
to pharynx **110**: 172
to tongue **106**: 282
to tonsil **111**: 37
Renal derived epistaxis 107: 144
Renal disease
branchio–oto–renal syndrome, cholesteatoma **113**: 841
Renal failure
parathyroidectomy **105**: 562
Renal tubular acidosis
hearing loss in Saudi children **109**: 930
Residual hearing despite radiological findings of anacusis 113: 714
Resonance frequency analysis
craniofacial implants **112**: 537
Respiratory failure
injury after neck dissection, phrenic nerve **110**: 281
Respiratory sounds
COPD, tracheomalacia **112**: 788
HIV infections **109**: 1197
laryngeal pseudotumour **109**: 142
radiological investigations **109**: 844
Respiratory tract
acromegaly **104**: 52
infections
bronchoalveolar lavage fluid **109**: 859
scanning electron microscopy findings **109**: 509
massive haemorrhage, complication of amyloidosis of larynx **107**: 51
nasal sarcoidosis **113**: 893
neoplasms
laryngeal papillomatosis, development of papillomata in paranasal sinuses **109**: 238
papillomatosis and squamous cell carcinoma prophylaxis **109**: 873
obstruction *see* Airway obstruction
papillomatosis *see* Papillomatosis
papillomavirus (HPV) **111**: 215
penicillamine-induced changes in elastic tissue **107**: 62
scleroma **105**: 198
bronchoscopy **108**: 484
solitary fibrous tumour **107**: 252
tuberculosis, misdiagnosed as Wegener's granulomatosis **104**: 255
viruses, serum antibodies, in acute otitis media **105**: 337
Rest cells
chronic otitis media without cholesteatoma, radical revision mastoidectomy **113**: 710
Restrictive respiratory insufficiency
tracheostomy **104**: 883
Retinoblastoma
bilateral, multiple malignancies **112**: 189
Retinoids
and interferon-α, head and neck neoplasms **110**: 857
Retraction pockets *see* Tympanic membrane
Retropharyngeal mass
abscess **110**: 483, **111**: 169, **111**: 546
acute torticollis **111**: 1183
anorexia **110**: 483
cold, with respiratory distress **104**: 157
nasopharyngeal carcinoma **113**: 70
pyopneumothorax sequela **107**: 460
angiomyoma **112**: 290
Ewing's sarcoma **108**: 363
goitre **113**: 170
haematoma
acute airway obstruction, metastatic carcinoma **113**: 258
diagnosis **107**: 356
review of literature **107**: 649
liposarcoma **106**: 469
mesenchymoma **107**: 1165
myxoma **108**: 690
Rhabdomyoma
hearing loss **109**: 1186
laryngeal **109**: 147
a rare cause of stridor **108**: 713
Rhabdomyosarcoma
head and neck, clinicopathological and DNA ploidy study **107**: 716
and malignant lymphoma, causing acute bilateral blindness in childhood **108**: 873
Rheumatoid arthritis
inner ear involvement **109**: 713
Rheumatoid nodules
larynx **112**: 573
Rhinitis
allergic
latex-induced **109**: 1094
levocabastine **111**: 935
mast cells **110**: 929
inferior turbinate **105**: 736
ultrastructure **105**: 1006
and vasomotor, silver nitrate **106**: 699
antibiotics, effect on ciliary beat frequency **109**: 24
atrophic
endoscopy **105**: 1014
nasal vestibule closure, new non-surgical technique **112**: 543
radiology and endoscopy of maxillary sinus **106**: 702
saddle nose deformity **104**: 404
bronchoalveolar lavage **109**: 859
chronic, bilateral transnasal vidian neurectomy **108**: 569
clinic information leaflets **105**: 282
cryotherapy **109**: 729
intranasal steroids **110**: 132
intrinsic, botulinum toxin type A **112**: 248
and lead toxicity, complications of indoor pistol shooting **110**: 663
mast cells
inferior turbinate **105**: 736
ultrastructure **105**: 1006
neonatal upper airway obstruction caused by chlamydial rhinitis **109**: 58
non-atopic, beclomethasone dipropionate **105**: 12
occupational, possible mechanisms of pathogenesis **109**: 104

vasomotor
hypertrophic inferior turbinates **110**: 732
silver nitrate **105**: 285
Rhinocerebral mycoses
aspergillosis **106**: 981
mucormycosis **106**: 48
ketoacidotic diabetic patient **107**: 233
liposomal amphotericin **105**: 575
Rhinoentomophthoromycosis 110: 1154
Rhinohygrometry
vs acoustic rhinometry **109**: 503
Rhinomanometry
evaluation of pre and post-operative SMR effects on exercise **104**: 126
Rhinometry *see* Acoustic rhinometry
Rhinophyma
carbon dioxide laser surgery **110**: 841
Rhinoplasty
calvarial bone grafts **105**: 1018
carotico-cavernous fistula **113**: 844
chondroplastic graft **104**: 539
displacement of dorsal nasal splint **113**: 358, **113**: 725
nasal sarcoidosis **106**: 544
nasal septal perforation repair **113**: 728
paraffinoma **110**: 785
two-point fixation **113**: 405
using silicone implants, complications **112**: 1074
Rhinorrhoea *see* Cerebrospinal fluid rhinorrhoea
Rhinoscleroma
antroscopy **106**: 697
electron microscopy **104**: 772
palatal sign **105**: 968
Rhinoscopy
lepromatous leprosy **111**: 122
Rhinosinusitis
allergic, prevalence **112**: 1019
children **113**: 1
chronic
bacteriology of secretions **112**: 1162
Charing Cross CT protocol for surgery **109**: 1057
long-term antibiotic therapy, ciliary beat frequency **109**: 24
functional endoscopic sinus surgery **105**: 832
Rhinosporidiosis 106: 468
associated with squamous cell carcinoma of tongue **104**: 648
culture methods **113**: 523
dapsone therapy **107**: 809
epidemiology in Europe **106**: 440
immunohistochemical and electron microscopic studies **108**: 1048
Ribavirin
for juvenile respiratory papillomatosis **107**: 423
Rifampicin
rhinoscleroma, electron microscopy **104**: 772
Robin sequence
treatment with nasal CPAP **109**: 328
Rosai–Dorfman disease
nasal manifestations **113**: 275
of paranasal sinuses **108**: 152
parotid tumours **111**: 1091
persistent ear nodule **106**: 249
sinus histiocytosis **106**: 61
Round window
congenital absence **104**: 980

Saddle nose deformity
in atrophic rhinitis **104**: 404
pyoderma gangrenosum **112**: 870
Saethre–Chotzen syndrome
conductive hearing loss **110**: 952
Safety
submucosal diathermy **104**: 408
St Cadoc
healing of deafness **104**: 1
Salicylazosulphapyridine
earache **110**: 466
Saliva
artificial, vs pilocarpine, xerostomia in radiation injury **108**: 663
aspiration, cricoidectomy with fibrin glue support **110**: 72
Salivary gland(s)
allergic aetiology of disease, proposed **109**: 66
atypically located submandibular gland diagnosed by Doppler ultrasound **110**: 1171
bilateral chronic sialadenitis **113**: 686
CMV in AIDS **109**: 1113
ectopic, in posterior triangle of neck **109**: 669
familial insensitivity to aldosterone, and hearing loss **104**: 956
mycobacterial infection **107**: 561
polycystic disease **109**: 165
sialectasis, tympanic neurectomy **109**: 1155
sialolithiasis **113**: 266
Sjögren's syndrome **112**: 1196
tuberculosis **112**: 588
diagnosis by PCR **112**: 494
ultrasound-guided biopsy **113**: 988
see also Parotid
Salivary gland masses 109: 683, **109**: 787, **111**: 316
abscess, intra-operative ultrasound-guided drainage **112**: 1098
acinic cell carcinoma
DNA flow cytometry **104**: 410
minor **105**: 782
adenoid cystic carcinoma **110**: 503, **111**: 491
and Hodgkin's disease **105**: 224
adenolymphoma, carcinomatous transformation **104**: 656
adenoma **111**: 985
adenomatoid hyperplasia **110**: 167
auricular nerve **111**: 556
basal cell adenocarcinoma **104**: 150
review of literature **107**: 862
basal cell adenoma **111**: 182
bilateral
from primary bronchial carcinoid tumour **105**: 489
maxillary sinus, hard palate and optic nerve **105**: 584
biopsy **110**: 96
calculi **109**: 767, **112**: 784
capillary haemangioma **111**: 588
carcinoid tumour, bilateral parotid, metastases **105**: 489
carcinoma
histological features and prognosis **112**: 944
undifferentiated, with lymphoid stroma **107**: 1177
cavernous lymphangioma **111**: 590
cell nuclear antigen **111**: 551
choristoma, middle ear **106**: 630
cyst
facial paralysis **110**: 799
iatrogenic epidermoid, following ear surgery **105**: 227
cystadenoma **111**: 883
cystic hygroma **107**: 855
cystic lymphangioma **106**: 566
desmoid-type fibromatosis **111**: 669
dysphagia **113**: 569
ear canal stenosis **110**: 493
enucleation **104**: 706
facial nerve schwannoma in a child **110**: 1169
fine needle aspiration cytology **107**: 1025, **109**: 853
giant calculus **106**: 446
haemangiomas, MRI **108**: 892
haemangiopericytoma **106**: 659, **107**: 1159
haematoma **110**: 590
hamartoma-like mass **111**: 296
herpesviruses **113**: 906
heterotopia **113**: 299
hibernoma **107**: 257
hypertrophy, bulimia **108**: 516
infantile desmoid-type **111**: 669
Ki-67, immunohistochemistry **106**: 35
leiomyosarcoma **110**: 401
lipoma **109**: 772, **110**: 93
lipomatosis **112**: 895
lymph node metastases **110**: 148
lymphangioma **110**: 586
malignant adenolymphoma, carcinomatous transformation **104**: 656
malignant mixed tumour of minor gland **108**: 76
megalith fistula **109**: 767
metastases **109**: 1222
cutaneous melanoma, head and neck **104**: 350

Salivary gland masses (continued)
renal carcinoma **104**: 352
seeding **109**: 671
monomorphic adenoma, clinicopathology **104**: 790
myoepithelioma **109**: 995
neurofibroma **113**: 938
non-tuberculous mycobacterial infections in children, management **109**: 525
oncocytic differentiation **109**: 569
oncocytoma, immunohistochemistry and ultrastructure **107**: 69
palate, flow cytometric and clinicopathological analysis **107**: 858
parotidectomy, modified facelift incision **108**: 574
peripheral nerve sheath tumour **106**: 748
plasmacytoma **105**: 687, **112**: 179
pleomorphic adenoma
with cystic degeneration **108**: 446
liver metastases **104**: 152
metastases **104**: 45
multiple metastases **106**: 652
nasal septum **113**: 483
pleomorphic lipoma **112**: 202
Rosai–Dorfman disease **111**: 1091
schwannoma **111**: 1088
sialadenoma papilliferum, oral **109**: 787
sialometaphasia, necrotizing **106**: 569
small lymphocytic lymphoma **105**: 584
solitary plexiform neurofibroma **110**: 1173
sphenoid **111**: 982
spindle cell carcinoma **109**: 683
submandibular
calculus, pulsed dye laser **110**: 942
excision **112**: 269
malignant oncocytoma **112**: 106
swelling due to spontaneous haemorrhage **112**: 497
T cell-rich histiocyte-rich B-cell lymphoma **110**: 811
teratoma **109**: 992
terminal duct adenocarcinoma **109**: 466
toxoplasmosis lymphadenitis, parotid gland **105**: 860
true malignant mixed tumour **104**: 360
tuberculosis simulating malignancy **113**: 951
tuberculous parotitis, clinically indistinguishable from a neoplasm **106**: 929
tumours of different type in one patient **108**: 798
Turban tumour **113**: 779
Wegener's granulomatosis **104**: 259, **110**: 691
Salivary terminal duct carcinoma 106: 649
***Salmonella* spp.**
neck abscess **111**: 489
with jugular vein thrombosis **105**: 966, **113**: 1122
Sarcoidosis
ethmoidal **108**: 682
nasal **113**: 893
VIII cranial nerve **109**: 1089
Sarcoma
Ewing's, retropharynx **108**: 363
nasal cavity and paranasal sinuses, chondrosarcoma, osteosarcoma and fibrosarcoma **108**: 947
sinonasal tract **105**: 186
soft tissue, surgical trauma **109**: 126
synovial
hypopharynx **106**: 285
middle ear **107**: 1071
pharynx **109**: 1207
Saudi children
hearing impairment, epidemiological study **108**: 294
hearing loss, and renal tubular acidosis **109**: 930
Scalp flap
reconstructive head and neck surgery **107**: 324
Scanning electron microscopy
chondromyxoid fibroma **113**: 380
chronic sinusitis and recurrent respiratory infections **109**: 509
Eustachian tube **107**: 651
head and neck masses **106**: 403
nasopharyngeal carcinoma **105**: 349
paraganglioma **110**: 196
pathological features of facial nerve **104**: 294
rhinoscleroma **104**: 772
rhinosporidiosis **108**: 1048
tympanic membrane perforations, in tissue culture **107**: 1106
Scheibe cochlear deformity
with macrocephaly, single channel implantation **112**: 1065
Schuknecht, Harold Frederick
obituary **111**: 1
Schwannoma 109: 1016
accessory nerve **113**: 942
bilateral **105**: 769
ear canal **107**: 829
facial nerve **110**: 632
child **110**: 1169
mastoiditis **108**: 1008
gene for type 2 neurofibromatosis **109**: 830
Horner's syndrome **111**: 493
intracochlear acoustic, MRI **108**: 1111
intralabyrinthine **105**: 659
larynx **110**: 294
asphyxiation **111**: 1171
review of literature **108**: 788
molecular genetics **109**: 381
MRI **111**: 877
predicting late facial motor function **109**: 394
nasal **106**: 1011
naso-ethmoid, intracranial extension **105**: 578
neurilemmoma of tonsil **113**: 585
neurofibromatosis **113**: 1034
paranasal sinuses **107**: 146, **113**: 585
parapharyngeal **105**: 384, **112**: 883
von Recklinghausen's disease **107**: 848
parotid gland **106**: 748
pleomorphic adenoma **111**: 1088
posterior pharyngeal wall **109**: 883, **110**: 170
surgery 1978-1990 **105**: 165
surgery
cerebrospinal fluid rhinorrhoea **107**: 1122
hearing preservation **106**: 500
vestibular
in an only hearing ear **108**: 983, **110**: 366
audit **112**: 860
cost-effective screening protocol **110**: 1129
enlarged translabyrinthine approach **108**: 545
gene for type 2 neurofibromatosis **109**: 830
intracranial spread and lateral extension to ear canal **108**: 149
molecular genetics **109**: 381
obstruction by aberrant jugular bulb vein **112**: 772
surgery
air travel-induced meningitis **110**: 258
transcranial translabyrinthine approach **107**: 111
translabyrinthine approach, facial nerve function **112**: 441
test comparisons **113**: 118
unilateral
audiological findings in 93 patients **110**: 1120
clinical features of neurofibromatosis **110**: 634
Scintigraphy
evaluation of glomus tumours **104**: 33, **110**: 373
FDG-PET, head and neck cancer **113**: 548
tympanocochlear (TCS), otosclerosis **109**: 1051
Xe-133, Eustachian tube function **113**: 509
Scleroma
diagnosis by endoscopy **104**: 619
eustachian tube, salpingoscleroma **108**: 944
larynx **111**: 438
lower respiratory tract
bronchoscopy **108**: 484
review of literature **108**: 161
upper respiratory tract, CT scanning **105**: 198
Sclerosis *see* Otosclerosis; Tympanosclerosis
Scottish Otolaryngology Audit
laryngeal cancer **108**: 332
Sebaceous gland masses
carcinoma, external auditory canal **113**: 578
oral squamous cell carcinoma **110**: 500
postauricular region **105**: 954
sebaceous differentiation **109**: 784
Self-harm
laryngo-pharyngectomy **108**: 252
macroglossia **111**: 75

Sella turcica
endoscopic anatomy **109**: 951
lesions, endoscopy **109**: 956
Semicircular canals
intractable benign paroxysmal positional vertigo **108**: 93
non-ampullary plugging, for vertigo **105**: 901
Seminoma
sphenoid sinus, metastatic **105**: 1075
Sensorineural hearing loss *see* Hearing loss
Sensorineural localization
specificity of guinea pig inner ear antigenic epitopes **109**: 19
Sensory interaction testing
platform posturography **107**: 496
Sensory nerve supply
external and middle ear **109**: 1141
Septic shock
and death, due to occult sinusitis **104**: 990
Septum *see* Nasal septum
Serological activity index
CO–N reaction in Wegener's granulomatosis **107**: 607
Serotonin function
hyperacusis **109**: 915
Serum antibodies
respiratory tract viruses, in acute otitis media **105**: 337
Sex hormone metabolism
diet-modified, squamous cell carcinoma prophylaxis **109**: 873
Sexually transmitted diseases
Chlamydia trachomatis, and tonsillitis **107**: 27
see also Syphilis
Shy–Drager syndrome
snoring and sleep apnoea **110**: 681
SIADH
inappropriate secretion of ADH, consequence of neck dissection **111**: 449
Sialadenitis
atypically located submandibular gland diagnosed by Doppler ultrasound **110**: 1171
parotid duct carcinoma **113**: 686
Sialadenoma papilliferum
oral **109**: 787
Sialolithiasis
parotid **113**: 266
Sialometaphasia
necrotizing **106**: 569
Sialorrhoea
submandibular duct transposition **105**: 101
Sickle cell disease
deafness **105**: 653
sensorineural
epidemiology **107**: 790
sudden loss **107**: 831
nasal obstruction **105**: 851
Siderosis
CNS, hearing loss **111**: 60
cochlear implantation **110**: 1151
unruptured intracranial aneurysm **109**: 549
Sigmoid sinus
middle ear surgery **110**: 984
Silicone implants
late complications of nasal augmentation **112**: 1074
Silicone stent
prophylaxis of nasolacrimal duct obstruction **105**: 299
Silver nitrate cautery
nasal mucosa **110**: 609
vasomotor rhinitis **105**: 285
Simpson, John Ferguson
obituary **110**: 3
Simulation studies
animal tissue model, therapeutic and diagnostic bronchoscopy **113**: 149
Singapore
stapedectomy problem, audit **109**: 225
Singapore swing 111: 527
Sinolith
frontal **112**: 570
Sinonasal tract
metastases, from follicular thyroid carcinoma **108**: 1010
sarcoma **105**: 186
Sinus surgery
and CT **112**: 986
computerized axial **109**: 1057
paranasal sinuses **104**: 477
encephalocele
evaluation with MRI **112**: 790
Le Fort I osteotomy **112**: 779
endoscopic **112**: 547, **112**: 622, **112**: 986
sinusitis **105**: 832
(FESS), general anaesthesia **110**: 31
interpretation of dilated pupil during endoscopy **112**: 622
intracranial complications, role for cefotaxime **107**: 1005
Le Fort I osteotomy approach **112**: 779
major complications **108**: 212
microscopic and endoscopic technique **105**: 635
midfacial degloving **106**: 1059
prophylaxis of nasolacrimal duct obstruction using silicone stent **105**: 299
sphenoethmoidal junction, foreign bodies **106**: 998
uncinectomy **112**: 547
Sinuses
computerized tomography in primary hypogammaglobulinaemia **107**: 1008
endoscopic anatomy **113**: 122
enlargement in Sturge–Weber syndrome **113**: 177
histiocytosis, with massive lymphadenopathy (Rosai–Dorfman disease) **106**: 61
mucosal thickening, significance **104**: 694
polyps, premalignant change **104**: 210
surgery, medial orbital protrusion **113**: 754
see also Named sinuses
Sinusitis
acute isolated **105**: 1072
and acute orbit, children **104**: 213
allergic, prevalence **112**: 1019
antibiotics
choice **112**: 264
effect on ciliary beat frequency **109**: 24
associated visual loss **107**: 840
bacteriology **110**: 547, **112**: 845
bronchoalveolar lavage **109**: 859
chronic
antimicrobial management in children **109**: 1159
bacteriology of secretions **112**: 1162
scanning electron microscopy findings **109**: 509
and yellow nail syndrome **104**: 811
complicated suppurative, subdural empyema **110**: 673
and craniofacial necrotizing fasciitis **112**: 371
diagnosis of inflammatory sinonasal disease **109**: 27
endoscopy **105**: 832, **110**: 641, **110**: 926
frontal sinus carcinoma **105**: 121
fungal, skull base osteitis **112**: 92
intracranial complications **104**: 645, **109**: 945, **109**: 1061
maxillary sinus **110**: 926
non-Hodgkin's lymphoma of lacrimal sac **112**: 969
occult, septic shock and death **104**: 990
orbital complications **109**: 300, **111**: 719
recurrent frontal, Graves' disease **110**: 670
sphenoid, *Pseudallescheria boydii* **107**: 344
visual loss **107**: 840
see also Sinus surgery
Sjögren-like syndrome
CMV in AIDS **109**: 1113
Sjögren's syndrome
multicystic salivary gland disease **112**: 1196
severe form **108**: 806
Skin transplantation
cholesteatoma **110**: 629
Skull base
chondromyxoid fibroma **113**: 380
erosion, presenting as cerebrospinal fluid rhinorrhoea **112**: 679
extradural hypoglossal neurilemmoma **112**: 1052
modified transcochlear approach, through petrous bone **108**: 1036
osteitis, following fungal sinusitis **112**: 92
solitary plasmacytoma, with unilateral sensorineural hearing loss **113**: 164
surgery

Skull base (continued)
facial nerve monitoring **108**: 557, **111**: 715
jugular bulb **111**: 333
visual evoked potentials **111**: 513
Skull growth
cochlear implantation **113**: 212
Sleep apnoea syndrome
epiglottis **112**: 940
evaluating and reporting **113**: 336
maxillofacial abnormalities **105**: 94
and Melnick–Needles syndrome, emergency tracheostomy **107**: 647
nasopharyngeal viral papillomatosis **111**: 976
and pharyngoplasty **105**: 195
positive airway pressure therapy **113**: 888
epiglottis changes **113**: 1022
pregnancy **112**: 1189
and tonsillectomy **111**: 829
uvulopalatopharyngoplasty
evaluation post **109**: 308
prediction of success **104**: 428
suggested complication **109**: 212, **104**: 871
without tonsillectomy **113**: 542
Sleep nasoendoscopy
snoring **109**: 1163
Sluder's neuralgia 109: 193
Smell *see* Olfactory pathways
Smoking
cessation in chronic Reinke's oedema **104**: 626
marker, in head and neck cancer **105**: 1036
squamous cell carcinoma of larynx **110**: 742
Smooth muscle tumour *see* Leiomyosarcomas
Snoring
CO_2 laser palatoplasty **110**: 754
diagnosis and treatment **109**: 1163
and oral submucous fibrosis **111**: 346
palatal surgery **109**: 849
propofol infusion, assessment of upper airway **108**: 865
and sleep apnoea
palatoplasty **111**: 1151, **112**: 639
Shy–Drager syndrome **110**: 681
sleep nasoendoscopy **109**: 1163
surgery **110**: 1105
surgical treatment **110**: 1105
uvulopalatoplasty
laser surgery **110**: 232
suggested complication **109**: 212
see also Sleep apnoea syndrome
Soft palate
isolated bilateral paralysis **106**: 839
see also Palate
Soft tissue neoplasms
associated with surgical trauma **109**: 126
chondroma, parapharyngeal space **112**: 294
Solar recharging system
hearing aid cells **108**: 768
Solitary fibrous tumour
infratemporal fossa **110**: 594
nasal cavity **110**: 468
nasopharyngeal neoplasms **105**: 213
Solitary keratoacanthoma
nasal vestibule **105**: 306
Solitary plasmacytoma
epiglottis **112**: 174
skull base, with unilateral sensorineural hearing loss **113**: 164
Somatostatin
receptor imaging of olfactory neuroblastoma **110**: 1161
Somjee–Crabtree temporal bone support clamp 111: 54
SP-immunoreactivity
and CGRP, distribution in cat larynx **107**: 522
Speech
acoustic analysis, tracheo-oesophageal vs oesophageal speech **108**: 325
practical test procedure **106**: 105
see also Voice disorders
Speech audiometry
and pure tone audiometry, secretory otitis media **107**: 787
Speech recognition
hearing **105**: 249
Speech rehabilitation
cochlear implantation, following neurofibromatosis type-2 **113**: 161
Groningen valve prosthesis
failure **106**: 521
high resistance vs low resistance **108**: 321
pressure, flow and speech parameters **106**: 896
Sheffield **106**: 154
indwelling tracheo-oesophageal voice prostheses **110**: 343
phonation, post laryngeal trauma **113**: 58
pressure, flow and speech parameters, Groningen valve prosthesis **106**: 896
Provox valve
and candida vegetations **108**: 666
postlaryngectomy voice rehabilitation **109**: 1068
viscoaugmentation for leakage **113**: 847
voice restoration after laryngectomy **111**: 4
Spheno-choanal polyp
radiological diagnosis **107**: 159
Sphenoethmoidal junction
foreign bodies, endoscopic sinus surgery **106**: 998
Sphenoethmoidal lesions
polyps **112**: 660
visual dysfunction **104**: 217
Sphenoid bone
osteogenic sarcoma **109**: 1101
Sphenoid sinus
aspergillosis, transnasal endoscopic surgery **107**: 837
encephaloceles, Le Fort I osteotomy **112**: 779
endoscopic anatomy **109**: 951, **113**: 122
endoscopic finding **110**: 850
exploration, massive epistaxis **108**: 171
giant cell tumour **105**: 855
hepatocellular carcinoma metastases **108**: 503
infection, acute isolated **105**: 1072
mucocele **106**: 23
oculomotor nerve palsy **111**: 471
radiotherapy to head and neck **105**: 959
mucormycosis **110**: 471
schwannoma treated by endoscopic excision **113**: 466
seminoma, metastatic **105**: 1075
sinusitis
presenting as parotid swelling **111**: 982
Pseudallescheria boydii **107**: 344
Sphenopalatine artery
endoscopy **110**: 27
ligation in persistent epistaxis **111**: 1047
Spinal cord compression
complicating tracheo-oesophageal puncture **105**: 1082
Spinal osteophytes (Forestier's disease) 113: 65, **113**: 366
Spindle cell carcinoma
intralingual lipoma **113**: 587
larynx **112**: 711
nasal septum **110**: 284
parotid gland **109**: 683
Spiral ligament hyalinization
and hearing loss, cochlear otosclerosis **104**: 952
Splints *see* Nasal splints
Squamous bone
melanotic neuroectodermal tumour of infancy **107**: 843
Squamous cell carcinoma
amplification of Int-2 gene, head and neck neoplasms **109**: 72
basaloid variant **106**: 370, **112**: 710
Bazex syndrome **110**: 899
carbon dioxide laser therapy, larynx **109**: 111
chest and abdomen, radiological staging **113**: 152
chronic lymphocytic leukaemia **110**: 694
diet-modified sex hormone metabolism **109**: 873
DNA, nuclear content **111**: 43
DNA computerized image analysis **111**: 141
DNA ploidy **113**: 538
head and neck **104**: 631, **111**: 43, **111**: 531, **112**: 132, **112**: 139, **112**: 170
cellular proliferation markers **108**: 859
long-term follow-up **106**: 234
radiotherapy **110**: 243
image cytometry, tongue and tonsil **110**: 237
immunohistochemistry **110**: 440

Jordan **113**: 422
larynx **112**: 710
cervical lymph nodes **113**: 619
cyclin D1 protein expression **111**: 622
diagnosis and prognosis **112**: 711
laser and conventional surgery **110**: 1138
neck abscess or cellulitis **110**: 893
p53 oncoprotein and hPV **110**: 742
radiotherapy, anaemia **113**: 829
sebaceous differentiation **109**: 784
liver metastases from a carcinoma arising within a pleomorphic adenoma of parotid gland **104**: 152
and MALT-type lymphoma, larynx **108**: 995
maxillary antrum **112**: 399
metastatic to heart and skin **108**: 896
middle ear and mastoid **105**: 38
nasal septum **112**: 172
nasal vestibule **106**: 332
node negative, postcricoid region **109**: 114
non-irradiated, non-smoking patient **109**: 762
pharynx and larynx, neck abscess or cellulitis **110**: 893
post radiation primary intranodal leiomyosarcoma **109**: 80
posterior pharyngeal wall, characteristics compared with lateral wall **109**: 120
pyriform fossa, pedunculated polypoidal mass **109**: 157
in reconstructed pharynx **104**: 827
recurrence analysis **109**: 1063
sebaceous gland neoplasms **110**: 500
spindle cell variant **109**: 683, **110**: 284, **112**: 711, **113**: 587
temporal bone, staging **105**: 38, **105**: 346
thyroglossal duct cyst **109**: 1001
thyroid **107**: 1155, **110**: 1176
tongue
p53 expression and histopathological prognostic factors **113**: 446
rhinosporidiosis **104**: 648
tonsillar region
and angioimmunoblastic T-cell lymphoma **111**: 580
and base of tongue
image cytometry **110**: 237
morphology and immunohistochemistry pilot study **107**: 1129
verrucous variant **105**: 696 **112**: 172, **112**: 399, **112**: 711
Squamous metaplasia
nasal polyps **112**: 755
Stab wounds
carotid artery **112**: 387
Stapedectomy
approach to numbers problem **104**: 390
audit **109**: 317
complications, granuloma **110**: 185
delayed facial palsy **104**: 611
far-advanced otosclerosis **112**: 158
laser stapedotomy **113**: 413
posterior crus **107**: 795
Singapore problem **109**: 225
Stapedial artery
persistent **106**: 254
Stapedial reflex
in cephalic tetanus **108**: 736
Stapedial tendon
ossification, congenital conductive deafness **105**: 763
Stapes
ankylosis, middle ear arterial anomalies **108**: 237
fixation, and large vestibular aqueduct syndrome **108**: 989
footplate, congenital fistula, meningitis **107**: 931
surgery **111**: 233, **113**: 512
hearing measurement **113**: 417
revision, long-term results **106**: 971
suprastructure fixation **107**: 36, **113**: 798
training **104**: 203
***Staphylococcus aureus* (MRSA) 111**: 874
fistulae, tracheocarotid artery **113**: 689
peritonsillar abscess, infant **110**: 78
Stapling technique
hypopharyngeal diverticula **104**: 553
pharyngeal pouches **113**: 233, **113**: 237
Stenosis
high tracheostomy **110**: 1003
Stents
oesophageal stenosis, caustic injuries **110**: 1041
Stereotaxic techniques
image processing in otolaryngology **110**: 322
Sternocleidomastoid muscle
focal myositis **112**: 687
and myocutaneous flaps **104**: 315
Steroids
Bell's palsy, electrophysiological study **108**: 940
budesonide, intubation granuloma **113**: 427
control of post-tonsillectomy pain **107**: 605
ear cartilage infection **110**: 154
ear drop preparations, and antibiotics **104**: 862, **107**: 188
in Ménière's disease, intractable vertigo **113**: 217
sarcoidosis **109**: 1089
Stevens–Johnson syndrome
aminoglycosides, erythema multiforme **113**: 1002
Stomal recurrence
following laryngectomy, risk factors **107**: 527
Stomaplasty for tracheostomal stenosis
carbon dioxide laser **112**: 467
Streptococci
group A, and *Haemophilus influenzae*, recurrent tonsillitis **105**: 439
S. bovis abscess, undiagnosed colon cancer **111**: 666
S. sanguis, supraglottitis **104**: 430
Stria vascularis
endotoxin damage, hearing loss secondary to otitis media **108**: 310
Stridor
acute dilatation of oesophagus **106**: 751
bilateral vocal fold palsy **105**: 961, **113**: 678
congenital, laryngeal mask airway and rigid endoscope **108**: 1076
and cough **107**: 639
histiocytosis, deglutition disorders **107**: 1061
HIV infection **109**: 1197
metabolic, bilateral vocal fold abductor paralysis, secondary to hypokalaemia **106**: 56
myasthenia gravis **106**: 633, **113**: 1114
vocal fold paralysis **106**: 737
neonates **108**: 63
osteophytes of cervical spine (Forestier's disease) **113**: 65
paradoxical motion of vocal folds **105**: 312
radiology in children **109**: 844
rhabdomyoma of larynx **108**: 713
Stroboscopy
vocal fold paralysis **110**: 141
Sturge–Weber syndrome
paranasal sinus enlargement **113**: 177
Stylohyoid ligament
spontaneous fracture **113**: 854
Styloid apparatus
anomaly causing dysphagia **105**: 964
ossicular chain reconstruction, long-term analysis **108**: 111
Subclavian artery
pseudoaneurysm **112**: 1095
Subcutaneous emphysema
Munchausen syndrome **110**: 981
Subdural empyema
complicated suppurative sinusitis **110**: 673
otorhinolaryngological origin **104**: 118
Subglottic cyst
neonates **105**: 222
Subglottic stenosis
endoscopic balloon dilatation **109**: 876
formal reintubation, neonates **108**: 474
massive lymphadenopathy (Rosai–Dorfman disease), sinus histiocytosis **106**: 61
Montgomery T-tube, and carbon dioxide laser **106**: 829
Subglottic tracheopathia osteoplastica 107: 352
Sublingual gland
dermoid cyst, midline presentation **104**: 578
plunging ranula **110**: 554
solitary fibrous tumour **108**: 998
Submandibular duct transposition
for drooling **105**: 101
plunging ranula **105**: 667

Submandibular gland
adenocarcinoma, positive serum and tissue immunohistochemical staining for both CEA and CA-125 **108**: 719
clear cell carcinoma arising in adenoma **108**: 529
swelling, actinomycosis **107**: 1169
see also Salivary glands
Submental abscess
delayed complication of Blom–Singer valve insertion **108**: 1093
Submucosal diathermy
safety **104**: 408
Substance P
and capsaicin pretreatment in experimentally-induced secretory otitis media **113**: 114
and IgE decapeptide, nasal polyp fluid **110**: 225
Suction polypectomy forceps 107: 35
Suction toilet
audit **109**: 971
Sudden infant death syndrome
mucus glycoproteins in larynges **109**: 403
Sulphuric acid fumes
from lead acid batteries, carcinogenesis **108**: 881
Superoxide dismutase
and adenosine deaminase, cancerous laryngeal surgery **108**: 849
Supraglottic
see also Glottic
Supraglottic larynx
angiocentric T-cell lymphoma **113**: 263
laryngectomy **107**: 813
neurofibroma **108**: 156
supero-lateral thyrotomy **106**: 416
transection, results of repair and functional outcome **109**: 340
Supraglottitis
pseudomonal, neutropenia secondary to virus-associated haemophagocytic syndrome **106**: 739
Streptococcus sanguis **104**: 430
Suprahyoid neck
normal and pathological anatomy **113**: 501
Surgery
for aspiration **107**: 121
biological dressings, clinical trials **112**: 140
decannulation, tracheostomy **107**: 217
endoscopic fenestration of choanal atresia **109**: 31
eye protection **107**: 618
obliterative, otosclerosis **113**: 512
paediatric
haemoglobin **107**: 1146
inherited bleeding disorders **110**: 947
pressure exerted by head bandages **107**: 1110
submucosal lesions of supraglottic larynx, supero-lateral thyrotomy **106**: 416
tracheal neoplasms, excision via anterior castellated approach **109**: 774
see also Day-case surgery; Endoscopic; *Specific conditions and locations*
Surgical emphysema
aural exostosis surgery **108**: 490
following dental treatment **113**: 756
Surveys
endoscopic stapling technique, pharyngeal pouches **113**: 237
UK otolaryngologists, diathermy haemostasis at tonsillectomy **104**: 549
Susac's syndrome
sensorineural hearing loss **111**: 1072
Suspension microlaryngoscopic surgery
and indirect microlaryngostroboscopic surgery, vocal folds **108**: 1064
Sutures
GIA gun, treatment of hypopharyngeal diverticula **107**: 723
Sweating
gustatory, external auditory canal **113**: 1000
Swimming
grommets and ventilation tubes **107**: 190
and laryngectomy **109**: 481
Synostosis
congenital stapes suprastructure fixation **113**: 798
Synovial cell sarcoma
hypopharynx **106**: 285
Synovial osteochondromatosis
temporomandibular joint **107**: 742
Synovial sarcoma
middle ear **107**: 1071
Synovitis
pigmented villonodular, temporomandibular joint **107**: 853
Syphilis
Crown Prince Frederick of Prussia **109**: 479
labyrinthitis **109**: 719
larynx and pharynx, at endotracheal intubation **108**: 688
tonsillar **111**: 766, **113**: 1125
Syringoma
nasal **111**: 862
Systemic lupus erythematosus
hoarseness **110**: 478

T-cell leukaemia–lymphoma
Waldeyer's ring **107**: 960
T-cell lymphoma *see* Lymphoma
T-tubes *see* Ventilation tubes
Tamoxifen
adenoid cystic carcinoma **111**: 1186
Tattooing
electrocautery **113**: 244
Teaching aids
clinical photographs **109**: 741
laryngomicrosurgery **111**: 56
middle ear ventilation **112**: 642
for tonsillectomy **111**: 1064
Technetium-99m(v) DMSA
head and neck cancer **104**: 783
Teeth
extraction and re-implantation for difficult laryngoscopy **108**: 44
incisor, intrusion into contralateral frontal sinus following trauma **107**: 240
maxillary sinus **111**: 820
in neck **104**: 913
Teflon (polytetrafluoroethylene)
injection, vocal folds **105**: 128, **109**: 1184
left vocal fold palsy **112**: 878
Telangiectasia
argon laser for epistaxis **111**: 34
epithelial sheets, tissue culture **107**: 510
Young's procedure, epistaxis **108**: 754
Temporal arteritis
submandibular swelling **104**: 819
Temporal bone
abnormalities, in idiopathic bilateral sensorineural hearing loss **111**: 117
campomelic dysplasia, histopathological findings **106**: 361
complications to cochlear implant **110**: 881
CT scanning, tuberculous otitis media **108**: 702
dissection
autopsy **110**: 219
for display **108**: 3
supply **112**: 1138
using low cost miniature electric drill **107**: 721
exhibit preparation **108**: 9
fibrous dysplasia
cholesteatoma, parapharyngeal abscess **108**: 51
craniofacial **105**: 662
monostotic **113**: 772
fractures **104**: 438, **112**: 959
cochlear implantation **104**: 997, **113**: 454
petrous temporal bone **104**: 438
histopathology, open mastoidectomy cavities **107**: 569
hypothyroidism, acquired **105**: 886
image processing, stereotaxic techniques **110**: 322
internal carotid artery, anatomical study **113**: 717
labyrinth, ossification **105**: 621
malakoplakia **105**: 568
necrosis, radiation injury **107**: 183
normal vs pathological, submucosal glands, Eustachian tube **107**: 1099
pneumatisation, location of lateral sinus and length of mastoid process **106**: 485
polyostosis **105**: 80
sensorineural deafness and internal auditory meatus **113**: 1015

trauma
blast injuries **105**: 890
findings **104**: 986
gunshot injuries **112**: 929
parapharyngeal emphysema **112**: 301
see also Temporal bone
see also Middle ear
Temporal bone masses
acoustic schwannoma of traumatic origin, study **104**: 270
adenocarcinoma **108**: 710
carcinoma
glomus jugulare, tympanicum tumours **111**: 963
presenting as malignant otitis externa **106**: 908
cavernous haemangioma **106**: 1086
cholesteatoma, lymphoblastic acute leukaemia **112**: 867
cholesterol granuloma, and cholesterol cyst **106**: 465
chondroblastoma **108**: 1115
giant cell tumour **109**: 538
haemangiopericytoma **104**: 998, **113**: 911
liposarcoma, radiotherapy **110**: 779
metastatic thyroid neoplasm **109**: 1200
molecular biology of tumours **112**: 1011
osteoblastoma **109**: 565
papillary neoplasms, middle ear **105**: 950
primary mucosal malignant melanoma **105**: 1061
radiation for nasopharyngeal neoplasm **113**: 222
schwannoma **105**: 346
squamous cell carcinoma, staging **105**: 38, **105**: 346
xanthogranuloma **111**: 63
Temporal bone surgery
closure of petrous apex with ionomeric cement, translabyrinthine removal of acoustic neuroma **108**: 202
for cochlear implants **113**: 881
holder **109**: 644
irrigation **113**: 740
operating microscope **111**: 958
resection for pinnal malignancy **107**: 697
subtotal petrosectomy, external canal overclosure, otitis media **108**: 197
support clamp **111**: 54
Temporal fascia graft
closure of nasal septum perforation **112**: 1167
Temporal headache
Wegener's granulomatosis **110**: 802
Temporal lobe and post-aural abscesses 111: 284
Temporal region
non-Hodgkin's lymphoma **110**: 161
Temporalis fascia
anatomy **105**: 522
grafts **111**: 707
with temporoparietal **111**: 435
Temporocele
CT findings and management **113**: 661
Temporomandibular joint
capsule prolapse, repair using autograft cartilage **108**: 30
dislocation, and deafness from injury **108**: 415
extra-articular pigmented villonodular synovitis **112**: 182
osteochondromatosis **107**: 742
osteomyelitis, malignant otitis externa **113**: 451
pigmented villonodular synovitis **107**: 853, **108**: 166
tumours and pseudotumorous lesions **111**: 776
Temporoparietal fascia flap
mastoid surgery **105**: 417
Tension pneumocephalus
and hemiparesis, CSF rhinorrhoea **112**: 654
Tension pneumoperitoneum
after adenotonsillectomy **109**: 440
Teratocarcinosarcoma
nasal cavity and ethmoid **112**: 682
Teratoma
Eustachian tube **113**: 271
facial paralysis, newborn **110**: 875
head and neck masses **106**: 836
submandibular gland neoplasms **109**: 992
terminology **113**: 271
Terminal parotid duct carcinoma 105: 780
Testicular teratoma
nasal cavity, severe intractable epistaxis **112**: 1078
Tetanus
clinical and bacteriological profile of ear **106**: 1051
deglutition disorders **106**: 923
stapedial reflex **108**: 736
Thailand
cochlear implantation **113**: 515
Thalassaemia intermedia
otological manifestations **106**: 316
Thermal damage to pharynx and larynx
microwave cooking **108**: 509
Thoracic empyema
bilateral, complicating adult epiglottitis **105**: 858
Thoracic malignancy
neck abscess **112**: 891
Thoraco-cervical fibromatosis
surgical excision **111**: 385
Thorotrast
granuloma **104**: 355
Thromboembolism
prophylaxis in head and neck surgery **111**: 845
Thrombosis
following manipulation of fractured nasal bones **110**: 69
jugular veins
aneurysm as hard neck mass **110**: 179
salmonella neck abscess **113**: 1122
Trousseau's syndrome **110**: 1166
lateral sinus **104**: 949
massive, in laryngeal nerve palsy **107**: 54
Thymic cyst 107: 950
Thymomas
ectopic cervical hamartomatous, showing extensive myoid differentiation **107**: 155
Thymus gland
successful management of tracheo-innominate artery fistula using interposition of a thymus pedicle flap **109**: 161
Thyroglossal cyst
aberrant **108**: 1105
inflamed **109**: 899
ossification, embryological significance **108**: 168
papillary carcinoma **109**: 1124
with normal thyroid gland **107**: 1174
post-excisional lingual thyroid **108**: 341
squamous cell carcinoma **109**: 1001
Thyroid cartilage
anterior cervical pain syndromes, triamcinolone acetonide **109**: 49
and mastoid process syndromes **111**: 1190
see also Alar cartilages
Thyroid disorders
acquired hypothyroidism, temporal bone findings **105**: 886
acute bacterial thyroiditis **105**: 788
benign, and vocal fold paralysis **108**: 433
laryngeal nerve palsy **108**: 878
lingual thyroid, magnetic resonance imaging **105**: 493
Reinke's oedema **105**: 291
Thyroid gland
benign disease, and vocal fold paralysis **113**: 473
development from fourth branchial pouch **108**: 71
ectopic
dual **112**: 393
scanning **109**: 674
in trachea, papillary carcinoma, tall cell variant **113**: 183
vs invasive carcinoma **112**: 673
fine needle aspiration cytology, tuberculosis **109**: 36
oesophageal foreign bodies **113**: 769
tracheal **104**: 733
Thyroid gland masses
actinomycosis **111**: 172
adenocarcinoma **110**: 192, **110**: 1078
adenolipoma **110**: 1088
adenoma, recurrent laryngeal nerve palsy **105**: 141
benign goitre **109**: 892
carcinoma
Japan **110**: 657
metastases **108**: 886
metastases to lymph nodes **106**: 932
metastases to paranasal sinuses **111**: 647
metastases to temporal bone **109**: 1200
metastatic follicular to maxilla **112**: 69

Thyroid gland masses (continued)
occult giant cervical cyst **105**: 863
upper airway invasion **107**: 752
carcinoma-like carcinoids, larynx **105**: 683
ectopic, adherent to the oesophagus **106**: 746
follicular carcinoma, sino-nasal metastases **108**: 1010
foreign bodies **107**: 1057
laryngeal occlusion **110**: 1078
lateral aberrant, metastatic tumour **106**: 376
lingual, post thyroglossal cyst excision **108**: 341
occult papillary carcinoma **109**: 1109, **109**: 1204
oncocytoma **105**: 143
papillary carcinoma **108**: 899, **110**: 704
papillary thyroid carcinoma as branchioma **110**: 490
paraganglioma **113**: 978
squamous cell carcinoma **107**: 1155
laryngeal occlusion **110**: 1176
vocal fold paralysis **113**: 260
Thyroid surgery
drainage, prospective randomized study **113**: 49
lobectomy, removal of fish bone **104**: 511
microsurgical techniques **112**: 556
orbital decompression **111**: 946
Thyroiditis
autoimmune **109**: 781
Thyroplasty
incompetent larynx **112**: 1172
Isshiki type III, evaluation in mutational voice disorders **113**: 31
Thyrotomy
neurilemmoma of larynx **113**: 346
supero-lateral, supraglottic larynx **106**: 416
Tinnitus
assessment of distress associated **112**: 258
audit **109**: 826
division of eighth nerve **105**: 1099, **105**: 1101, **105**: 1102, **105**: 1106
ear canal resonance and hearing loss **111**: 810
effect of removal of translabyrinthine acoustic schwannoma **106**: 329
hypnotherapy and counselling **110**: 117
iatrogenic pulsatile **107**: 445
intratympanic instillation of lignocaine (lidocaine) via ventilation tubes **106**: 603
Lhermitte–Duclos disease **113**: 464
pregnancy **113**: 318
pulsatile, and arteriovenous fistula **104**: 421
relapsing polychondritis **110**: 154
related to eyelid blinking **106**: 44
relief, cochlear labyrinthectomy **110**: 57
severity measurement **105**: 89
unilateral, MRI screen for vestibular schwannoma **113**: 818
venous hum, ligation of internal jugular vein **107**: 1037
white noise generators, retraining therapy **111**: 810
Tissue culture
epithelial sheets, management of epistaxis associated with hereditary haemorrhagic telangiectasia **107**: 510
tympanic membrane perforations, scanning electron microscopy **107**: 1106
Tissue volume estimation
Holden's apparatus **109**: 1181
Titanium grommets
trial **104**: 197
see also Ventilation tubes
Toluidine blue
foreign bodies in pharynx **113**: 909
Tongue
macroglossia
angiomatous malformation of floor of mouth **109**: 665
Down's syndrome **104**: 494
fluctuating macroglossia **109**: 665
traumatic **111**: 75
use of leeches **109**: 442
paralysis, following head injury **109**: 770
tuberculosis **110**: 177
Tongue masses
adenocarcinoma **110**: 700
angiocentric T-cell lymphoma **113**: 263
carcinoma
surgical complications following radiotherapy **106**: 712
tongue, few surgical complications of radiotherapy **106**: 712
dermoid cysts **111**: 1179
Ebner's gland tumour, microcystic adnexal carcinoma **109**: 1211
foreign bodies, nasendoscopy guided removal from base of tongue and vallecula **109**: 534
giant enterocystoma, infant **104**: 814
glossal abscess **110**: 389
glycogen-rich clear cell carcinoma **108**: 716
hamartoma **107**: 363
leiomyosarcoma **108**: 617
leiomyotomous hamartoma **109**: 1190
lipoma **110**: 189
lymphangioma **105**: 924
metastases from bronchial carcinoma **108**: 1099
metastases from renal cell carcinoma **106**: 282
microcystic adnexal carcinoma **109**: 1211
osteochondroma **104**: 138
pleomorphic adenoma **111**: 1177
primary osteogenic sarcoma **113**: 376
spindle-cell variant of intralingual lipoma **113**: 587
squamous cell carcinoma **110**: 237
marijuana smoking **104**: 896
morphology and immunohistochemistry pilot study **107**: 1129
prognostic factors **113**: 446
and rhinosporidiosis **104**: 648
ultrasonography diagnosis and staging **110**: 43
Tonsil
torsion **110**: 891
Tonsillar abscess **105**: 442, **105**: 553, **105**: 743, **110**: 78, **110**: 175, **110**: 887
Arcanobacterium haemolyticum **106**: 1000
audit **109**: 531
bilateral, obstructing airway, in infectious mononucleosis **112**: 1186
cellulitis **113**: 229
computed tomographic findings **109**: 449
immunoglobulin- and complement-coated bacteria **112**: 634
Kawasaki disease **111**: 73
mediastinitis **110**: 175
microscopy and bacterial culturing **111**: 392
and necrotizing fasciitis **113**: 759
paediatrics **110**: 78
prospective study **106**: 986
quinsy in fifteen-month-old child **107**: 354
S. aureus, infant **110**: 78
synergistic necrotizing cellulitis **110**: 887
ultrasound **108**: 610
Tonsillar biopsy
vCJD test **113**: 1064
Tonsillar fossa
lipoma **108**: 507
Tonsillar haemorrhage
in acute tonsillitis **108**: 791
idiopathic spontaneous **107**: 44
Tonsillar infections
invasive candidiasis **111**: 1199
nematodes **110**: 387
prospective study of ultrasound, computerized tomography and clinical diagnosis **113**: 229
syphilis **111**: 766, **113**: 1125
tuberculosis **108**: 348, **109**: 880
US, CT and clinical diagnosis **113**: 229
see also Tonsillar abscess
Tonsillar lymphocytes
Cowden's disease **106**: 640
Tonsillar masses
bilateral synchronous carcinoma **113**: 255
Burkitt's lymphoma **104**: 991
choristoma **110**: 101
dermoid cyst **110**: 101
giant amyloidoma **110**: 613
haematoma **111**: 266
heterotopia, cartilage and bone **110**: 611
lipoma **109**: 662
lymphogranuloma venereum **104**: 331
melanoma **110**: 163, **113**: 1036
Merkel-cell carcinoma **106**: 1100

metastases
adenocarcinoma of stomach **110**: 291
from colon carcinoma **108**: 449
from renal cell carcinoma **111**: 379
malignant pulmonary carcinoid tumour **112**: 581
melanoma **109**: 236
myofibroblastic tumour **111**: 880
neurilemmoma **113**: 585
non-Hodgkin's lymphoma **105**: 445
polypoid lipoma **107**: 556
squamous cell carcinoma **110**: 237
and angioimmunoblastic T-cell lymphoma **111**: 580
morphology and immunohistochemistry pilot study **107**: 1129
see also Tonsillar abscess
Tonsillar polyps
benign hamartomatous polyp **107**: 1074
hairy polyp **110**: 101
hamartoma **105**: 1089
Tonsillar/peritonsillar space
lipoma **108**: 693
Tonsillectomy
and adenoidectomy, oropharyngeal microbial flora **108**: 763
adult
patient selection **105**: 836
post-operative pain and medication **112**: 41
audit
antibiotics in children **110**: 357
quality **113**: 135
Scottish audit *Supplement No. 20, August*
bipolar and monopolar microdissection needle excision **111**: 735
bismuth subgallate **108**: 761, **109**: 203
bleeding in severe von Willebrand's disease **109**: 437
children
admission and discharge policy **112**: 1047
bacteraemia **111**: 950
complications post-discharge **110**: 136
fluid replacement **104**: 801
GP vs consultant **108**: 131
long distance travel **104**: 417
parental preferences for duration of hospital stay **107**: 709
control of intra-operative blood loss **105**: 191
day-case surgery **106**: 299, **109**: 1166
laser **109**: 515
review of literature **107**: 703
safety **106**: 299
same-day **107**: 706
diathermy haemostasis, UK otolaryngologists, survey **104**: 549
electrocoagulation, pain control **110**: 446, **110**: 1038
electrodissection and dissection/snare, comparison **109**: 733
guillotine, and dissection **106**: 817
haematological tests, desirability **107**: 205
haemophilia **110**: 947
haemostasis, ligatures vs diathermy **107**: 711
haemostatic techniques **109**: 206
hayfork **105**: 33
infectious mononucleosis **106**: 989
middle meatus microbiology **113**: 24
pain **109**: 963
pain control, steroids **107**: 605
post-operative complications **113**: 1089
post-operative morbidity in electrodissection tonsillectomy **109**: 209
secondary haemorrhage, NSAIDs **113**: 28
and sleep apnoea syndrome **111**: 829
tension pneumoperitoneum **109**: 440
travelling kit **107**: 1086
Tonsillitis
bacteria of epithelium **105**: 29
and bilateral cervical abscesses, fatal cyclical neutropenia **105**: 487
cervical necrotizing fasciitis **108**: 435
foreign body **112**: 584
Lemierre syndrome **109**: 657
peritonsillar sepsis, bacteriology **105**: 553
pseudoaneurysm of internal carotid artery **105**: 588
recurrent, group A Streptococci and *Haemophilus influenzae* **105**: 439
sexually transmitted *Chlamydia trachomatis* **107**: 27
tonsillar surface fluid, penetration of penicillin **107**: 309
Topical inhalant steroids
intubation granuloma **113**: 427
Torticollis
Birmingham Mummy **109**: 273
retropharyngeal abscess **111**: 1183
Total laryngopharyngoesophagectomy
with gastric transposition **110**: 1072
Toxoplasmosis
bilateral sudden deafness **105**: 115
biopsy of lymph nodes **110**: 348
lymphadenitis of parotid gland **105**: 860
Toynbee Memorial Lecture
mastoid surgery, and Hong Kong Flap **108**: 825
middle ear mechanics, normal, diseased and reconstructed ears **112**: 715
Trachea
canine, mucosal wound and cicatricial stricture formation **105**: 207
ectopic thyroid tissue, papillary carcinoma **113**: 183
Tracheal intubation
acquired tracheo-oesophageal fistula **104**: 267
ballooned as consequence of intubation **106**: 561
ballooning **106**: 561
inter-arytenoid glottic bar **104**: 727
laryngoscopy **112**: 786
late congenital syphilis of larynx and pharynx **108**: 688
post-intubation sequelae **109**: 313
reintubation, subglottic stenosis in neonates **108**: 474
respiratory arrest secondary to oral epulis **106**: 444
retrograde **105**: 746
Tracheal masses
inflammatory pseudotumour **108**: 613
Tracheal stenosis
following percutaneous dilatational tracheostomy **113**: 1116
in infants **104**: 229
and inner ear involvement, relapsing polychondritis **106**: 841
laser surgery **110**: 973
Westaby T-Y tracheo–bronchial stent **113**: 652
Tracheal surgery
adenoid cystic carcinoma **109**: 774
cervical, transection following blunt trauma **109**: 250
neoplasms
analysis of clinical features and treatment results **108**: 230
excision via anterior castellated approach **109**: 774
reconstruction flaps **106**: 741
subglottic stenosis, endoscopic balloon dilatation **109**: 876
successful management of tracheo–innominate artery fistula using interposition of a thymus pedicle flap **109**: 161
Tracheal thyroid 104: 733
Tracheal trauma
pneumopericardium **111**: 387
Tracheal tuberculosis 107: 1052
Tracheal wall diverticula 111: 663
Tracheitis
tuberculosis **112**: 579
Tracheo–bronchial neoplasms
laryngeal papillomata **108**: 164
Tracheo–bronchial stent 113: 652
Tracheo–carotid artery
fistula infected with MRSA **113**: 689
Tracheocele
large cervical presentation **113**: 364
Tracheo–innominate artery fistula
interposition of a thymus pedicle flap **109**: 161
Tracheomalacia
COPD, respiratory sounds **112**: 788
Tracheo–oesophageal fistula
co-existing laryngeal cleft **113**: 469
creation, post laryngectomy **106**: 231
flexible endoscopy **109**: 1077
following intubation **104**: 267
foreign bodies **110**: 685
Tracheo–oesophageal puncture
Bivona voice prosthesis, aphonia **108**: 579
cervical cord compression **105**: 1082
forceps technique **105**: 748

Tracheo–oesophageal puncture (continued)
gastroscope and a percutaneous endoscopic gastrostomy set **111**: 447
retrograde passage of gastroscope, via mini-laparotomy and gastrotomy **113**: 564
review **105**: 750
under local anaesthesia **108**: 980
Tracheo–oesophageal speech
following transmucosal pharyngeal myotomy **111**: 659
Tracheopathia osteoplastica
subglottis **107**: 352
Tracheostomal stenosis
carbon dioxide laser **112**: 467
Tracheostome
Carden anaesthetic tube **108**: 46
Tracheostomy
amylase activity in tracheobronchial secretions **109**: 640
broken introducer, unusual foreign body **107**: 463
children in Papua New Guinea **113**: 645
closure in restrictive respiratory insufficiency **104**: 883
cuff herniation and inflation characteristics of tube **110**: 1142
decannulation, polysomnography, child **113**: 442
emergency, Melnick–Needles syndrome, and sleep apnoea **107**: 647
foreign body **110**: 1069
horizontal tracheal incision **104**: 322
intraoperative herniation of tube cuff **109**: 159
percutaneous, in head and neck unit **106**: 625
percutaneous dilatational, MRI **111**: 953
post-operative care **113**: 999
post-operative complications **113**: 1116
as repeated insertion of foreign bodies into tracheobronchial tree **107**: 359
self care, Nottingham System **106**: 723
stenosis and voice changes **110**: 1003
surgical decannulation **107**: 217
tracheal stenosis **113**: 1116
tracheo–innominate artery fistula, interposition of thymus pedicle flap **109**: 161
use of inhalers **113**: 762
washer, simple aid for tracheo–oesophageal speakers with a large tracheostome **107**: 824
Tracheostomy tubes
paediatric **105**: 1046, **113**: 35
silver
corrosion **113**: 68
corrosion and fracture **105**: 48
obturator in tracheobronchial tree **104**: 437
use of inhalers **113**: 762
Westaby T-Y tracheobronchial stent **113**: 652
Tracheotomy
bilateral pneumothorax, review of literature **108**: 69
electrodissection **110**: 765
percutaneous **110**: 723
Tragal cartilage
graft, nasal septal perforation **111**: 435
inferior turbinate mucoperiosteal sandwich graft technique, repair of nasal septal perforations **106**: 893
Training
diagnostic bronchoscopy **113**: 149
Transethmoid decompression
optic nerve, head injury **105**: 205
Transforming growth factor (TGF-alpha)
cholesteatoma **112**: 750
Transitional papilloma
middle ear **106**: 628
Translabyrinthine acoustic schwannoma
effect of removal on tinnitus **106**: 329
Transnasal endoscopy
local anaesthesia **111**: 616
Transpharyngeal approach
dysphagia, in Forestier's disease **113**: 366
Transverse sinus thrombosis
and venous infarction of brain, following unilateral radical neck dissection **112**: 88
Trauma *see* Blast injuries; Head injury; *specific locations*; Wounds
Trauma
treatment *see* Reconstructive surgery; Rehabilitation
Travel
long distance, by children for tonsillectomy **104**: 417
Treacher Collins syndrome
genetics and prenatal testing **112**: 705
Triamcinolone acetonide
steroid injection after hot dissection tonsillectomy **110**: 1038
treatment of anterior cervical pain syndromes **109**: 49
Trichinosis
cancer of the larynx **106**: 171
Trigeminal nerve
maxillary sinus barotrauma **105**: 217
neurinoma, with trismus **113**: 1112
Trigeminal neuralgia
nasopharyngeal carcinoma **110**: 394
Tripod allograft
reconstruction of incudal lesions **108**: 206
Trismus
associated with head and neck malignancy, CT and PET **112**: 303
head and neck masses **107**: 1017
migrating foreign body **109**: 990
with trigeminal neurinoma **113**: 1112
Trousseau's syndrome
recurrent laryngeal nerve paralysis **110**: 1166
thrombosis, jugular veins **110**: 1166
Tuberculoma 111: 872
mastoid **109**: 232
Tuberculosis
bacilli in cervical lymph node **105**: 558
cervical lymphadenopathy, fine needle aspiration cytology **104**: 24
cervical spine **105**: 786
endobronchial,differentiation from foreign body aspiration **109**: 1192
facial paralysis, and CT **109**: 1013
fine needle aspiration cytology of thyroid gland **109**: 36
laryngeal
clinical and videostroboscopic evaluation **112**: 45
lepromatous patient **107**: 845
lingual **112**: 86
lymphadenopathy, secondary to atypical mycobacterial infection **110**: 48
mandibular, in a child **112**: 585
mastoiditis **105**: 907
Mycobacterium spp. **109**: 5
nasal **109**: 324
nasopharyngeal **106**: 1079, **113**: 928
nasopharyngeal cyst, diagnostic aspiration using nasendoscope **108**: 505
oral **109**: 880
oropharyngeal wall **113**: 1029
otitis media
diagnosis **107**: 339
temporal bone scan **108**: 702
otolaryngeal **109**: 1080
parotid gland **112**: 588
PCR **112**: 494
parotitis **106**: 1094
clinically indistinguishable from a neoplasm **106**: 929
role of surgery **110**: 96, **110**: 976
pulmonary, presenting as suspected foreign body aspiration **106**: 453
pyriform fossa **112**: 782
salivary gland **113**: 951
secondary tonsillar and cerebral **108**: 348
tongue **110**: 177
tonsillar **109**: 880
tracheal **107**: 1052
tracheitis **112**: 579
upper respiratory tract, misdiagnosed as Wegener's granulomatosis **104**: 255
vs Kikuchi–Fujimoto's syndrome **113**: 82
Tuberous sclerosis
with primary meningioma of maxillary antrum **105**: 481
Tubotympanic CSOM
ear swabs **104**: 460
Tularemia
differential diagnosis **107**: 127

Turban tumour
parotid gland **113**: 779
Turbinates
cryosurgery **109**: 729
hypertrophy, total inferior turbinectomy vs concho-antropexy **107**: 1125
inferior
compensatory hypertrophy, septoplasty **107**: 413
multiple submucosal out-fractures **104**: 239
resection, need for nasal pack **107**: 906
laser surgery **109**: 296
nasal obstruction, in sickle cell anaemia **105**: 851
pyocele **108**: 783
resection, nasal packing **107**: 906
silver nitrate cautery **110**: 609
Turbinectomy
complications **109**: 559
and cryosurgery for hypertrophic inferior turbinates **110**: 732
inferior, four techniques **104**: 206
laser **113**: 529
sequestration following submucosal diathermy **105**: 14
Tympanic cavity
cochlear fistula **105**: 656
Tympanic membrane
anaesthesia, EMLA cream vs iontophoresis **104**: 195
atelectasis, otitis media with effusion **109**: 495
computer simulation **106**: 878
myringitis
bullosa haemorrhagica, tympanosclerosis **106**: 162
granulomatous **112**: 150
myringoplasty **111**: 517
anterior perforation, Kerr flap **106**: 14
children **104**: 758, **111**: 106
day-case clinics **110**: 421
ear canal dressing, pope wick **106**: 327
endoscopic surgery **106**: 493
fibrous annulus **106**: 116
iatrogenic epidermoid cyst **105**: 227
silicone prosthesis **106**: 205
temporalis fascia anatomy **105**: 522
myringotomy
middle ear ventilation tube, teaching materials **112**: 642
needle **112**: 865
increased prevalence of HIV **112**: 865
and ventilation tube insertion **111**: 257
ossification **107**: 550
pars flaccida, tissue culture, morphological study **104**: 91
pars tensa
retraction pockets **105**: 525
ventilation tubes, insertion **109**: 817
pathology, epidemiology **109**: 281
retraction pockets
excision **106**: 882
pars tensa **105**: 525
children, ventilation tube insertion **109**: 817
thermometry and minor ear surgery **110**: 454
Tympanic membrane perforation
closure after removal of Goode-type tympanostomy tubes, silastic sheeting **106**: 960
endoscopy **105**: 716
following grommet removal or extrusion, audit **107**: 593
mini-grommet **105**: 161
repair, hydrocolloidal dressing **109**: 1041
rupture by ear irrigation **109**: 1036
spontaneous rupture during anaesthesia **108**: 582
tissue culture, scanning electron microscopy **107**: 1106
traumatic, spontaneous healing **106**: 1037
Tympanic neurectomy
otalgia **104**: 114
Tympano–cartilago–stapediopexy
hearing improvement, open technique tympanoplasty **104**: 942
Tympanocentesis
ad hoc apparatus **106**: 425
Tympano–cochlear scintigraphy (TCS)
otosclerosis **109**: 1051
Tympanograms
abnormal, otitis media in Hampshire schoolchildren **108**: 930
Tympanometry
and home environment, seven-year-old children **104**: 4
point and period prevalence, otitis media with effusion **104**: 937
Tympanoplasty 109: 1048
autograft vs xenograft **107**: 892
bone grafts, fate **105**: 1018
children **113**: 628
prospective study **112**: 1147
cholesteatoma **112**: 31
combined approach, cholesteatomas of middle ear and mastoid **109**: 710
dietary sodium chloride requirement **109**: 324
instrumentation, surgery, retaining aural speculum **109**: 230
intact canal wall, cholesteatoma **110**: 1090
mucociliary clearance **107**: 895
ossiculoplasty **105**: 529
transposition of incus **106**: 607
Tympanosclerosis 111: 917
grommets, results at two years **107**: 108
hearing loss **113**: 1076
middle ear **104**: 685
mini grommets **109**: 922
myringitis bullosa haemorrhagica **106**: 162
otitis media with effusion, and ventilation tubes **105**: 161, **105**: 614
Tympanoscopy
diagnosis of conductive deafness **112**: 154
Tympanostomy
otitis media with effusion **113**: 207
Tympanostomy tube
otorrhoea, antibiotics **110**: 531
Tympanotomy
middle ear ventilation, long-term **109**: 1151
Typhus fever
and hearing loss, historical study **107**: 275

Ulcerative colitis
and giant cell arteritis, associated with sensorineural deafness **104**: 889
sensorineural hearing loss **111**: 277
Ultrasound
B-Mode, non-luminal carotid artery invasion by tumour **106**: 73
cystic neck lesions **107**: 245
and fine-needle aspiration cytology, parathyroid adenoma **107**: 543
laryngeal cancers **107**: 65
neoplasm metastases, treated by radiotherapy **113**: 993
oral dermoid cyst **104**: 141
peritonsillar abscess **108**: 610
prenatal diagnosis of upper airway obstruction **110**: 583
tonsillar infections **113**: 229
vs physical examination, staging carcinoma of tongue **110**: 43
Ultrasound-guided biopsy
salivary gland **113**: 988
Ultrasound-guided drainage
parotid abscess **112**: 1098
Uncinate process
pneumatization **107**: 361
Uncinectomy
endoscopic sinus surgery **112**: 547
Unterberger stepping test
indicator of peripheral vestibular dysfunction **104**: 599
Upper gastrointestinal tract
globus syndrome **107**: 535
Upper jugular haemorrhage 104: 976
Upper respiratory tract *see* Respiratory tract
Uvula
mycobacterial infection **112**: 1183
oedema, recurrent **107**: 640
surgery, obstructive sleep apnoea, complication of uvulopalato-pharyngoplasty **109**: 212
Uvulectomy
prevention of throat infections **108**: 65
Uvulopalato(pharyngo)plasty
complications **104**: 871, **109**: 212
laser surgery **110**: 232, **112**: 639
Leicester experience **108**: 649
sleep apnoea, post-operative evaluation **109**: 308
and treatment of snoring **104**: 428
without tonsillectomy, local anaesthesia **113**: 542

Vagus nerve
nasopharyngeal carcinoma **110**: 987
neurilemmoma **110**: 485
paraganglioma **110**: 688, **111**: 83
Vallecula
actinomycosis **109**: 154
angioleiomyoma, acute airway obstruction **104**: 341
cysts, neonates, and failure to thrive **106**: 448
Valsalva manoeuvre
causing cranial pneumatization **113**: 480
Eustachian tube barotitis **110**: 625
hypopharynx visualization **109**: 863
Varicella
facial nerve palsies **108**: 676
Varicella-zoster virus antigen
herpes zoster oticus **110**: 918
Vascular cross-compression
VIIth and VIIIth cranial nerves **106**: 436
Vascular malformations
internal auditory canal **107**: 1039
Vasculitis
ANCA-asociated, propylthiouracil **113**: 477
Vasoconstrictors
and saline, septal surgery infiltration **105**: 638
Vasomotor rhinitis *see* Rhinitis
Velopharyngeal function
nasendoscopy **111**: 739
Venous haemangioma
neck and mediastinum **105**: 386
Venous infarction of brain
and transverse sinus thrombosis **112**: 88
Venous sinus, lateral
papilloedema **110**: 878
Venous thromboembolism
prophylaxis in head and neck surgery **111**: 845
Venous thrombosis
massive, in laryngeal nerve palsy **107**: 54
Ventilation
high frequency jet ventilation **108**: 23
long term, tympanotomy **109**: 1151
middle ear, parental perception of outcome **113**: 1068
Ventilation scintigraphy Xe-133
Eustachian tube function **113**: 509
Ventilation tubes
and erythromycin, otitis media with effusion **104**: 200
Goode vs Armstrong, chronic otitis media with effusion **104**: 608
grommet insertion, children **112**: 732
grommet removal or extrusion, perforation following, audit **107**: 590, **107**: 593
grommets
swimming and otorrhoea **107**: 190
titanium **104**: 197
insertion **109**: 817
and myringotomy **111**: 257
using topical anaesthesia, children **106**: 427
intratympanic instillation of lignocaine (lidocaine), for tinnitus **106**: 603
mini grommets **109**: 922
otitis media, suppurative **105**: 896
Per-Lee tubes, children **104**: 112
prophylaxis for blockage, steroid ear drops/antibiotics **107**: 188, **110**: 531
Shah Permavent tube, long-term review **109**: 277
simultaneous laryngeal and oesophageal strictures, dilatation with two T-tubes **108**: 42
T-tubes **111**: 282
tympanosclerosis **105**: 161, **105**: 614
Ventilatory failure
postoperative presentation of myasthenia gravis **112**: 1194
Ventilatory monitoring
during microlaryngeal surgery, jet insufflation anaesthesia **106**: 42
Verbal auditory agnosia
with focal EEG abnormality, hearing loss **109**: 429
Verruciform xanthoma
nose **113**: 79
Verrucous squamous cell carcinoma
maxillary antrum **105**: 696, **112**: 399
nasal septum **112**: 172
Vertebral artery
penetrating injuries **106**: 925
trauma **113**: 76
Vertebral hyperostosis
Forestier's disease, cervical osteophytes **104**: 236
Vertebro–carotid artery anastomosis
uncontrollable epistaxis **108**: 247
Vertigo
Arnold–Chiari malformation **110**: 1060
benign paroxysmal positional **105**: 901, **107**: 1153
complication of cochlear implant **113**: 922
division of the auditory nerve **105**: 1099
endolymphatic sac drainage **105**: 1109
evaluation, multidisciplinary neurotology clinic **113**: 19
giant cell tumour of temporal bone **109**: 538
head and neck surgery **104**: 849
intractable benign paroxysmal positional, fenestration and occlusion of posterior semicircular canal **108**: 935
medical management **111**: 1114
Ménière's disease **113**: 666
aminoglycosides **113**: 916
endolymphatic sac surgery **110**: 1008
steroids **113**: 217
non-ampullary plugging of posterior semicircular canal **105**: 901
normal otoneurological examination, role of vestibular laboratory tests **110**: 1133
sarcoidosis **109**: 1089
significance of hearing loss as lateralising indicator **105**: 618
temporal bone, giant cell tumour **109**: 538
Vestibular aqueduct
large endolymphatic sac **110**: 1103
Vestibular aqueduct syndrome
and stapes fixation **108**: 989
Vestibular function
and cochlear implant **113**: 922
Vestibular function tests
measurement of body sway in normal subjects and patients with dizziness **109**: 189
schwannoma, caloric test vs galvanic body sway test **113**: 118
sensory interactions in platform posturography **107**: 496
sway weigh balance platform **109**: 836
Unterberger stepping test **104**: 599
Vestibular laboratory tests 110: 1133
Vestibular labyrinth *see* Labyrinth
Vestibular masses
auditory canal meningioma **113**: 1101
see also Schwannoma
Vestibular nerve
dysfunction and decompression in Engelmann's disease **110**: 462
regeneration, posterior cranial fossa neurectomy **113**: 967
schwannoma, unilateral tinnitus **113**: 818
Vestibular neurectomy
following previous mastoidectomy **110**: 836
histological and clinical study of results **110**: 211
infralabyrinthine approach **106**: 780
long-term results **112**: 1150
posterior fossa **105**: 1002
Vestibular neuronitis
symptoms caused by intramedullary lesion **109**: 545
Vestibular schwannoma
surgery, cerebrospinal fluid rhinorrhoea **107**: 1122
Vestibular tumours
inner ear tumours **111**: 709
Vestibulo–cochlear dysfunction
acute, following occipital fracture **108**: 54
***Vibrio* infections 109**: 1082
otitis media **109**: 1082
Video recording endoscopy
computer-assisted image processing, nasal mucosa **110**: 1017
Videostroboscopic evaluation
laryngeal tuberculosis **112**: 45
Villonodular synovitis
temporomandibular joint **107**: 853, **108**: 166, **112**: 182
Vinca alkaloids
and vocal fold palsy **112**: 485
Viscoaugmentation
for leakage around Provox 2 voice rehabilitation system **113**: 847

Visual evoked potentials
endoscopic paranasal sinus surgery **110**: 31, **110**: 261
skull base surgery **111**: 513
Visual loss
acute bilateral in childhood, rhabdomyosarcoma and malignant lymphoma **108**: 873
benign spheno–ethmoidal lesions **104**: 217
complication of bilateral neck dissection **104**: 154
electrocoagulation following functional endoscopic sinus surgery (FESS) **110**: 261
sinusitis associated **107**: 840
Visual pathways
endoscopic sinus surgery **112**: 622
Vocal efficiency (PAVE) 111: 129
Vocal fold paralysis
adenoid cystic carcinoma invading recurrent laryngeal nerve **113**: 260
arytenoid cartilage surgery **110**: 1027
benign thyroid disease **108**: 433, **113**: 473
bilateral abductor
arytenoidectomy and posterior cordectomy **105**: 454
endoscopic laterofixation **106**: 31
myasthenia gravis **113**: 678
secondary to hypokalaemia **106**: 56
bilateral immobile **111**: 474
endoscopic teflon injection **109**: 1184
following carotid endarterectomy **113**: 439
following vinca alkaloid treatment **112**: 485
and hydralazine-induced lupus **112**: 875
infants, tracheostomy or not **108**: 329
investigations **108**: 193
laryngeal mask airway **110**: 383
laryngeal pseudotumour **109**: 142
laser cordectomy **113**: 637
MRI **110**: 884
in multiple system atrophy **112**: 177
organophosphorus poisoning **112**: 81
precricoid swelling, Teflon injection in vocal fold **112**: 878
radiation-induced **105**: 44
relapsing polychondritis **105**: 961
result of central venous catheterization **109**: 1107
Shy–Drager syndrome, snoring and sleep apnoea **110**: 681
stroboscopy **110**: 141
surgery **110**: 111
Vocal fold tumours
carcinoma, T-1 **104**: 222
function following laser and conventional surgery **110**: 1138
T-1 carcinoma **104**: 222
Vocal folds
caffeine effects **113**: 341
lateralisation using carbon dioxide laser and fibrin glue **106**: 226
paradoxical motion **109**: 1105
stridor **105**: 312
pre-operative checks **113**: 642
stridor, myasthenia gravis **113**: 1114
sulcus **104**: 876
suspension microlaryngoscopic and indirect microlaryngostroboscopic surgery, benign lesions **108**: 1064
systemic lupus erythematosus **110**: 478
Teflon injection **105**: 128
Vocal process granulomata 108: 216
Voice
at puberty, vocal fold length and its relationship to fundamental frequency **112**: 451
Voice disorders
botulinum toxins **110**: 551
chronic posterior laryngitis, pantoprazole **113**: 734
cricohyoepiglottopexy, long-term results **113**: 532
and gastroesophageal reflux **109**: 1195
Isshiki type III thyroplasty, acoustic evaluation **113**: 31
laser surgery, vs conventional phonosurgery **113**: 140
mutations, Isshiki type III thyroplasty **113**: 31
paediatrics **110**: 1022
rehabilitation system **113**: 847
tracheoesophageal following transmucosal pharyngeal myotomy **111**: 659
traumatic causes **111**: 903
see also Speech
Voice rehabilitation
after laryngectomy **111**: 4
Bivona voice prosthesis, aphonia **108**: 579
indwelling tracheo-oesophageal voice prostheses **110**: 343
leaking prosthesis, "holiday plug" **107**: 1149
manomometry as screening procedure **106**: 353
partial laryngectomy **109**: 410
pharyngeal myotomy, complications **107**: 430
post laryngectomy, Provox valve **109**: 1068
prosthesis washer, tracheo-oesophageal speakers with a large tracheostome **107**: 824
tracheo-oesophageal puncture **105**: 748, **105**: 750, **105**: 1082
tracheoesophageal vs oesophageal speech **108**: 325
Vomiting
pregnancy, resulting in oesophageal perforation **107**: 1059
Von Hippel–Lindau disease
invasive choroid plexus tumour, presenting as middle ear mass **106**: 429
Von Recklinghausen's disease
parapharyngeal space, schwannoma **107**: 848
Von Willebrand's disease
bleeding after tonsillectomy **109**: 437
tonsillectomy **110**: 947
and Wilms' tumour, epistaxis **108**: 1081

Waardenburg's syndrome
anodontia **113**: 672
hearing loss, genetic counselling **104**: 97
hearing loss and pigmentary disturbances **109**: 96
Waldenstrom's macroglobulinaemia
malignant external otitis, Bing–Neel syndrome **108**: 492
Waldeyer's tonsillar ring
adult T-cell leukaemia–lymphoma **107**: 960
blastic variant of mantle cell lymphoma **112**: 991
Warfarin
and epistaxis, case controlled study **107**: 195
syndrome, airway problem **106**: 1098
Warthin's tumour
mucocele mimicking recurrence **112**: 1092
Water fluoridation
otosclerosis **111**: 20
Watson-Williams, Patrick
on focal sepsis of sinuses **105**: 1
Wegener's granulomatosis 111: 746, **111**: 825, **112**: 307, **112**: 664
cochlear implant **110**: 958
facial nerve paralysis **110**: 459
family study **105**: 123
Japan, AIDS-like disproportion of minor T-cell subsets **106**: 133
major salivary gland enlargement **110**: 691
misdiagnosis **104**: 255
negative ANCA **108**: 420
otological manifestations **108**: 144
recurrence of intranasal adhesions **104**: 426
salivary glands **104**: 259
serological activity index, CO–N reaction **107**: 607
temporal headache **110**: 802
unilateral parotid swelling **108**: 431
Welch Allyn Audioscope and Microtymp
accuracy, and that of pneumatic otoscopy, tympanometry and pure tone audiometry, as predictors of otitis media with effusion **106**: 600
Westaby T-Y tracheobronchial stent 113: 652
Weyer's acrofacial dysostosis
double epiglottis **112**: 976
White noise generators for tinnitus
canal resonance and hearing loss **111**: 810
WHO
role in prevention of hearing loss **111**: 699
Wilms' tumour
and von Willebrand's disease, epistaxis **108**: 1081
Wound healing
image processing, computer-assisted endoscopy of nasal and oesophageal mucosa **110**: 1017
Wounds
acute laryngeal trauma
Bosnia **109**: 144
peacetime and war injuries **110**: 435
MRSA infection, head and neck surgery **111**: 874

Wounds (continued)
pharyngeal perforation secondary to 'pencil injury' **110**: 901
soft tissue sarcomas of head and neck associated with surgical trauma **109**: 126
vertebral artery trauma **113**: 76
wound healing, image processing **110**: 1017
see also Foreign bodies

X-ray CT *see* CT scanning
Xanthogranuloma
temporal bone **111**: 63
Xanthogranuloma auris
juvenile **109**: 975
Xanthoma
nasal **113**: 79
Xenograft
vs autograft, in tympanoplasty **107**: 892
Xenon radioisotopes
Eustachian tube function **113**: 509
Xeroform packs
mastoidectomy **105**: 916
Xerostomia
radiation injury, artificial saliva vs pilocarpine **108**: 663
Xomed one piece septal button
nasal septum **106**: 358
Xylocaine test
prognostic aid in Sluder's neuralgia **109**: 193

Yearsley, James 105: 249
Yellow nail syndrome
and chronic sinusitis **104**: 811
Young's procedure
epistaxis **105**: 847

Zenker's diverticulum 104: 312
endoscopic stapling **113**: 237

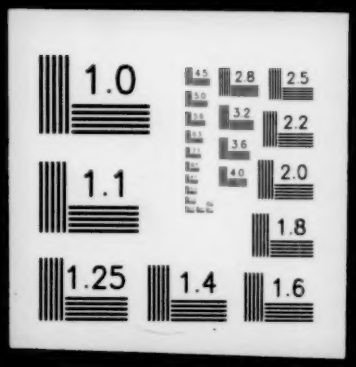
1.0
2.8
2.5
3.2
2.2
3.6
4.0
2.0
1.1
1.8
1.25
1.4
1.6